

INCREASED PREVALENCE OF DYSPLASTIC AND MALIGNANT LIP LESIONS IN RENAL-TRANSPLANT RECIPIENTS

GASTON N. KING, B.D.S., M.D.Sc., CLAIRE M. HEALY, B.DENT.Sc., MARY T. GLOVER, M.B., B.S.,
 JONATHAN T.C. KWAN, M.B., B.S., M.D., DAVID M. WILLIAMS, B.D.S., PH.D.,
 IRENE M. LEIGH, M.B., B.S., M.D., HELEN V. WORTHINGTON, PH.D.,
 AND MARTIN H. THORNHILL, M.B., B.S., PH.D.

Abstract Background. Renal-transplant recipients are known to have increased rates of skin cancer associated with exposure to the sun. Little is known, however, about the prevalence and histologic features of lesions of the lips in these patients, or about risk factors for such lesions.

Methods. We examined the lips of 160 renal-transplant recipients (105 men and 55 women; mean [\pm SD] age, 48 ± 13 years) and 160 normal subjects matched with the transplant recipients for age, sex, and skin type. The mean length of time between transplantation and the examination was 69 ± 52 months; 58 percent of the recipients had received their grafts more than 60 months earlier.

Results. Among the 160 renal-transplant recipients, 21 (13 percent) had leukoplakia; in 2 (1.2 percent) the leukoplakia contained squamous-cell carcinoma. In con-

trast, only one normal subject (0.6 percent) had leukoplakia. Histologically, 13 of the 21 leukoplakias (62 percent) in the renal-transplant recipients who underwent biopsy were dysplastic, and 2 (10 percent) contained squamous-cell carcinoma. Actinic change was evident in 91 percent of the dysplastic lesions but not in the nondysplastic lesions ($P<0.001$). Exposure to the sun and smoking were risk factors for dysplastic and malignant lip lesions in the renal-transplant recipients ($P<0.001$ and $P=0.003$, respectively). Among these recipients, only men had dysplastic or malignant lip lesions ($P=0.006$); lipstick was used frequently by 73 percent of the women. The clinical appearance of lip lesions did not predict the presence of dysplasia or cancer.

Conclusions. Renal-transplant recipients have an increased prevalence of leukoplakia, dysplasia, and cancer of the lip. (N Engl J Med 1995;332:1052-7.)

RENAL-TRANSPLANT recipients who receive immunosuppressive therapy have an increased risk of premalignant skin keratoses and skin cancer,^{1,2} and aggressive cancer occurs 20 to 30 years earlier, on average, in transplant recipients than in subjects who do not undergo immunosuppression.³⁻⁶ Exposure to ultraviolet radiation and the duration of immunosuppression are important risk factors for cutaneous lesions; the incidence of cancer on sun-exposed surfaces is 20 times higher than in immunocompetent subjects, whereas the incidence of cancer is increased by only 4 to 7 times at sites with low levels of exposure to sunlight.^{4,5,7,8} Although the lip is exposed to a great deal of sunlight, little is known about the prevalence of lip lesions among renal-transplant recipients and the associated risk factors. We conducted this study to determine the prevalence of leukoplakia, dysplasia, and cancer of the lip in renal-transplant recipients and to identify possible risk factors and any distinctive features of the lesions.

METHODS

The study was conducted with the approval of the ethics committee of Tower Hamlets Health Authority and with the informed consent of the study subjects. We examined the lips of 160 consecutive renal-transplant recipients (105 men and 55 women; mean [\pm SD] age, 48 ± 13 years) who were seen in an oral-screening clinic after a routine follow-up appointment in the renal clinic. The mean length of time since transplantation was 69 ± 52 months.

Eight patients (5 percent) were receiving only cyclosporine. Of the remainder, those who underwent transplantation before 1985 (17 per-

cent) were receiving prednisolone and azathioprine, and those who received transplants during or after 1985 (78 percent) were receiving prednisolone, azathioprine, and cyclosporine. The recipients were categorized according to lifetime sun exposure. Those who had lived in a tropical or subtropical region for more than three months or had worked in an outdoor occupation in the United Kingdom for five or more years were assigned to the highest sun-exposure group. Those who sunbathed more than 14 days per year or participated in outdoor activities more than 10 hours per week were assigned to the moderate-sun-exposure group. All others were assigned to the low-sun-exposure group. There was no difference in sun exposure between the male and female renal-transplant recipients. The women were asked how frequently they used lipstick when out of doors. All the subjects were assigned to one of five skin-type categories on the basis of their race or ethnic group, tanning ability, and tendency to burn, according to the classification of Fitzpatrick.⁹ The transplant recipients were also asked about their past and present smoking habits and their current alcohol consumption.

We also studied 160 consecutively recruited normal subjects who came to the Dental Institute at the Royal London Hospital for general dental treatment. These subjects (105 men and 55 women; mean [\pm SD] age, 50 ± 15 years) were matched for age, sex, and skin type with the renal-transplant recipients.

The lips of all subjects were examined once by two clinicians who had previously reviewed the subjects' medical histories. The diagnosis of leukoplakia was made by the two clinicians conjointly according to the World Health Organization definition of leukoplakia as a keratotic white plaque that could not be removed and could not be characterized clinically or pathologically as indicative of any other disease.¹⁰ All lesions were photographed.

Pathological Studies

All clinically evident lesions were sampled at biopsy and examined histopathologically. Changes in the epithelium and connective tissue were assessed, and a diagnosis was made by a pathologist who had no knowledge of the subject's clinical history. Hyperkeratosis was considered to be present if the thickness of keratin was greater than is normally found on the vermilion surface of the lip. Epithelial dysplasia was defined by the presence of epithelial atypia without invasion of connective tissue, a bulbous rete-peg pattern, basal-cell crowding, abnormal mitotic activity, an increased ratio of nucleus to cytoplasm, and nuclear hyperchromatism. Squamous-cell carcinoma was diagnosed if multiple bud-like projections and discrete islands

From the Departments of Oral Medicine and Periodontology (G.N.K., C.M.H., M.H.T.), Dermatology (M.T.G., I.M.L.), and Nephrology (J.T.C.K.), and the Joint Department of Oral Pathology with the Institute of Dental Surgery (D.M.W.), London Hospital Medical College, London, and the Department of Oral Health, University of Manchester, Manchester, United Kingdom (H.V.W.). Address reprint requests to Dr. King at the Department of Oral Medicine and Periodontology, London Hospital Medical College, London E1 2AD, United Kingdom.

and nests of cells had invaded the underlying connective tissue. Actinic change was diagnosed when there was mild or marked loss of collagen fibers with an amorphous appearance and hyalinization in the underlying connective tissue. The inflammatory response in the connective tissue was also assessed.

Statistical Analysis

The photographs of the lip lesions were assessed separately by three experienced oral physicians who were unaware of the subject's clinical history, to determine the degree of agreement among observers and the degree of agreement between their diagnoses and the histologic diagnoses. The sensitivity and specificity of the clinical diagnoses as predictors of the histologic features of lesions were also determined. Differences between the groups were compared by the Mann-Whitney U test, in the case of continuous variables, and the chi-square test or Fisher's exact test for categorical variables. The analysis was repeated, comparing the transplant recipients who had dysplastic or malignant lesions with all other transplant recipients. In logistic-regression analyses, the presence or absence of dysplastic or malignant lesions was used as the dependent variable in order to examine the relation between dependent and explanatory variables. All statistical tests were two-tailed.

RESULTS

Four percent of the renal-transplant recipients had received their grafts less than 12 months before the examination, 58 percent had received grafts more than 60 months previously, and 14 percent had received grafts more than 120 months previously. Twenty-three (14 percent) of the renal-transplant recipients (18 men and 5 women) had lip lesions; in the control group, only 1 subject (0.6 percent), a woman, had a lip lesion, diagnosed as leukoplakia. All the lesions affected the vermilion portion of the lower lip, except for a single car-

cinoma of the vermilion portion of the upper lip in a 62-year-old renal-transplant recipient, a man, with a history of smoking. The lip lesions were diagnosed clinically as leukoplakia in 21 of the transplant recipients and as papillomas in 2. Biopsies were performed on 21 of the lesions; the histopathological diagnosis was a fibroepithelial polyp in 1 patient, a papilloma in 1 patient (who also had epithelial dysplasia), benign hyperkeratosis in 7 patients, epithelial dysplasia in 11 patients (including 1 associated with a squamous-cell papilloma), and squamous-cell carcinoma in 2 patients (both men, 37 and 62 years old). Overall, 8 lip lesions were categorized as nondysplastic and 13 as dysplastic or malignant. No biopsy was done of two lip lesions, including a leukoplakia in a man whose renal transplant had been rejected and who was no longer receiving immunosuppressive therapy; this lesion disappeared one month after the initiation of dialysis. One woman, a transplant recipient with a clinically diagnosed papilloma of the lower lip, was lost to follow-up. The single leukoplakia in the normal subject had been present for many years without change. The characteristics of the two study groups and the distribution of risk factors among the renal-transplant recipients, subgroups of the recipients, and normal subjects are summarized in Tables 1 and 2.

Clinically, the lip lesions in the transplant recipients were often subtle. Some had only a dry, atrophic appearance or an indistinct vermilion border that merged with the adjacent keratinized skin (Fig. 1). The poor agreement between the clinical diagnoses of the 21 lip

Table 1. Characteristics of the Renal-Transplant Recipients with and without Dysplastic or Malignant Lip Lesions and of the Normal Subjects.*

CHARACTERISTIC	CONTROLS (N = 160)	RENAL-TRANSPLANT RECIPIENTS				
		ALL (N = 160)	WITH DYSPLASTIC OR MALIGNANT LESIONS (N = 13)	P VALUE: RECIPIENTS WITH DYSPLASTIC OR MALIGNANT LESIONS VS. ALL OTHER RECIPIENTS	P VALUE: RECIPIENTS WITH NON-DYSPLASTIC LESIONS VS. RECIPIENTS WITH DYSPLASTIC OR MALIGNANT LESIONS	
Age — yr	50 ± 15	48 ± 13	54 ± 12	0.12	60 ± 6	0.31
Sex — no. (%)						
Male	105	105	13 (12)†	0.006	4 (4)†	0.01
Female	55	55	0		4 (7)‡	
Time since receipt of transplant — mo	—	69 ± 52	69 ± 52	0.67	76 ± 59	0.77
Dose of immunosuppressive agents — mg/kg/day						
Cyclosporine	—	3.14 ± 2.31	2.96 ± 1.50	0.53	1.84 ± 2.1	0.16
Prednisolone	—	0.13 ± 0.05	0.12 ± 0.03	0.13	0.14 ± 0.02	0.04
Azathioprine	—	1.69 ± 0.51	1.57 ± 0.61	0.84	1.75 ± 0.89	0.73
History of smoking — no. (%)	94 (59)	72 (45)	11 (15)§	0.003	2 (3)§	0.02
Active smokers — no. (%)	53 (33)	23 (14)	4 (17)¶	0.08	2 (9)¶	1.00
Cigarettes smoked — packs/wk	5.8 ± 3.8	4.6 ± 3.1	4.5 ± 2.6	0.83	6.8 ± 4.6	0.42
Years of smoking	21 ± 11	21 ± 14	25 ± 14	0.22	52 ± 18	0.06
Alcohol consumption — units/wk	5.9 ± 10.3	3.3 ± 5.6	7.2 ± 8.3	0.08	1.6 ± 2.3	0.24

*Plus-minus values are means ± SD. Only the 21 transplant recipients who underwent biopsy are included in the renal-transplant subgroups. Tests of significance were performed with the Mann-Whitney U test and the Pearson chi-square test or Fisher's exact test.

†Percentage of male transplant recipients.

‡Percentage of female transplant recipients.

§Percentage of transplant recipients with a history of smoking.

¶Percentage of active smokers.

||One unit of alcohol was defined as approximately 10 g of alcohol or one half-pint of beer, one small glass of wine, or one measure of spirits.

Table 2. Age, Skin Type, and Sun Exposure of the Renal-Transplant Recipients with Dysplastic or Malignant Lip Lesions, the Renal-Transplant Recipients without Such Lesions, and the Normal Subjects.*

VARIABLE	CONTROLS (N = 160)		RENAL-TRANSPLANT RECIPIENTS		P VALUE: RECIPIENTS WITH DYSPLASTIC OR MALIGNANT LESIONS VS. ALL OTHER RECIPIENTS	P VALUE: RECIPIENTS WITH NON- DYSPLASTIC LESIONS VS. RECIPIENTS WITH DYSPLASTIC OR MA- LIGNANT LESIONS
	no.	no.	ALL (N = 160)	WITH DYSPLASTIC OR MALIGNANT LESIONS (N = 13)		
				no. (%)†		
Age (yr)					0.14	0.08
18–29	20	20	0		0	
30–39	21	21	2 (10)		0	
40–49	39	40	2 (5)		0	
50–59	46	47	4 (9)		5 (11)	
≥60	34	32	5 (16)		3 (9)	
Skin type					0.67	0.86
Always burns, never tans	19	16	0		1 (6)	
Burns easily, tans slowly	64	67	6 (9)		3 (4)	
Always tans, never burns	49	53	5 (9)		3 (6)	
Mediterranean, Chinese	10	8	1 (12)		0	
Asian Indian, black	18	16	1 (6)		1 (6)	
Sun exposure					<0.001	0.38
Low	54	93	2 (2)		2 (2)	
Moderate (sunbathing >14 days/yr or outdoor activity >10 hr/wk)	46	21	2 (10)		2 (10)	
High (outdoor job ≥5 yr or lived in tropics >3 mo)	60	46	9 (20)		4 (9)	

*Tests of significance were performed with the Pearson chi-square test or Fisher's exact test. Only the 21 transplant recipients who underwent biopsy are included in the renal-transplant subgroups.

†Percentages are of all transplant recipients in the relevant category.

lesions made by each of the three clinicians (values for kappa ranged from 0.22 to 0.50), and the poor agreement between their clinical diagnoses and the histopathological findings (Fig. 2) (kappa, -0.06 to 0.24), reflect the difficulty of accurately diagnosing dysplastic and malignant lip lesions on the basis of the clinical examination alone (Fig. 1, 3, and 4). The sensitivity and specificity of the clinical diagnosis in predicting the his-

tologic features of the lesions were remarkably low; the diagnoses of two clinicians had a combined sensitivity and specificity of less than 100 percent, and the third clinician's diagnosis had a sensitivity of 42 percent and a specificity of 88 percent.

The differences in sun exposure between the men and women in the renal-transplant group were not significant, but the 13 transplant recipients (all men) who had dysplastic or malignant lesions had significantly more sun exposure than the 147 recipients with normal lips or nondysplastic lesions ($P < 0.001$). The majority (69 percent) of the men with dysplastic or malignant lesions, including both patients with squamous-cell carcinoma, were in the highest sun-exposure category. More of the transplant recipients with dysplastic or malignant lesions than of the other recipients were smokers ($P = 0.003$). Both exposure to the sun and a history of smoking were significant independent variables in a logistic-regression analysis ($P = 0.002$ and $P = 0.009$, respectively); no other variables approached statistical significance. Of the female recipients, 73 percent used lipstick when out of doors; all had done so for 5 years or more and 92 percent for more than 10 years. Although the three white women who had leukoplakia used lipstick, none had dysplastic or malignant lesions.

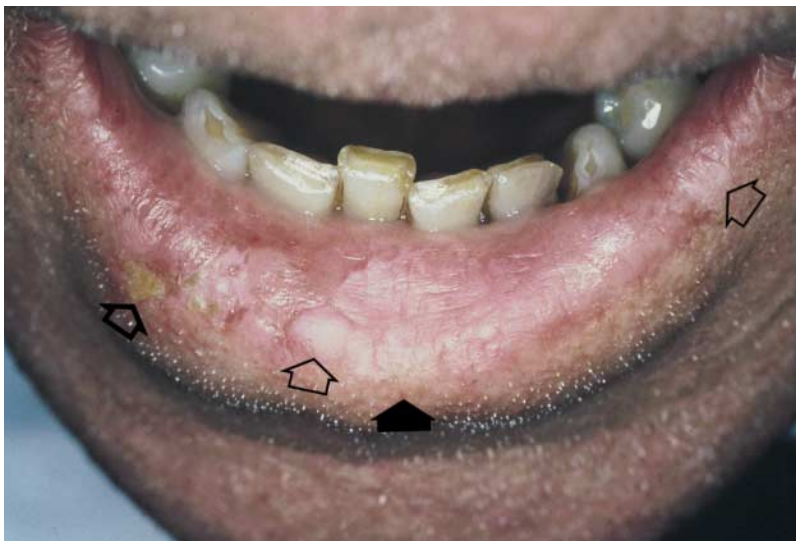

Figure 1. Clinical Features of a Lip Lesion in a Renal-Transplant Recipient.

This photograph shows areas of localized flaking and crusting on the left (large open arrow), an indistinct vermilion border where the lip margin merges with the adjacent keratinized skin (solid arrow), and thickened, flat white patches (small open arrows). In this patient, as in some others, several foci of change were present, making it difficult to determine which area should be sampled at biopsy.

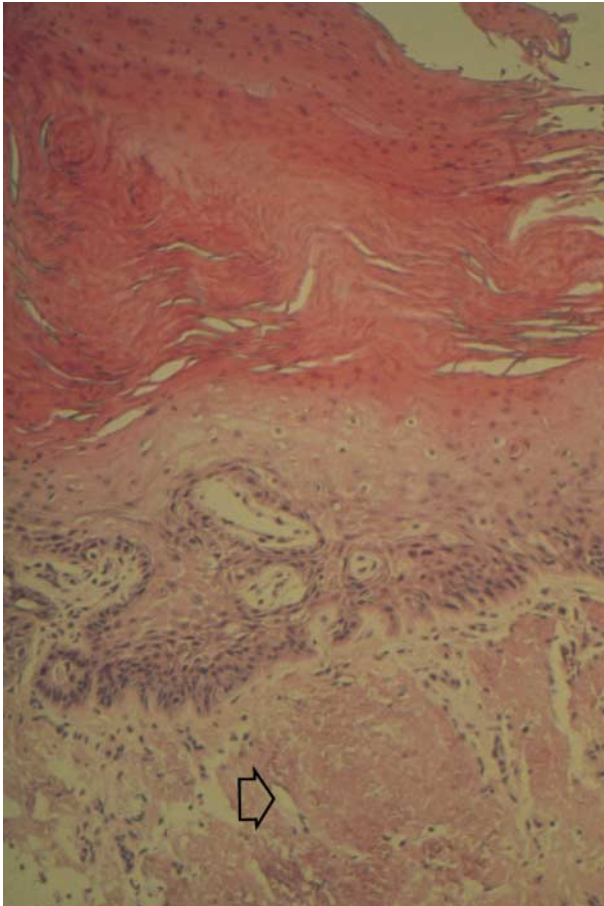


Figure 2. A Dysplastic Lip Lesion with Typical Histologic Features in a Renal-Transplant Recipient.

This section shows pronounced hyperkeratosis on the surface, epithelial dysplasia, and actinic change and hyalinization of underlying fibrous tissue (arrow); a host inflammatory response is absent (hematoxylin and eosin, $\times 85$).

There were no significant differences between the transplant recipients with dysplasia or cancer and those with normal lips or nondysplastic lesions with respect to age at time of transplantation, length of time since transplantation, type of immunosuppressive therapy, skin type, or alcohol consumption. No relation was found between lip dysplasia or cancer and the presence or number of atypical, dysplastic, or malignant skin lesions on the face.

There was significantly more sun exposure ($P < 0.001$) and a higher frequency of smoking in the control group than in the renal-transplant group. The normal subjects smoked significantly more cigarettes per week than the transplant recipients, although both groups had smoked for the same mean number of years. Alcohol consumption was also significantly higher among the normal subjects than among the transplant recipients.

Histologically, 71 percent of the biopsy specimens from the transplant recipients showed pronounced hyperkeratosis; epithelial dysplasia was present in 52 percent, and 10 percent had evidence of squamous-cell carcinoma (Fig. 2 and 4). Actinic change was evident

in 91 percent of the dysplastic lesions but was absent in the nondysplastic lesions in the recipients ($P < 0.001$). A host inflammatory response was either absent or minimal in all nondysplastic lesions and 64 percent of the dysplastic lesions. There was no significant difference between the transplant recipients with dysplastic lesions and those with nondysplastic lesions with respect to the length of time since transplantation or the type of immunosuppressive therapy. In the two recipients with squamous-cell carcinoma, there was an unusual combination of keratin-pearl formation with aggressive infiltration and an absence of inflammatory response in the connective tissue.

DISCUSSION

The prevalence of dysplastic lesions of the vermilion border of the lip in this group of renal-transplant recipients was 8 percent, and that of malignant lip lesions 1.2 percent; the control subjects had no such lesions. These prevalence rates were 90 and 15 times higher, respectively, than those reported in a recent, large general-population study of white North Americans.¹¹ The prevalence of lip leukoplakia in the transplant recipients (13 percent) was 22 times higher than that in the normal subjects (0.6 percent) and 16 times higher than in the North American study (0.8 percent).¹¹

The renal-transplant recipients and the controls were matched for age, sex, and skin type, but the renal-transplant group had a generally lower frequency of possible risk factors such as smoking, alcohol consumption, and exposure to the sun. Immunosuppression ap-

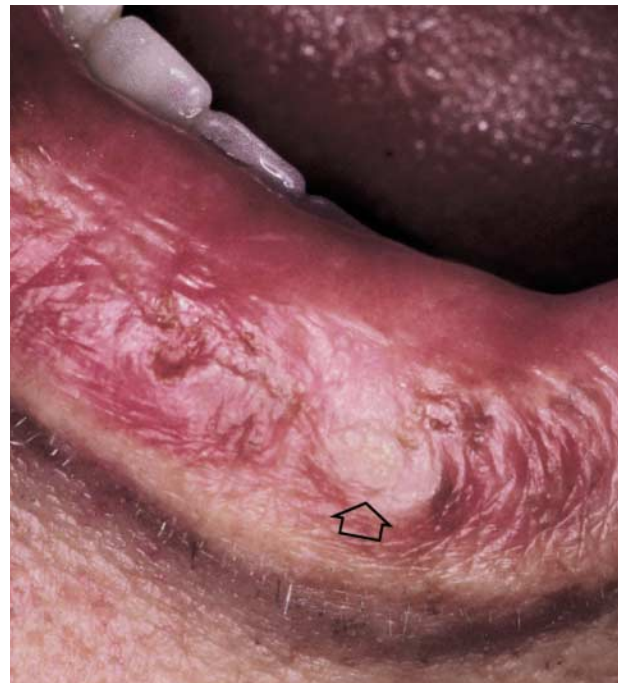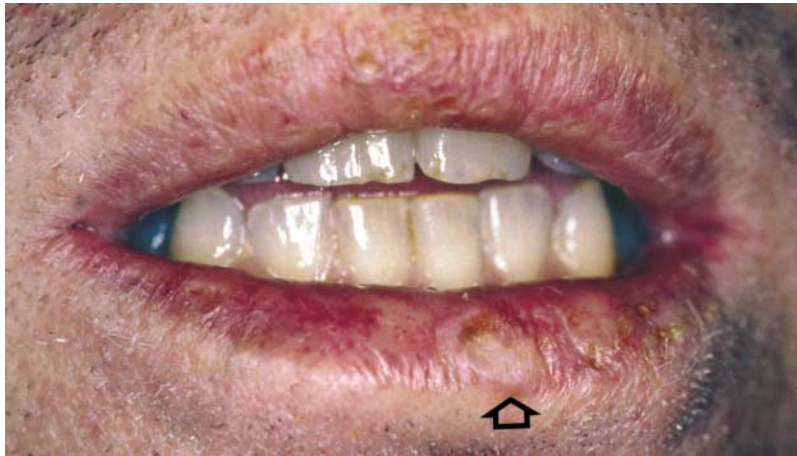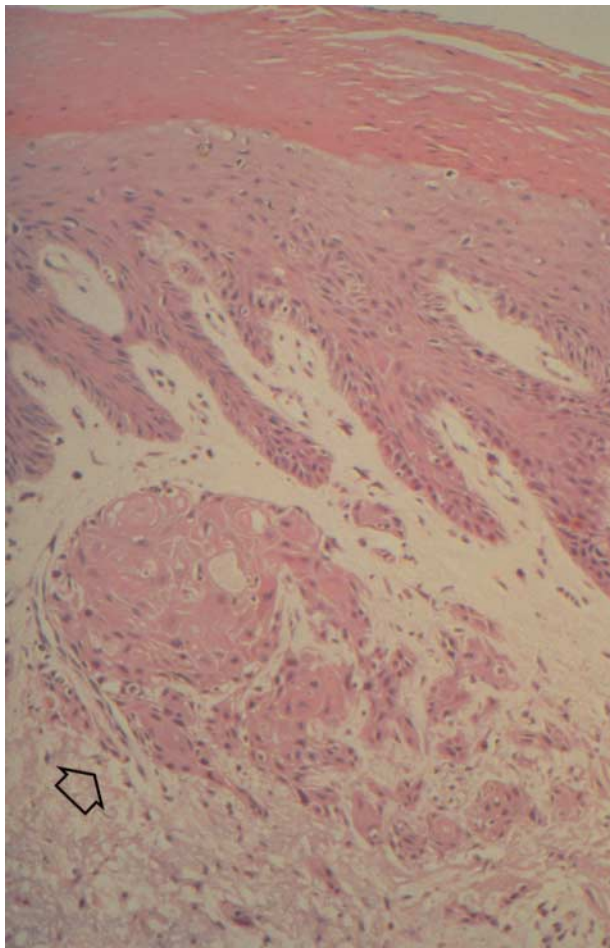


Figure 3. Lower Lip of a 62-Year-Old Male Renal-Transplant Recipient.

This photograph shows a thickened white patch (arrow). Although sinister in appearance, this lesion was classified as benign hyperkeratosis on biopsy.



A



B

Figure 4. Photograph of the Lower Lip of a 37-Year-Old Male Renal-Transplant Recipient (Panel A) and Photomicrograph of a Biopsy Specimen from the Lip Lesion (Panel B).

The photograph in Panel A shows a thickened white patch (arrow). On biopsy, this was diagnosed as a carcinoma. Panel B shows the histologic appearance of the lesion. This section shows marked hyperkeratosis at the surface. At a deeper level, there is infiltration of the underlying fibrous tissue by squamous-cell carcinoma (arrow), with a negligible inflammatory response (hematoxylin and eosin, $\times 85$).

pears to have been the single most important cause of the higher prevalence of lip lesions in the transplant recipients, although not all were at equal risk for dysplastic or malignant lesions. Additional factors such as sun exposure may also be important, since lip cancer is often preceded by actinic keratosis and dysplasia.^{12,13} Indeed, exposure to the sun appears to have been an important factor in the development of dysplasia in the transplant recipients; 91 percent of the biopsy specimens with evidence of dysplasia also had actinic changes in the underlying corium, whereas there was no evidence of such changes in the

biopsy specimens from recipients who did not have dysplasia ($P < 0.001$). Moreover, the transplant recipients with dysplastic or malignant lip lesions had had significantly more exposure to the sun than those with normal or nondysplastic lesions ($P < 0.001$); nearly 69 percent of those with dysplasia or lip cancer were in the highest sun-exposure group. Exposure to the sun and smoking were significant independent risk factors for the development of dysplastic or malignant lip lesions ($P < 0.01$).

The transplant recipients with dysplasia or cancer of the lip did not have an increased incidence of cutaneous actinic keratoses and skin carcinomas of the face, a finding that suggests that independent processes may be involved in the development of skin and lip cancer. There was little histologic evidence of viral infection in the biopsy specimens we examined, but there is accumulating evidence that implicates human papillomaviruses in the pathogenesis of skin cancer in renal-transplant recipients.¹⁴⁻¹⁷

Although lip cancer in transplant recipients may be superficial, multiple, or atypical in appearance,¹⁸ a disturbing feature in this study was the innocent clinical appearance of these lesions. A high proportion (62 percent) of leukoplakias were dysplastic, and 10 percent had undergone malignant change. Furthermore, dysplastic changes were seen at some distance from the clinically obvious lesions.

Although the men and women in this study were otherwise well matched for important variables associated with the development of skin cancer, all the dysplastic lesions and squamous-cell carcinomas occurred in men. Since keratinocytic epidermal cancers are not related to hormonal activity,¹⁹ the use of a physical block against sun exposure — such as lipstick — is probably a factor that reduces the risk of lip cancer in women.

We are indebted to Mr. A. Cruchley for advice and encouragement.

REFERENCES

- Boyle J, MacKie RM, Briggs JD, Junor BJR, Aitchison TC. Cancer, warts, and sunshine in renal transplant patients: a case control study. *Lancet* 1984; 1:702-5.
- Blohme I, Brynner H. Malignant disease in renal transplant patients. *Transplantation* 1985;39:23-5.

3. Blohme I, Larko O. Premalignant and malignant skin lesions in renal transplant patients. *Transplantation* 1984;37:165-7.
4. Hardie IR, Strong RW, Hartley LCJ, Woodruff PWH, Clunie GJA. Skin cancer in Caucasian renal allograft recipients living in a subtropical climate. *Surgery* 1980;87:177-83.
5. Hoxtell EO, Mandel JS, Murray SS, Schuman LM, Goltz RW. Incidence of skin carcinoma after renal transplantation. *Arch Dermatol* 1977;113:436-8.
6. Marshall V. Premalignant and malignant skin tumours in immunosuppressed patients. *Transplantation* 1974;17:272-5.
7. Kinlen LJ, Sheil AGR, Peto J, Doll R. Collaborative United Kingdom-Australasian study of cancer in patients treated with immunosuppressive drugs. *BMJ* 1979;2:1461-6.
8. Penn I. Tumors after renal and cardiac transplantation. *Hematol Oncol Clin North Am* 1993;7:431-45.
9. Pathak MA, Fitzpatrick TB, Greiter F, Kraus EW. Preventive treatment of sunburn, dermatoheliosis, and skin cancer with sun-protective agents. In: Fitzpatrick TB, Eisen AZ, Wolff K, Freedberg IM, Austen KF, eds. *Dermatology in general medicine: textbook and atlas*. 3rd ed. Vol. 1. New York: McGraw-Hill, 1987:1507-22.
10. Kramer IR, Lucas RB, Pindborg JJ, Sobin LH. Definition of leukoplakia and related lesions: an aid to studies on oral precancer. *Oral Surg Oral Med Oral Pathol* 1978;46:518-39.
11. Bouquot JE, Gundlach KK. Odd lips: the prevalence of common lip lesions in 23,616 white Americans over 35 years of age. *Quintessence Int* 1987;18:277-84.
12. Douglass CW, Gammon MD. Reassessing the epidemiology of lip cancer. *Oral Surg Oral Med Oral Pathol* 1984;57:631-42.
13. Lindqvist C, Teppo L, Pukkala E. Occupations with low risk of lip cancer show high risk of skin cancer of the head. *Community Dent Oral Epidemiol* 1981;9:247-50.
14. Lutzner M, Croissant O, Ducasse MF, Kreis H, Crosnier J, Orth G. A potentially oncogenic human papillomavirus (HPV-5) found in two renal allograft recipients. *J Invest Dermatol* 1980;75:353-6.
15. Bunney MH, Barr BB, McLaren K, et al. Human papillomavirus type 5 and skin cancer in renal allograft recipients. *Lancet* 1987;2:151-2.
16. Barr BB, Benton EC, McLaren K, et al. Human papilloma virus infection and skin cancer in renal allograft recipients. *Lancet* 1989;1:124-9.
17. Blessing K, McLaren KM, Benton EC, et al. Histopathology of skin lesions in renal allograft recipients — an assessment of viral features and dysplasia. *Histopathology* 1989;14:129-39.
18. Penn I. Immunosuppression and skin cancer. *Clin Plast Surg* 1980;7:361-8.
19. Rogers GS, Flowers JL, Pollack SV, McCarty KS Jr. Determination of sex steroid receptor in human basal cell carcinoma. *J Am Acad Dermatol* 1988;18:1039-43.

IMAGES IN CLINICAL MEDICINE

Images in Clinical Medicine, a weekly *Journal* feature, presents clinically important visual images, emphasizing those a doctor might encounter in an average day at the office, the emergency department, or the hospital. If you have an original unpublished, high-quality color or black-and-white photograph representing such a typical image that you would like considered for publication, send it with a descriptive legend to Kim Eagle, M.D., University of Michigan Medical Center, Division of Cardiology, 3910 Taubman Center, Box 0366, 1500 East Medical Center Drive, Ann Arbor, MI 48109. For details about the size and labeling of the photographs, the requirements for the legend, and authorship, please contact Dr. Eagle at 313-936-5275 (phone) or 313-936-5256 (fax), or the *New England Journal of Medicine* at images@edit.nejm.org (e-mail).