

## ESOPHAGITIS ASSOCIATED WITH THE USE OF ALENDRONATE

PIET C. DE GROEN, M.D., DIETER F. LUBBE, M.B., CH.B., LAURENCE J. HIRSCH, M.D., ANASTASIA DAIFOTIS, M.D., WENDY STEPHENSON, M.D., M.P.H., DEBRA FREEDHOLM, B.S.N., SUZANNE PRYOR-TILLOTSON, M.S., MITCHEL J. SELEZNICK, M.D., HAIM PINKAS, M.D., AND KENNETH K. WANG, M.D.

### ABSTRACT

**Background** Alendronate, an aminobisphosphonate and a selective inhibitor of osteoclast-mediated bone resorption, is used to treat osteoporosis in postmenopausal women and Paget's disease of bone. Aminobisphosphonates can irritate the upper gastrointestinal mucosa.

**Methods** We describe three patients who had severe esophagitis shortly after starting to take alendronate and also analyze adverse esophageal effects reported to Merck, the manufacturer, through post-marketing surveillance.

**Results** As of March 5, 1996, alendronate had been prescribed for an estimated 475,000 patients worldwide, and 1213 reports of adverse effects had been received. A total of 199 patients had adverse effects related to the esophagus; in 51 of these patients (26 percent), including the 3 we describe in case reports, adverse effects were categorized as serious or severe. Thirty-two patients (16 percent) were hospitalized, and two were temporarily disabled. Endoscopic findings generally indicated chemical esophagitis, with erosions or ulcerations and exudative inflammation accompanied by thickening of the esophageal wall. Bleeding was rare, and stomach or duodenal involvement unusual. In patients for whom adequate information was available, esophagitis seemed to be associated with swallowing alendronate with little or no water, lying down during or after ingestion of the tablet, continuing to take alendronate after the onset of symptoms, and having preexisting esophageal disorders.

**Conclusions** Alendronate can cause chemical esophagitis, including severe ulcerations, in some patients. Recommendations to reduce the risk of esophagitis include swallowing alendronate with 180 to 240 ml (6 to 8 oz) of water on arising in the morning, remaining upright for at least 30 minutes after swallowing the tablet and until the first food of the day has been ingested, and discontinuing the drug promptly if esophageal symptoms develop. (N Engl J Med 1996;335:1016-21.)

©1996, Massachusetts Medical Society.

**A**LENDRONATE sodium, an aminobisphosphonate, is a selective inhibitor of osteoclast-mediated bone resorption. In a recently reported study of alendronate (Fosamax, Merck) for the treatment of postmenopausal osteoporosis, the drug progressively increased bone mass; decreased the incidence of vertebral fracture, deformity, and loss of stature over a period of

three years; and was well tolerated.<sup>1</sup> In the United States and elsewhere, alendronate is available by prescription for the treatment of postmenopausal osteoporosis (10 mg per day) and Paget's disease of bone (40 mg per day for six months).<sup>2</sup>

In an earlier, dose-ranging study, a dose of 40 mg of alendronate per day was associated with a small increase in upper gastrointestinal events, including esophagitis or gastritis, in women with postmenopausal osteoporosis<sup>3</sup>; no patient required hospitalization. One case report has described esophagitis and esophageal erosions in association with the use of alendronate.<sup>4</sup> Erosive esophagitis was reported with the use of an older, less potent aminobisphosphonate, pamidronate.<sup>5</sup> To reduce the potential for esophageal irritation, the original (September 1995) dose instructions for alendronate in the United States specified that it should be taken first thing in the morning with a full glass (180 to 240 ml [6 to 8 oz]) of plain water and at least 30 minutes before the first food or beverage of the day and that the patient should avoid lying down for at least 30 minutes after ingestion of the tablet.<sup>6</sup>

We report on three patients in whom severe esophagitis developed shortly after the start of treatment with alendronate. We also review adverse esophageal events reported to Merck among patients with prescriptions for alendronate.

### CASE REPORTS

#### Patient 1

Patient 1 was a 73-year-old woman without a history of gastrointestinal disease who had severe chest pain and dysphagia 12 hours after starting to take alendronate at a dose of 10 mg daily. She stopped taking the drug after the third dose, when her chest pain was so severe that she was admitted to an intensive care unit. The patient had taken alendronate with a full glass of water at 4:30 a.m., remained upright for 30 minutes, and returned to sleep for at least 1 hour before awaking to eat breakfast. Endoscopy demonstrated severe ulcerative esophagitis. Computed tomography showed thickened walls of the esophagus and gastric fundus. Despite treatment with omeprazole and intravenous morphine, her symptoms persisted.

From the Division of Gastroenterology (P.C.G., K.K.W.) and the Department of Medicine (D.E.L.), Mayo Clinic and Foundation, Rochester, Minn.; Merck Research Laboratories, Rahway, N.J. (L.J.H., A.D., W.S., D.E., S.P.-T.); and the Divisions of General Internal Medicine (M.J.S.) and Gastroenterology (H.P.), University of South Florida, Tampa. Address reprint requests to Dr. de Groen at the Division of Gastroenterology, Mayo Clinic and Foundation, 200 First St. S.W., Rochester, MN 55905.

The patient was transferred to the Mayo Clinic in February 1996. Further endoscopy confirmed severe ulcerative esophagitis affecting the entire length of the esophagus, which was more severe in the distal half (Fig. 1A), with mild gastritis and duodenitis. Biopsies showed ulceration and necrosis; multiple fungal and viral cultures were negative. Repeated computed tomographic studies confirmed the original findings (Fig. 1B). The patient was treated with total parenteral nutrition, intravenous H<sub>2</sub> blockers, and morphine. After recovery, barium studies of the esophagus and stomach showed a small hiatal hernia and recumbent reflux. She was discharged taking omeprazole and sucralfate slurry. One month later, nearly all the symptoms had resolved. In June 1996, repeated endoscopy showed a normal esophagus and superficial gastritis. When last seen on June 17, 1996, she was free of symptoms.

**Patient 2**

Patient 2 was an 84-year-old woman who had symptoms of dysphagia and odynophagia approximately four days after the initiation of treatment with alendronate (10 mg daily). She continued to take the drug and 10 days later was hospitalized for odynophagia and dehydration. The patient had taken alendronate with half a glass of water (90 to 120 ml [3 to 4 oz]), frequently while in a recumbent position. Her other medications consisted of thyroxine; vitamin C, D, and E supplements; calcium carbonate; an estrogen and progesterone preparation; enalapril; amitriptyline; glyburide for type II diabetes mellitus; and ranitidine because of previous gastritis caused by nonsteroidal antiinflammatory agents. Other than the alendronate, no new medicines had been taken during the preceding year.

Endoscopy showed severe, circumferential ulceration of the distal 10 cm of the esophagus, with a normal-appearing proximal esophagus. After discharge, the patient was given omeprazole (20 mg twice daily) for four weeks, followed by lansoprazole (30 mg daily). Alendronate was continued.

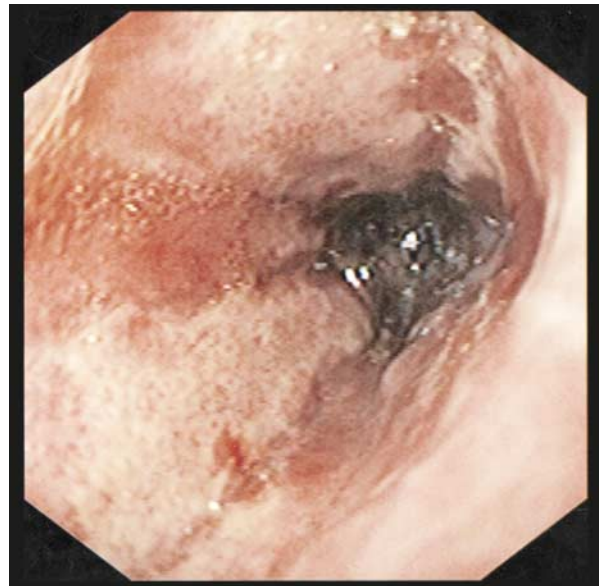The symptoms persisted. Six weeks later, computed tomographic images of the chest, as well as endoscopic ultrasonographic studies, showed marked thickening of the walls of the esophagus and a small hiatal hernia. Smears for fungi were negative. Esophageal biopsies showed marked acute and chronic inflammatory changes, with one focus suggesting neoplastic changes.

The patient was referred to the Mayo Clinic in February 1996, by which time she had lost 10 kg (22 lb) while continuing to take alendronate and her other medications. Repeated endoscopy with ultrasonography confirmed distal esophagitis with pronounced ulceration and circumferential wall thickening, without signs of neoplastic invasion. Alendronate was discontinued, and the patient was treated with lansoprazole and cisapride. Repeated endoscopy in March 1996 showed persistent circumferential ulcerations in the distal esophagus. The esophagus was dilated. As of July 1996, the patient was free of symptoms of esophagitis or a stricture.

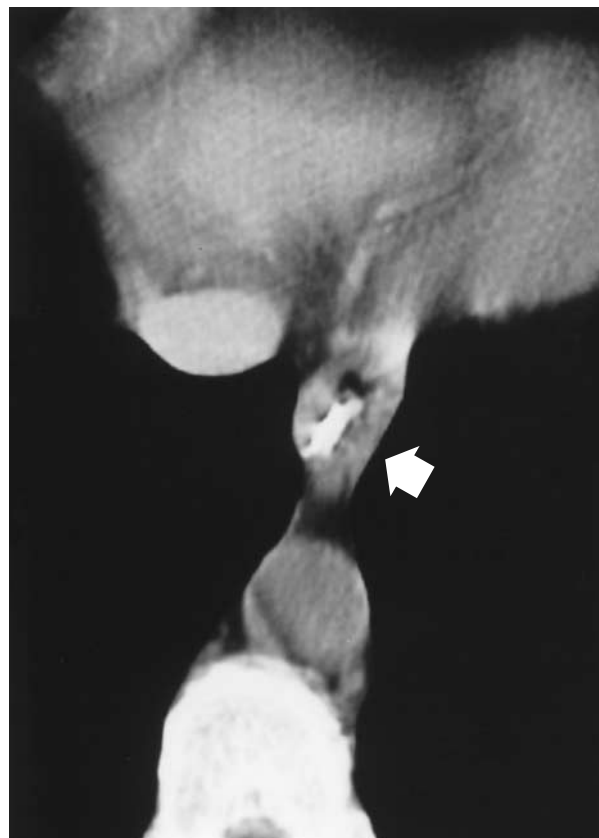**Patient 3**

Patient 3 was a 74-year-old woman who presented to the University of South Florida in February 1996 with a two-month history of progressive odynophagia and dysphagia, a weight loss of 0.9 to 1.4 kg (2 to 3 lb), and an episode of hematemesis. Four and a half years earlier, esophagogastroduodenoscopy for dyspepsia had shown three benign gastric ulcers and a normal esophagus. Repeated endoscopy after two months of treatment with ranitidine confirmed that the ulcer had healed; ranitidine was continued. Two months before presentation, she started taking alendronate (10 mg per day), ingesting the tablets with half a glass of water.

The patient had progressive odynophagia and dysphagia, which markedly impaired her oral intake, and hematemesis. A barium swallow examination showed esophagitis, a new stricture of the distal esophagus (3 to 4 cm in length), and a small hiatal hernia (Fig. 2). Endoscopy showed severe, circumferential ulceration of the distal 12 cm of the esophagus, with a very narrowed lumen,

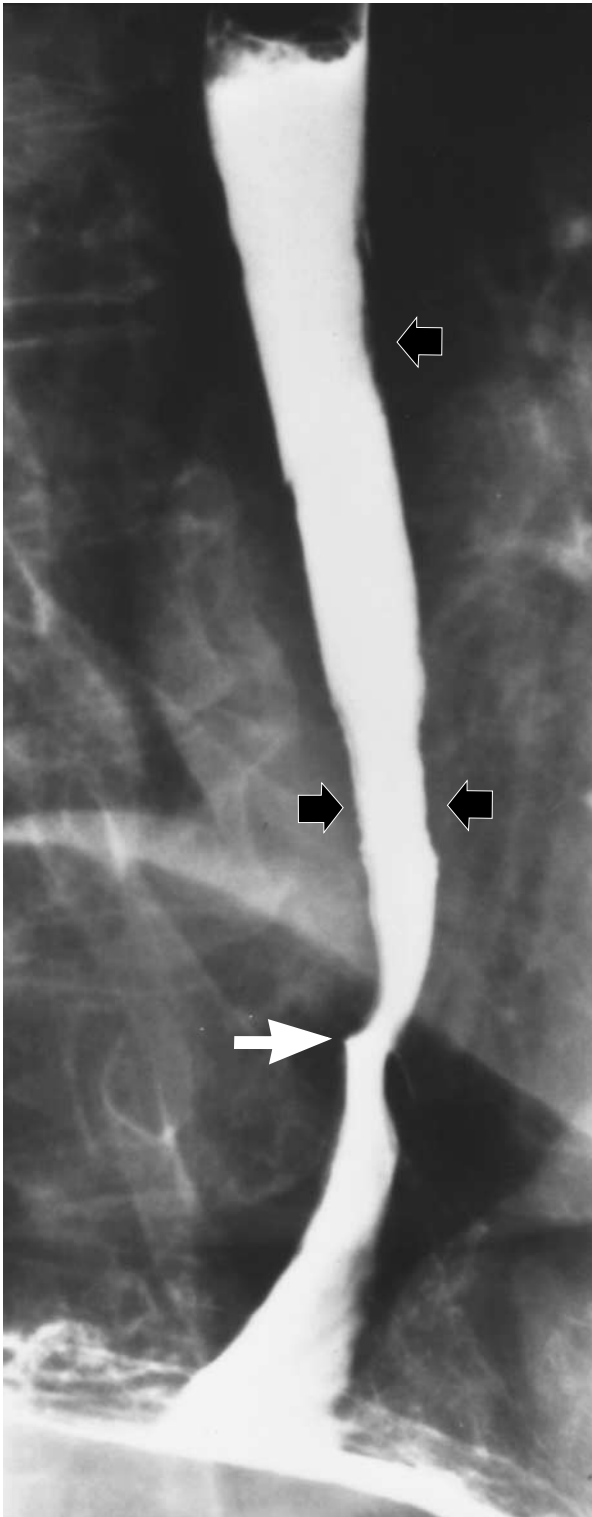


A



B

**Figure 1.** Endoscopic Image of the Esophagus (Panel A) and Contrast-Enhanced CT Scan of the Chest (Panel B) in Patient 1. Panel A shows severe, extensive hemorrhagic ulcerations and inflammatory exudates, which were still present in the distal esophagus on the ninth day of hospitalization. Panel B shows concentric esophageal-wall thickening (arrow) suggestive of transmural inflammation.



**Figure 2.** Barium-Contrast Film of the Esophagus in Patient 3. The irregularity of the mucosa is consistent with esophagitis (black arrows). The distal esophagus is strictured (white arrow).

and a normal stomach and duodenum. Alendronate was discontinued, and the patient was treated symptomatically with sucralfate slurry and lansoprazole. She underwent two esophageal dilations, one in March 1996 and one in April 1996. As of July 1996, she was free of symptoms.

## METHODS

We reviewed computerized data bases of post-marketing surveillance for reports of adverse esophageal events associated with the use of alendronate in which there were terms suggestive of esophageal irritation. The analysis included all reports received by Merck up to March 5, 1996. The following terms were considered suggestive of esophageal irritation: acid regurgitation, dyspepsia, dysphagia, erosive esophagitis, esophagalgia, esophagitis, hematemesis, esophageal hemorrhage, odynophagia, reflux esophagitis, esophageal perforation, esophageal stricture, and esophageal ulcer.

For the purpose of this analysis, a clinically serious adverse effect implied that the patient was hospitalized. A clinically severe adverse effect was defined as an endoscopically confirmed esophageal lesion or the acute onset of severe chest pain, dysphagia, or odynophagia requiring medical therapy.

The health care providers who had reported adverse effects classified as clinically serious or severe were contacted by mail or telephone for additional information. A standard questionnaire was used to gather data on the patients' demographic characteristics, concomitant medications and other conditions, and endoscopic and gastrointestinal radiographic studies, as well as the dose of alendronate and duration of its use, the time to the onset of symptoms, and the response to medical treatment. All cases of adverse effects, whether or not the reporters thought they were caused by the drug, are included in our analysis, as are cases first encountered during the follow-up of other reports. Estimates of the numbers of patients taking alendronate are based on Merck data on new prescriptions dispensed and visits at which physicians wrote prescriptions for alendronate in the United States, as well as on local sales data elsewhere.

## RESULTS

As of March 5, 1996, an estimated 470,000 patients worldwide had received prescriptions for alendronate for the treatment of osteoporosis (330,000 in the United States had received prescriptions since October 1995, for a total exposure of 710,000 person-months), and 5000 patients had received prescriptions for the treatment of Paget's disease. Merck had received a total of 1213 reports of adverse effects (1121 in the United States), of which 199 were related to the esophagus. Thirty-four patients had adverse esophageal effects classified as serious (32 [16 percent] were hospitalized, and 2 were temporarily disabled), and another 17 had esophageal effects classified as severe. Thus, 51 patients (26 percent) had adverse effects classified as serious or severe. Four of the 51 patients were seen at the Mayo Clinic or at the University of South Florida, and 46 of the 51 reports originated in the United States.

Forty-six of the patients were women, and two were men; the sex of the other three patients was not reported. Information on age was available for 36 of the patients, who were 23 to 85 years old (mean, 65); all but 2 were 48 years or older.

The most common terms in the reports on the 51 patients were esophageal ulcer, esophagitis, and ero-

sive esophagitis (Table 1). Esophageal perforation was not reported. Diagnostic endoscopy was performed in 36 patients. Appropriate information was available for 20 lesions, described as panesophageal in five patients, midesophageal or mid-distal in eight, and distal in seven. In one patient, severe esophagitis was limited to an 8-cm section of the midesophagus, and the stomach was normal. Severe dysphagia had developed in this patient after five days of treatment with alendronate (10 mg daily). The patient had taken each tablet with less than 180 ml of water, sometimes while in a supine position.

Information on the timing of symptoms was available for 43 patients. Forty-two patients had symptoms within two months after the start of treatment with alendronate, 39 within one month, and 19 within one week. Twenty-one of the 43 patients had serious adverse effects, and 12 of the 21 continued to take alendronate for a mean of 13 days (median, 9) after the onset of symptoms.

Nine of 34 patients with adequate information had a history of previous upper gastrointestinal disease (ulcers in 6, a hiatal hernia in 1, Crohn's disease with esophageal involvement in 1, and retrosternal burning in 1), and 1 patient had previously undiagnosed achalasia.

Of the 30 patients for whom relevant dose information was available, 16 had taken alendronate with less than 180 ml of water, including 2 who had taken the drug without water. Two patients described a sense of the tablet's being stuck, followed by the onset of symptoms of local irritation. In 18 of 33 reports with adequate information on the patient's posture, it was stated that the patient had not remained upright for 30 minutes or more after taking the tablet. These 18 patients included 5 who had taken alendronate at bedtime or during the night. Thus, 17 of 28 patients (61 percent) for whom information was available on both water intake and posture had taken alendronate incorrectly, according to the September 1995 dose instructions. The 11 other patients appear to have taken alendronate correctly. One of these patients had peptic ulcer disease, one had systemic lupus erythematosus and was being treated with hydroxychloroquine sulfate and salsalate, one had undergone a partial gastrectomy, and one had a history of esophagitis associated with Crohn's disease. One patient had taken alendronate in the early morning and had returned to sleep 30 minutes later, without eating (Patient 1).

One of the patients who were hospitalized had severe chest pain eight days after the start of treatment with alendronate, which she had taken in a supine position, without water, and on two occasions in the middle of the night. Alendronate was discontinued, and she recovered after treatment with omeprazole. Treatment with alendronate was resumed, with the patient taking each tablet with 180 to 240 ml of wa-

**TABLE 1.** PATIENTS WITH ADVERSE ESOPHAGEAL EFFECTS ASSOCIATED WITH THE USE OF ALENDRONATE, ACCORDING TO POST-MARKETING DATA.\*

ADVERSE EFFECT	NO. OF PATIENTS
Any effect†	199
Serious or severe effect†	51
Esophageal ulcer	22
Esophagitis	21
Erosive esophagitis	13
Esophagalgia or odynophagia‡	12
Dysphagia	11
Acid regurgitation or dyspepsia‡	5
Reflux esophagitis	4
Hematemesis or esophageal hemorrhage‡	2
Esophageal stricture	2

\*As of March 5, 1996, an estimated 475,000 patients worldwide had received prescriptions for alendronate.

†Patients with more than one type of event were counted only once.

‡Patients with both events were counted only once.

ter while upright. She has remained free of symptoms for six months, according to information obtained from her physician.

## DISCUSSION

Endoscopic findings in patients with esophagitis associated with alendronate were generally consistent with a chemical cause; some patients also had erosive or ulcerative mucosal damage with exudative inflammation, accompanied by thickening of the esophageal wall. Bleeding was rare, and stomach or duodenal involvement unusual. In most of the severe cases of esophageal complications identified by post-marketing surveillance, recovery occurred when alendronate was stopped, with additional treatments including an acid-suppressing agent or sucralfate or both, analgesia (local and systemic), and parenteral nutrition when necessary. Drug-induced acid suppression is not a substitute for the discontinuation of alendronate. Follow-up of patients for the possible development of esophageal strictures is important.

The current formulation of alendronate, the monosodium salt of alendronic acid, was developed to improve the drug's rate of dissolution and solubility (8 to 40 mg per milliliter of water, depending on the pH) and to optimize its absorption, which is essentially limited to the upper small intestine. The oral bioavailability of a 10-mg alendronate tablet, taken with plain water after an overnight fast and 2 hours before ingestion of the first food of the day, is 0.8 percent in women; when the drug is taken 30 or 60 minutes before breakfast, its oral bioavailability is reduced to approximately 0.5 percent.<sup>7</sup> The drug's

bioavailability is reduced to approximately 0.3 percent when alendronate is taken with coffee or orange juice instead of plain water and is negligible when taken up to two hours after a standardized breakfast.<sup>7</sup> The current formulation reduces the propensity for esophagitis observed with the earlier formulation of encapsulated alendronic acid.<sup>2,8-10</sup> In addition, to facilitate esophageal passage and to decrease mucosal adherence, alendronate has been formulated as a small, uncoated tablet.<sup>11-13</sup>

This tablet was also used in the three-year trials of alendronate in women with postmenopausal osteoporosis.<sup>1</sup> A reexamination of adverse esophageal effects in these trials revealed no evidence of a higher incidence of serious or severe adverse effects among patients taking alendronate than among those taking placebo, as reported elsewhere in this issue of the *Journal*.<sup>14</sup>

Adverse effects occurred at various points during the three-year study period. Most patients recovered without having to stop taking alendronate, and few were hospitalized. In contrast, most of the reported post-marketing events occurred soon after the start of treatment; about 25 percent of patients had serious or severe effects, and 16 percent required hospitalization. Given the variable post-marketing reporting rates for adverse effects,<sup>15</sup> the probability of an increased recognition of such effects soon after starting a new medication (particularly effects described in the product labeling), and the likely bias in favor of reporting more clinically severe effects, we could not estimate the average time from the start of treatment to the onset of esophagitis or calculate the true incidence of serious and severe adverse esophageal effects.

The apparent difference in the severity of adverse esophageal effects between the clinical trials and the surveillance data on early use of prescribed alendronate may in part reflect the nature of controlled studies, in which study participants have regularly scheduled follow-up visits, with frequent reinforcement of dose instructions. Study participants may also differ from other patients in terms of concomitant conditions and use of medication.

A report of erosive esophagitis in association with the use of pamidronate involved doses taken in the evening or at bedtime. Endoscopy showed lesions in the middle or distal portion of the esophagus, with relative sparing of the stomach and duodenum. The postulated pathophysiologic mechanisms were direct esophageal irritation, and possibly reflux of drug-containing gastric contents.<sup>5</sup>

Failure of the alendronate tablet to pass through the esophagus may result in prolonged local mucosal exposure to the drug. This possibility is consistent with the observation that lesions were circumscribed, with normal mucosa proximal and distal to the involved area, in some of our patients, as well as similar

observations in another report.<sup>4</sup> On the basis of the post-marketing reports with adequate information, the majority of patients appear to have taken alendronate with less than 180 ml of water or none, failed to remain upright afterward, or both. These factors are known to increase the risk of esophageal retention of swallowed tablets.<sup>12,13</sup> Tetracyclines, quinidine, ferrous sulfate, and potassium chloride produce esophagitis when ingested in this manner.<sup>16</sup> Patients frequently reported taking alendronate in a supine position or lying down shortly afterward, a position known to exacerbate gastroesophageal reflux. An esophageal lesion located in the distal esophagus, as reported in several patients, is consistent with a reflux-mediated process.

On the basis of the analyses reported here, the dose instructions for alendronate were revised worldwide to indicate that it should be taken when the patient is arising for the day, as follows<sup>17</sup>:

To facilitate delivery to the stomach and thus reduce the potential for esophageal irritation patients should be instructed to swallow [alendronate] with a full glass of water (6–8 oz) and not to lie down for at least 30 minutes *and* until after their first food of the day. Patients should not chew or suck on the tablet. Patients should be specifically instructed not to take [alendronate] at bedtime or before arising for the day. Patients should be informed that failure to follow these instructions may increase their risk of esophageal problems. Patients should be instructed that if they develop symptoms of esophageal disease (such as difficulty or pain upon swallowing, retrosternal pain or new or worsening heartburn) they should stop taking [alendronate] and consult their physician.

Previously, cautious use of alendronate was advised in patients with active upper gastrointestinal problems.<sup>6</sup> Now, alendronate is contraindicated in patients with “abnormalities of the esophagus which delay esophageal emptying such as stricture or achalasia” or “inability to stand or sit upright for at least 30 minutes.”<sup>17</sup>

In summary, alendronate can cause chemical esophagitis, including severe ulcerations in some patients. Factors that may contribute to the development of severe esophagitis include taking alendronate with less than 180 ml of water, taking alendronate in a supine position, lying down after ingesting the tablet, continuing to take alendronate after the onset of symptoms suggestive of esophagitis, and having preexisting esophageal disorders that would prolong mucosal exposure to the drug.

Supported by the Mayo Clinic and Foundation and by Merck and Company.

*We are indebted to Alan J. Cameron, M.D., Douglas B. McGill, M.D., Vandana Nebra, M.D., and A. John Yates, M.D., for their referrals of patients, helpful suggestions, and critical review of the manuscript.*

## REFERENCES

1. Liberman UA, Weiss SR, Bröll J, et al. Effect of oral alendronate on bone mineral density and the incidence of fractures in postmenopausal osteoporosis. *N Engl J Med* 1995;333:1437-43.
2. Siris E, Weinstein RS, Altman R, et al. Comparative study of alendronate *versus* etidronate for the treatment of Paget's disease of bone. *J Clin Endocrinol Metab* 1996;81:961-7.
3. Chesnut CH III, McClung MR, Ensrud KE, et al. Alendronate treatment of the postmenopausal osteoporotic woman: effect of multiple dosages on bone mass and bone remodeling. *Am J Med* 1995;99:144-52.
4. Maconi G, Porro GB. Multiple ulcerative esophagitis caused by alendronate. *Am J Gastroenterol* 1995;90:1889-90.
5. Lufkin EG, Argueta R, Whitaker MD, et al. Pamidronate: an unrecognized problem in gastrointestinal tolerability. *Osteoporos Int* 1994;4:320-2.
6. Fosamax (alendronate sodium tablets). West Point, Pa.: Merck, 1995 (package insert).
7. Gertz BJ, Holland SD, Kline WF, et al. Studies of the oral bioavailability of alendronate. *Clin Pharmacol Ther* 1995;58:288-98.
8. Adami S, Passeri M, Ortolani S, et al. Effects of oral alendronate and intranasal salmon calcitonin on bone mass and biochemical markers of bone turnover in postmenopausal women with osteoporosis. *Bone* 1995;17:383-90.
9. Adami S, Zamberlan N. Adverse effects of bisphosphonates: a comparative review. *Drug Saf* 1996;14:158-70.
10. Adami S, Mian M, Gatti P, et al. Effects of two oral doses of alendronate in the treatment of Paget's disease of bone. *Bone* 1994;15:415-7.
11. Marvola M, Rajaniemi M, Marttila E, Vahervuo K, Sothmann A. Effect of dosage form and formulation factors on the adherence of drugs to the esophagus. *J Pharm Sci* 1983;72:1034-6.
12. Channer KS, Virjee JP. The effect of size and shape of tablets on their esophageal transit. *J Clin Pharmacol* 1986;26:141-6.
13. Hey H, Jorgensen F, Sorensen K, Hasselbalch H, Wamberg T. Oesophageal transit of six commonly used tablets and capsules. *BMJ* 1982;285:1717-9.
14. Liberman UA, Hirsch LJ. Esophagitis and alendronate. *N Engl J Med* 1996;335:1069-70.
15. Inman WHW. The United Kingdom. In: Inman WHW, ed. Monitoring for drug safety. Philadelphia: J.B. Lippincott, 1980:9-47.
16. Bozymski EM, Isaacs KL. Medications reported to cause esophageal damage. In: Yamada T, ed. Textbook of gastroenterology. 2nd ed. Vol. 1. Philadelphia: J.B. Lippincott, 1995:1283-301.
17. Fosamax (alendronate sodium tablets). West Point, Pa.: Merck, 1996 (package insert).