

OVEREXPRESSION OF AN OSTEOGENIC MORPHOGEN IN FIBRODYSPLASIA OSSIFICANS PROGRESSIVA

ADAM B. SHAFRITZ, B.A., EILEEN M. SHORE, PH.D., FRANCIS H. GANNON, M.D., MICHAEL A. ZASLOFF, M.D., PH.D., REBECCA TAUB, M.D., MAXIMILIAN MUENKE, M.D., AND FREDERICK S. KAPLAN, M.D.

ABSTRACT

Background Fibrodysplasia ossificans progressiva is a heritable disorder of connective tissue characterized by congenital malformation of the great toes and postnatal formation of ectopic bone. Although the disorder was first described more than 300 years ago, the genetic defect and pathophysiology remain unknown. Bone morphogenetic proteins are potent bone-inducing morphogens that participate in the developmental organization of the skeleton, and increased production of one or more of these proteins has been proposed as the cause of fibrodysplasia ossificans progressiva.

Methods We studied lymphoblastoid cell lines established from peripheral-blood mononuclear cells of patients with fibrodysplasia ossificans progressiva and fibroblast-like cell lines derived from lesional and nonlesional tissue. We used Northern blot analysis and ribonuclease protection assays to measure the expression of messenger RNA (mRNA) of bone morphogenetic proteins 1 to 7 and immunohistochemical analysis to examine protein expression.

Results Among the bone morphogenetic proteins and mRNAs examined, only bone morphogenetic protein 4 and its mRNA were present in increased levels in cells derived from an early fibroproliferative lesion in a patient with fibrodysplasia ossificans progressiva. Bone morphogenetic protein 4 mRNA was expressed in lymphoblastoid cell lines from 26 of 32 patients with fibrodysplasia ossificans progressiva but from only 1 of 12 normal subjects ($P < 0.001$). Bone morphogenetic protein 4 and its mRNA were detected in the lymphoblastoid cell lines from a man with fibrodysplasia ossificans progressiva and his three affected children (two girls and a boy), but not from the children's unaffected mother. No other bone morphogenetic proteins were detected.

Conclusions Overexpression of a potent bone-inducing morphogen (bone morphogenetic protein 4) in lymphocytes is associated with the disabling ectopic osteogenesis of fibrodysplasia ossificans progressiva. (N Engl J Med 1996;335:555-61.)

©1996, Massachusetts Medical Society.

THE human skeleton is a complex organ system consisting of more than 200 articulated bones of various shapes and sizes. During embryogenesis, the skeleton develops from undifferentiated mesenchyme according to a genetic plan that controls its precise temporal and spatial formation. Postnatally, the initiation of osteogenesis is normally restricted to the regeneration of bone at fracture sites. Heterotopic ossification results from an alteration in the normal regulation of osteogenesis, leading to ectopic bone formation. Fibrodysplasia ossificans progressiva, first described in 1692, is the most extensive disorder of heterotopic osteogenesis in humans and results in the postnatal formation of ectopic bone. The genetic defect and pathophysiology are not known.

Fibrodysplasia ossificans progressiva is an autosomal dominant disorder of connective tissue characterized by congenital malformation of the great toes and progressive, disabling heterotopic osteogenesis in predictable anatomical patterns.¹⁻⁴ Spontaneous or trauma-induced exacerbations of fibrodysplasia ossificans progressiva during childhood are characterized by soft-tissue swelling; localized heat, erythema, and tenderness; low-grade fever; and an elevated erythrocyte sedimentation rate.⁵ Histopathological studies of pre-osseous lesions (obtained before the diagnosis of fibrodysplasia ossificans progressiva) reveal lymphocytic infiltration and muscle-cell degeneration,⁶ followed by the appearance of highly vascular, fibroproliferative tissue and then by endochondral ossification with mature lamellar bone and marrow elements.⁷

Heterotopic ossification in fibrodysplasia ossificans progressiva begins in childhood and can be induced by intramuscular injections.⁸ Severe scoliosis may develop as a result of asymmetric heterotopic ossification of paravertebral muscles.⁹ By early adulthood, heterotopic ossification leads typically to ankylosis of all major joints of the axial and appendicular skeleton, rendering movement impossible^{4,5} (Fig. 1). Most patients are confined to a wheelchair by their

From the Departments of Orthopaedic Surgery (A.B.S., E.M.S., M.A.Z., F.S.K.), Pathology (F.H.G.), Medicine (R.T., F.S.K.), and Genetics (R.T.), University of Pennsylvania School of Medicine; and the Division of Human Genetics and Molecular Biology, Children's Hospital of Philadelphia (M.M.) — both in Philadelphia. Address reprint requests to Dr. Kaplan at the Division of Metabolic Bone Diseases and Molecular Orthopaedics, Department of Orthopaedic Surgery, Hospital of the University of Pennsylvania, Silverstein 2, 3400 Spruce St., Philadelphia, PA 19104.

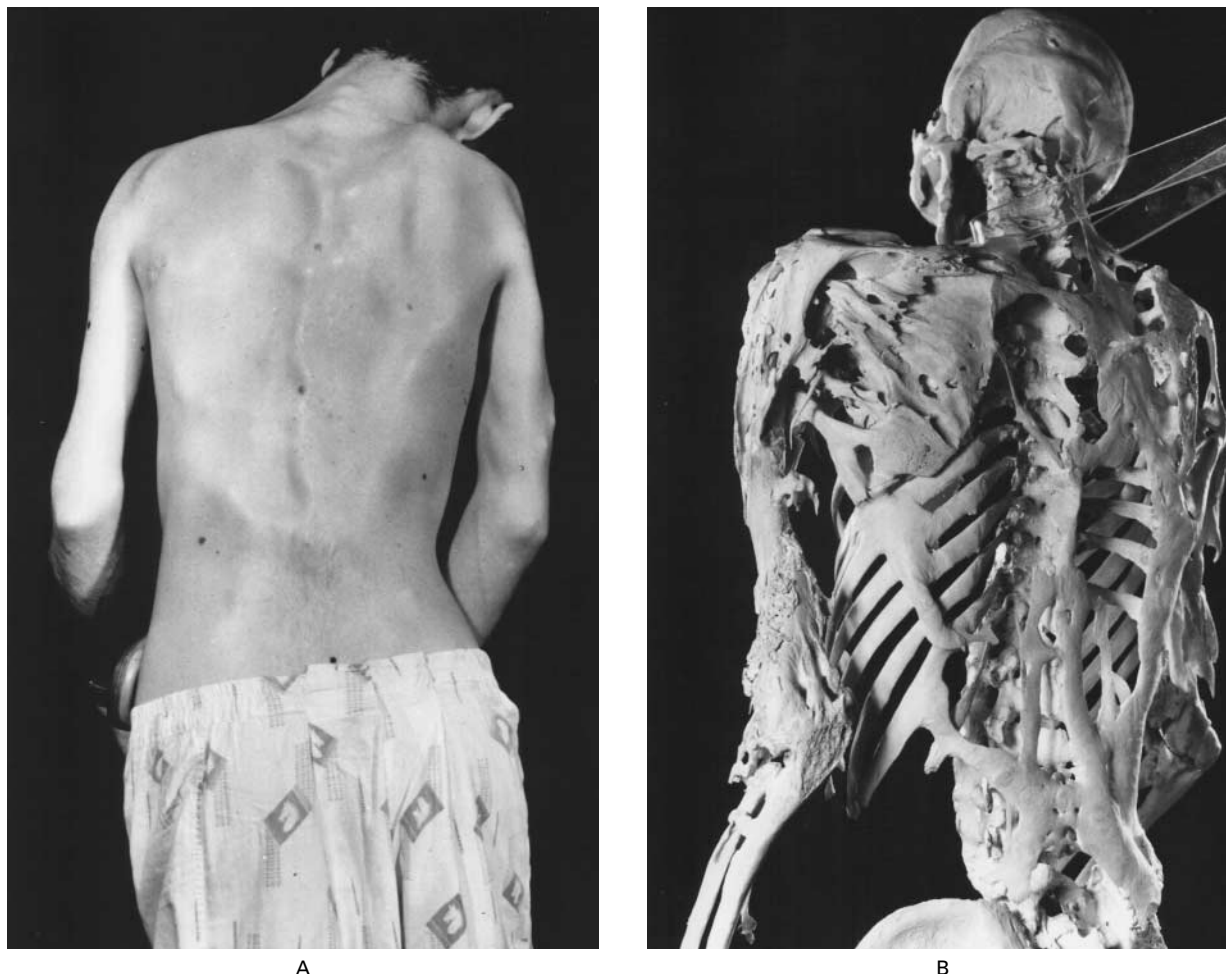

Figure 1. Clinical Appearance and Skeleton of a Man with Fibrodysplasia Ossificans Progressiva.

The rigid posture in this 25-year-old man with fibrodysplasia ossificans progressiva was due to ankylosis of the spine, shoulders, and elbows. He died of pneumonia at the age of 40 years. Plates and ribbons of ectopic bone contour the skin over the back and arms (Panel A), and can be seen directly on the skeleton (Panel B). Courtesy of the Mütter Museum, College of Physicians of Philadelphia.

early 20s and require lifelong assistance in performing activities of daily living.^{1,4} Starvation may result from ankylosis of the jaw, and pneumonia may occur as a complication of fixation of the chest wall.⁵ Surgical trauma associated with the resection of heterotopic bone leads to the exacerbation of local ossification.⁵ At present, there is no effective means of prevention or treatment.

Studies to identify the cause of fibrodysplasia ossificans progressiva are currently focused on the candidate-gene approach,¹⁰ since karyotypic abnormalities have not been detected in patients with the disorder³ and lesional tissue is not readily available for study.⁷ Definitive linkage analysis is not possible, since only three small families with inheritance of fibrodysplasia ossificans progressiva have been identified worldwide,^{2,3,11} and the molecular defect is not

known. In this article, we provide evidence that a potent bone-inducing morphogen, bone morphogenetic protein 4, is overexpressed in the lymphocytes of patients with fibrodysplasia ossificans progressiva.

METHODS

Patients and Cell Lines

From 1990 to 1995, 62 patients with fibrodysplasia ossificans progressiva were referred to the Fibrodysplasia Ossificans Progressiva Working Group at the University of Pennsylvania. Lymphoblastoid cell lines were established from peripheral-blood mononuclear cells in 32 patients and 12 normal subjects by transformation of the cells by Epstein-Barr virus.¹² The protocols were approved by the institutional review boards of the Children's Hospital of Philadelphia and the University of Pennsylvania, and informed consent was obtained from all patients or their parents.

Primary cell lines were established from pre-osseous lesional tissue from a 15-year-old boy with fibrodysplasia ossificans progres-

siva, after resection of a lesion affecting the muscles of mastication; uninvolved skin and subcutaneous tissue from an 8-year-old girl with fibrodysplasia ossificans progressiva, removed at the time of an emergency craniotomy for resection of a craniopharyngioma (an apparently unrelated condition); skin and subcutaneous tissue from a normal infant; paraspinal muscle from a normal 4-year-old girl; and temporalis muscle from three normal children, ages 1, 6, and 14 years, who had undergone unrelated neurosurgical procedures. The skin fibroblast cells from the normal infant were used as a negative control, and the U-2 OS osteosarcoma cell line (American Type Culture Collection) was used as a positive control for the expression of bone morphogenetic proteins.¹³

Cell Culture

Primary cultures of fibroblast-like cells were established in Dulbecco's modified Eagle's medium containing 2.5 μg of amphotericin B (Fungizone) per milliliter, 50 μg of gentamicin per milliliter, and 15 percent fetal-calf serum. The U-2 OS osteosarcoma cells were grown in McCoy's 5A medium and 2.5 μg of amphotericin B per milliliter, 50 μg of gentamicin per milliliter, and 10 percent fetal-calf serum. Lymphoblastoid cell lines were grown in RPMI 1640 medium containing 100 units of penicillin per milliliter, 100 μg of streptomycin per milliliter, 0.25 μg of amphotericin B per milliliter, and 15 percent fetal-calf serum. All tissue-culture reagents were obtained from Life Technologies (Gaithersburg, Md.). The control and fibrodysplasia ossificans progressiva lymphoblastoid cell lines were coded and run together in all assays, and the results were read in a blinded fashion.

Preparation of RNA

Total RNA was isolated from lymphoblastoid cell lines and primary cells in culture by extraction with guanidine isothiocyanate and phenol-chloroform-isoamyl alcohol.¹⁴ Poly(A)⁺ RNA was prepared from total cellular RNA with oligo(dT) cellulose (5Prime-3Prime, Boulder, Colo.).

Complementary DNA Clones

Plasmid clones containing human complementary DNA (cDNA) inserts from the following genes were used as templates for labeled-probe synthesis in Northern blot analyses and ribonuclease protection assays: collagen types I and II, osteocalcin, and alkaline phosphatase (liver-bone-kidney type) (used to establish the cell phenotype); *c-fos*, *c-jun*, *jun B*, *jun D*, and transforming growth factor $\beta 1$ (TGF- $\beta 1$) (genes involved in the early cellular response and terminal differentiation pathways of chondro-osseous development)^{15,16}; *MSX-2* (a homeobox gene induced during osteogenesis)¹⁷; and bone morphogenetic proteins 1 to 7 and growth-differentiation factor 5 (members of the family of bone morphogenetic proteins).¹⁵ The expression of glyceraldehyde-3-phosphate dehydrogenase was used as an internal standard.

Northern Blot Analysis

With the use of standard methods,¹⁸ poly(A)⁺ RNAs (4 μg) from cultured human cells were electrophoresed through 0.8 percent agarose formaldehyde denaturing gels, transferred to nylon membranes (MagnaGraph, MSI, Westborough, Mass.), and prehybridized with 5 \times saline sodium citrate (SSC; 1 \times SSC is 0.15 M sodium chloride and 0.015 M sodium citrate per liter), 50 percent formamide, 6 \times Denhardt's solution (1 \times Denhardt's solution is 0.02 percent Ficoll, 0.02 percent polyvinylpyrrolidone, and 0.02 percent bovine serum albumin), 300 mg of denatured salmon-sperm DNA per milliliter of solution, and 0.1 percent sodium dodecyl sulfate at 42°C. Probe cDNAs were labeled with [α -³²P]deoxycytidine triphosphate by random-primer extension. Membranes were hybridized with 2 \times 10⁶ cpm of probe per milliliter in 50 percent formamide, 5 \times SSC, 3 \times Denhardt's solution, 150 mg of denatured salmon-sperm DNA per milliliter, and 0.1 percent sodium dodecyl sulfate. The blots were washed under conditions designed to remove nonspecific hybridization and were

then subjected to autoradiography. To remove labeled cDNA for reprobing, the hybridized blots were incubated in 60 percent formamide, 50 mM TRIS-hydrochloric acid (pH 8.0), and 1 percent sodium dodecyl sulfate for one hour at 75°C.

Ribonuclease Protection Assays

Antisense RNA probes were synthesized by in vitro transcription (MAXIscript, Ambion, Austin, Tex.), and full-length transcripts were purified from a 5 percent acrylamide, 8 M urea gel with 0.5 M ammonium acetate, 1 mM EDTA, and 0.1 percent sodium dodecyl sulfate. For each ribonuclease protection assay, 150,000 cpm of [³²P]-labeled antisense RNA was used according to recommended protocols (RPA II, Ambion). The samples were denatured and electrophoresed through a 5 percent acrylamide, 8 M urea gel. The dried gel was subjected to autoradiography and then exposed to a phosphor screen. Messenger RNAs (mRNAs) were quantitated with either a Computing densitometer (model 300A, Molecular Dynamics, Sunnyvale, Calif.) or a PhosphorImager (Molecular Dynamics).

Immunohistochemical Analysis

Lymphoblastoid cells from 10 patients with fibrodysplasia ossificans progressiva and 10 normal subjects were applied to uncoated glass slides. The cells were stained according to standard immunoperoxidase protocols with antibody against bone morphogenetic proteins 2 and 4 (1:3000 dilution), counterstained with Wright's stain, and examined under light microscopy. Slides of an osteosarcoma (positive control) and liver tissue (negative control) were stained simultaneously (data not shown).

RESULTS

Pattern of mRNA Expression in Cells from a Fibrodysplasia Ossificans Progressiva Lesion

The expression of mRNAs of genes related to bone and cartilage development in pre-osseous lesional tissue from a patient with fibrodysplasia ossificans progressiva was evaluated by Northern blot analysis. The lesional cells were morphologically similar to skin fibroblasts. The pattern of gene expression of the two types of cells was similar, with the exception of mRNA of bone morphogenetic protein 4, which was detected in the lesional cells from a patient with fibrodysplasia ossificans progressiva but not in skin fibroblasts from normal subjects or the patient (Table 1). Bone morphogenetic protein 4 was the only TGF- β -like bone morphogenetic protein expressed in the early lesional cells. There was no detectable expression of bone morphogenetic protein 2, 3, 5, 6, or 7; collagen type II; osteocalcin; or *MSX-2* in either lesional cells or normal skin fibroblasts (Table 1). Type I collagen mRNA was expressed at higher levels by skin fibroblasts than by lesional cells from patients with fibrodysplasia ossificans progressiva. The levels of expression of alkaline phosphatase, *c-fos*, *c-jun*, *jun B*, *jun D*, TGF- $\beta 1$, and growth-differentiation factor 5 were similar in lesional cells and normal skin fibroblasts.

Expression of Bone Morphogenetic Protein mRNA in Nonlesional and Lesional Cell Lines from Patients with Fibrodysplasia Ossificans Progressiva

RNAs from cell lines established from lesional and nonlesional sites from patients with fibrodysplasia os-

sificans progressiva and from the same sites in normal subjects matched for age and sex were evaluated for the expression of bone morphogenetic proteins 1 to 7 by ribonuclease protection assays (Fig. 2). Bone morphogenetic protein 1 mRNA was expressed in all cell lines examined, although the level of expression varied. Bone morphogenetic protein 2 mRNA, which was not detected by Northern blot analysis (Table 1), was expressed at very low levels in all the cell lines (data not shown). The expression of bone morphogenetic protein 4 mRNA was barely detectable in nonlesional cells from a patient with fibrodysplasia ossificans progressiva (Fig. 2, lane 3) and in normal skin fibroblasts (Fig. 2, lane 4). All the muscle-cell lines (Fig. 2, lanes 5, 6, 7, and 8) from normal subjects expressed bone morphogenetic protein 4 mRNA, but the highest level of expression was in the cell line from early lesional tissue from a patient with fibrodysplasia ossificans progressiva (Fig. 2, lane 2); in this cell line the level of expression was approximately 12 times greater than in cell lines derived from normal muscle or fascia.

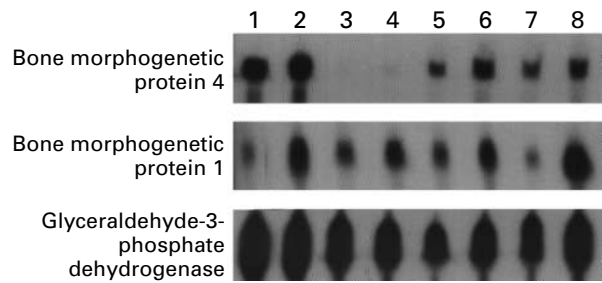


Figure 2. Expression of mRNA of Bone Morphogenetic Protein 4. Total RNA was analyzed for mRNA of bone morphogenetic proteins 4 and 1 by a ribonuclease protection assay with the probes indicated to the left of each row. The expression of glyceraldehyde-3-phosphate dehydrogenase mRNA served as an internal standard. RNA samples were prepared from U-2 OS osteosarcoma cells (positive control) (lane 1); pre-osseous lesional cells from a patient with fibrodysplasia ossificans progressiva (lane 2); skin and subcutaneous cells from another patient with fibrodysplasia ossificans progressiva (lane 3); skin and subcutaneous tissue from a normal subject (lane 4); temporalis muscle, tendon, and fascia from normal subjects who were 14 years old (lane 5), 6 years old (lane 6), and 1 year old (lane 7); and cervical paraspinal muscle, tendon, and fascia from a normal 4-year-old subject (lane 8).

TABLE 1. EXPRESSION OF mRNA OF GENES RELATED TO BONE AND CARTILAGE DEVELOPMENT.*

mRNA	SKIN FIBROBLASTS FROM A NORMAL INFANT	LESIONAL CELLS FROM A PATIENT WITH FIBRODYSPLASIA OSSIFICANS PROGRESSIVA	U-2 OS OSTEOSARCOMA CELLS
Collagen type I	+++	++	+
Collagen type II	-	-	+/-
Alkaline phosphatase	+	+	+
Osteocalcin	-	-	-
<i>c-fos</i>	+	+	++
<i>c-jun</i>	++	++	++
<i>jun B</i>	++	++	++
<i>jun D</i>	+/-	+/-	+/-
<i>MSX-2</i>	-	-	-
TGF- β 1	++	++	++
Bone morphogenetic protein			
1	++	+	+
2	-	-	++
3	-	-	+/-
4	-	+	++
5	-	-	+
6	-	-	+
7	-	-	++
Growth-differentiation factor 5	-	-	+
Glyceraldehyde-3-phosphate dehydrogenase	++++	++++	++++

*The ++++ symbol indicates an intense signal after 2 hours of exposure of a hybridized Northern blot to x-ray film (see the Methods section); +++ indicates an intense signal after 12 hours of exposure; ++ indicates a strong signal within 24 hours; + indicates a signal that was easily seen within a 3-day period; and +/- indicates a faint signal at 7 days. The - symbol indicates that no signal was detected after seven days of exposure at -70°C with two intensifier screens.

Expression of Bone Morphogenetic Protein mRNA in Lymphoblastoid Cell Lines from Patients with Fibrodysplasia Ossificans Progressiva

In order to determine whether dysregulation of the expression of the bone morphogenetic protein 4 gene was a generalized feature of fibrodysplasia ossificans progressiva, RNAs isolated from lymphoblastoid cell lines from 32 patients with fibrodysplasia ossificans progressiva and 12 normal subjects were examined for the expression of mRNAs of bone morphogenetic proteins 1 to 7 by a ribonuclease protection assay. Only the expression of bone morphogenetic protein 4 mRNA differed between lymphoblastoid cell lines derived from patients with fibrodysplasia ossificans progressiva and normal subjects (Fig. 3). Lymphoblastoid cell lines from 26 of the 32 patients with fibrodysplasia ossificans progressiva expressed bone morphogenetic protein 4 mRNA, as compared with only 1 of 12 normal subjects (P<0.001). No other bone morphogenetic proteins were expressed by either group of cells. There was no apparent correlation between age, sex, or severity of disease activity and the presence or magnitude of expression of bone morphogenetic protein 4 mRNA.

In order to study the expression of bone morphogenetic protein 4 mRNA in lymphoblastoid cell lines derived from a kindred with fibrodysplasia ossificans progressiva, a family with genetic transmission of the disorder from parent to offspring³ was evaluated by a ribonuclease protection assay. Bone morphogenetic protein 4 mRNA was detected in cells derived from all four family members with fibrodysplasia ossificans

progressiva — the father, two daughters, and a son — but not in cells from the unaffected mother (Fig. 4).

Immunohistochemical Evaluation of Bone Morphogenetic Protein 4 in Lymphoblastoid Cell Lines

Immunohistochemical analysis of cultured cells was used to determine whether bone morphogenetic protein 4 was present in lymphoblastoid cell lines from patients with fibrodysplasia ossificans progressiva and normal subjects. The antibody we used recognizes bone morphogenetic proteins 2 and 4, but because bone morphogenetic protein 2 mRNA was not detected in these cells, antibody binding indicated the presence of bone morphogenetic protein 4. This protein was detected in the lymphoblastoid cells from 10 patients with fibrodysplasia ossificans progressiva but not in 10 normal subjects (Fig. 5).

DISCUSSION

The bone morphogenetic proteins, a family of potent osteogenic agents in the TGF- β superfamily of peptides, induce endochondral osteogenesis and fracture healing.^{13,15,19-28} These substances act by diffusion in a concentration-dependent manner to specify the fate of cells in embryogenesis and bone regeneration.^{15,27-30} Bone morphogenetic proteins are unique in their ability to induce the complete cellular program of endochondral osteogenesis at heterotopic sites in vivo.^{13,15,31,32} Our study provides evidence that overexpression of a bone morphogenetic protein is associated with a disabling disorder of osteogenesis in humans.

We previously proposed that overexpression of a bone morphogenetic protein gene may be involved in the gain of function leading to heterotopic ossification in patients with fibrodysplasia ossificans progressiva.¹⁰ The results of this study suggest a mechanism to explain the pathophysiology of heterotopic bone formation in this disorder. Since the half-life of bone morphogenetic protein is extremely brief (only a few minutes), it is unlikely that osteogenesis-inducing concentrations of bone morphogenetic protein 4 could be achieved at sites of osteogenesis unless the morphogen is delivered to those sites by circulating cells or manufactured at those sites by mesenchymal cells. As evidence, Chinese-hamster-ovary cells transfected with bone morphogenetic protein 4 and implanted at soft-tissue sites in mice induce ectopic ossification at the sites of implantation but not at remote locations.^{31,32}

We propose that lymphocytes capable of expressing bone morphogenetic protein 4 circulate in the peripheral blood of patients with fibrodysplasia ossificans progressiva and are recruited to connective tissue after soft-tissue injury.^{33,34} Type IV collagen, a primary constituent of the basement membrane of endothelial cells and muscle cells, avidly binds bone morphogenetic protein 4,³⁵ resulting in in-

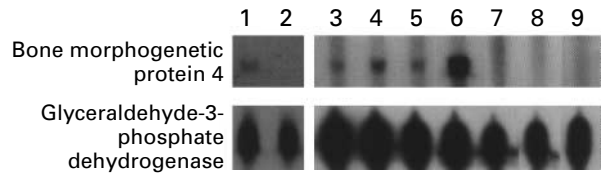


Figure 3. Expression of Bone Morphogenetic Protein 4 mRNA in Immortalized Lymphoblastoid Cell Lines from Patients with Fibrodysplasia Ossificans Progressiva and Normal Subjects.

RNAs from lymphoblastoid cell lines were analyzed for the expression of mRNA of bone morphogenetic protein 4 by a ribonuclease protection assay. The expression of glyceraldehyde-3-phosphate dehydrogenase mRNA served as an internal standard. Lanes 1, 3, 4, 5, and 6 show RNA from patients with fibrodysplasia ossificans progressiva; lanes 2, 7, 8, and 9 show RNA from normal subjects. The samples from patients with fibrodysplasia ossificans progressiva are representative of the range of detectable bone morphogenetic protein 4 mRNA. Quantitation by densitometry (with correction for film background levels and glyceraldehyde-3-phosphate dehydrogenase levels) yielded values of zero for samples negative for bone morphogenetic protein 4 (11 of 12 normal subjects and 6 of 32 patients with fibrodysplasia ossificans progressiva). The one normal subject scored as positive for bone morphogenetic protein 4 mRNA had a value equal to the lowest positive value measured for any patient with fibrodysplasia ossificans progressiva. The range of expression of bone morphogenetic protein 4 mRNA in the patients varied by a factor of about 20 from the weakest positive signal (lane 3) to the strongest positive signal (lane 6).

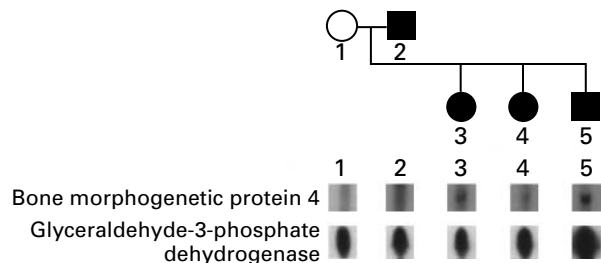
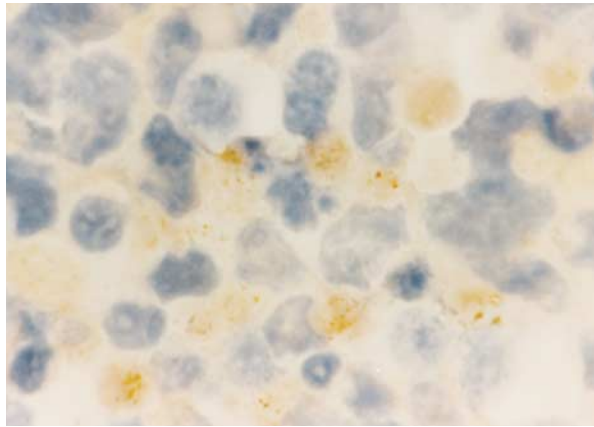


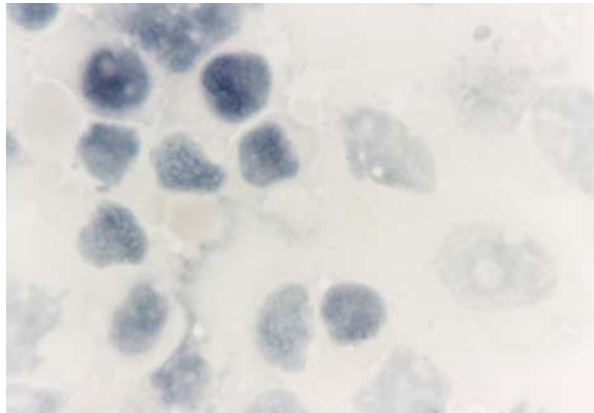
Figure 4. Expression of Bone Morphogenetic Protein 4 mRNA in a Family with Fibrodysplasia Ossificans Progressiva.

The pedigree of a family with genetic transmission of fibrodysplasia ossificans progressiva from parent to offspring is shown. Circles denote female family members, squares male family members, and solid symbols affected family members. The father, both daughters, and the son all have fibrodysplasia ossificans progressiva. The mother is unaffected. RNA from lymphoblastoid cell lines established from each subject was examined for bone morphogenetic protein 4 mRNA by a ribonuclease protection assay. The unaffected mother's lymphoblastoid cells did not express bone morphogenetic protein 4 mRNA, whereas lymphoblastoid cells from the father and all three children did express it. The expression of glyceraldehyde-3-phosphate dehydrogenase mRNA served as an internal standard for the amount of RNA in each lane.

creased local concentrations. At high concentrations, bone morphogenetic protein 4 acts as a morphogen^{13,15,19,36} capable of up-regulating its own mesenchymal expression²² and leading to the development of pre-osseous fibroproliferative lesions.¹³



A



B

Figure 5. Expression of Bone Morphogenetic Protein in Cells from a Patient with Fibrodysplasia Ossificans Progressiva (Panel A) and a Normal Subject (Panel B) ($\times 1250$).

The cells were stained with an antibody that detects bone morphogenetic proteins 2 and 4. A positive immunoperoxidase reaction product (brown staining) is seen only in the cytoplasm of lymphoblastoid cells from the patient. Cell nuclei stain blue with the counterstain (Wright's stain).

The appearance of lymphocytes in the perivascular space of the earliest detectable lesion of fibrodysplasia ossificans progressiva⁶ provides support to the view that lymphocytes and perivascular cells are involved in the induction of osteogenesis.^{37,38}

The stringent temporal and spatial patterns of postnatal heterotopic ossification in patients with fibrodysplasia ossificans progressiva are reminiscent of the patterns of mesenchymal-cell condensation during skeletal embryogenesis and suggest a common molecular basis for prenatal and postnatal osteogenesis.^{1,4,5,15} In humans postnatal osteogenesis occurs most commonly during healing of fractures. The creation of callus at a fracture site and heterotopic bone formation in fibrodysplasia ossificans progres-

siva follow nearly identical endochondral pathways⁷ involving lymphocytes^{6,37} and increases in the level of bone morphogenetic protein 4.^{25,26}

Dysregulation of bone morphogenetic protein during skeletal embryogenesis provides a tantalizing model for skeletal malformations in neonates with fibrodysplasia ossificans progressiva.⁵ In mice, naturally occurring mutations of bone morphogenetic protein genes result in congenital abnormalities of the skeleton and in postnatal abnormalities in fracture repair.^{15,23,24} Homozygous deletions of bone morphogenetic protein 5 result in dysmorphism of the axial skeleton and in abnormal fracture repair in *short ear* mice.²³ Homozygous mutations of growth-differentiation factor 5 result in dysmorphism of the appendicular skeleton in *brachypodism* mice.²⁴ Fibrodysplasia ossificans progressiva in humans appears to be the only known example of a naturally occurring genetic disorder of osteogenesis that is associated with overexpression of a bone morphogenetic protein.

Our model raises many questions about lymphocytes, inflammation, tissue repair, and osteogenesis. What is the role of lymphocytes in osteogenic induction, bone development, fracture repair, and nongenetic forms of heterotopic osteogenesis? Do lymphocytes normally produce bone morphogenetic proteins? Is the overexpression of bone morphogenetic protein 4 a primary or secondary abnormality? Do the lymphocytes of patients with fibrodysplasia ossificans progressiva transport bone morphogenetic protein 4 to the site of osteogenic induction, or is the expression of bone morphogenetic protein 4 up-regulated locally at the site of osteogenesis?

The cause of lymphocytic activation in patients with fibrodysplasia ossificans progressiva is not known. Lymphoblastoid cell lines immortalized with Epstein-Barr virus can induce the transcription of genes that are not normally expressed in lymphocytes in vivo.³⁹ Therefore, induction of the expression of bone morphogenetic protein 4 in lymphoblastoid cell lines from patients with fibrodysplasia ossificans progressiva could be the result of transformation by the Epstein-Barr virus or other cell-culture conditions. However, bone morphogenetic protein 4 was not overexpressed in identically treated lymphoblastoid cell lines from normal subjects, indicating a clear genetic difference between cells affected by fibrodysplasia ossificans progressiva and normal cells. The possibility of lymphocyte-mediated induction of heterotopic osteogenesis has broad implications for the study of hematopoiesis and skeletal biology.

Supported by grants from the International Fibrodysplasia Ossificans Progressiva Association, the American Heart Association, the Orthopaedic Research and Education Foundation (Johnson and Johnson research award), and the National Institutes of Health (R01-AR-41916).

We are indebted to the following for gifts of cDNA clones: Dr. Darwin Prockop (Thomas Jefferson Medical College, Philadelphia) for collagens type I and II, Dr. Thomas Kadesch (University of Pennsylvania, Philadelphia) for alkaline phosphatase, Dr. Se-Jin Lee (Johns Hopkins University, Baltimore) for growth-differentiation factor 5, Dr. Dwight Towler (Washington University, St. Louis) for MSX-2, and Drs. John Wozney and Vicki Rosen (Genetics Institute, Cambridge, Mass.) for generously providing bone morphogenetic protein and osteocalcin probes and antibody against bone morphogenetic proteins 2 and 4; to Heather Mitchell for establishing lymphoblastoid cell lines; to Drs. Leslie Sutton and Ann-Christine Duhaime for providing surgical specimens to establish primary cell lines; to Dr. Leslie Crofford for providing an established line of fibrodysplasia ossificans progressiva lesional cells; to Michael Haraschak for assistance with tissue culture; to Drs. Elizabeth Rand and Keyong Du for advice on laboratory techniques; to Dr. David Roche for statistical analysis; to Gretchen Worden and the Mütter Museum of the College of Physicians of Philadelphia for archival photographs; to Joanne Deithorn for clinical photography; to Frank Yue for assistance in preparing figures; to Drs. J. Michael Connor, William Gelbart, Victor McKusick, and Marshall Urist for thoughtful and scholarly discussions during the course of this work; and to Jeannie Peeper (president of the International Fibrodysplasia Ossificans Progressiva Association) and all the patients affected with fibrodysplasia ossificans progressiva for their steadfast courage in guiding us on this journey.

REFERENCES

- Cohen RB, Hahn GV, Tabas JA, et al. The natural history of heterotopic ossification in patients who have fibrodysplasia ossificans progressiva: a study of forty-four patients. *J Bone Joint Surg Am* 1993;75:215-9.
- Connor JM, Skirton H, Lunt PW. A three generation family with fibrodysplasia ossificans progressiva. *J Med Genet* 1993;30:687-9.
- Kaplan FS, McCluskey W, Hahn G, Tabas JA, Muenke M, Zasloff MA. Genetic transmission of fibrodysplasia ossificans progressiva: report of a family. *J Bone Joint Surg Am* 1993;75:1214-20.
- Rocke DM, Zasloff M, Peeper J, Cohen RB, Kaplan FS. Age- and joint-specific risk of initial heterotopic ossification in patients who have fibrodysplasia ossificans progressiva. *Clin Orthop* 1994;301:243-8.
- Connor JM, Evans DA. Fibrodysplasia ossificans progressiva: the clinical features and natural history of 34 patients. *J Bone Joint Surg Br* 1982;64:76-83.
- Kaplan FS, Gannon FH, Shafritz AB, Zasloff MA, Shore EM. Acute lymphocytic infiltration in a very early lesion of fibrodysplasia ossificans progressiva. *Calcif Tissue Int* (in press). abstract.
- Kaplan FS, Tabas JA, Gannon FH, Finkel G, Hahn GV, Zasloff MA. The histopathology of fibrodysplasia ossificans progressiva: an endochondral process. *J Bone Joint Surg Am* 1993;75:220-30.
- Lanchoney TF, Cohen RB, Rocke DM, Zasloff MA, Kaplan FS. Permanent heterotopic ossification at the injection site after diphtheria-tetanus-pertussis immunizations in children who have fibrodysplasia ossificans progressiva. *J Pediatr* 1995;126:762-4.
- Shah PB, Zasloff MA, Drummond D, Kaplan FS. Spinal deformity in patients who have fibrodysplasia ossificans progressiva. *J Bone Joint Surg Am* 1994;76:1442-50.
- Kaplan FS, Tabas JA, Zasloff MA. Fibrodysplasia ossificans progressiva: a clue from the fly? *Calcif Tissue Int* 1990;47:117-25.
- Janoff HB, Tabas JA, Shore EM, et al. Mild expression of fibrodysplasia ossificans progressiva: a report of 3 cases. *J Rheumatol* 1995;22:976-8.
- Watt JL, Stephen GS. Lymphocyte culture for chromosome analysis. In: Rooney DE, Czepulkowski BH, eds. *Human cytogenetics: a practical approach*. Oxford, England: IRL Press, 1986:39-55.
- Wozney JM, Rosen V, Celeste AJ, et al. Novel regulators of bone formation: molecular clones and activities. *Science* 1988;242:1528-34.
- Chomczynski P, Sacchi N. Single-step method of RNA isolation by acid guanidinium thiocyanate-phenol-chloroform extraction. *Anal Biochem* 1987;162:156-9.
- Kingsley DM. The TGF-beta superfamily: new members, new receptors, and new genetic tests of function in different organisms. *Genes Dev* 1994;8:133-46.
- Wang ZQ, Grigoriadis AE, Mohle-Steinlein U, Wagner EF. A novel target cell for c-fos-induced oncogenesis: development of chondrogenic tumours in embryonic stem cell chimeras. *EMBO J* 1991;10:2437-50.
- Jabs EW, Muller U, Li X, et al. A mutation in the homeodomain of the human MSX2 gene in a family affected with autosomal dominant craniosynostosis. *Cell* 1993;75:443-50.
- Sambrook J, Fritsch EF, Maniatis T. *Molecular cloning: a laboratory manual*. 2nd ed. Cold Spring Harbor, N.Y.: Cold Spring Harbor Laboratory Press, 1989.
- Urist MR. Bone: formation by autoinduction. *Science* 1965;150:893-9.
- Jones CM, Lyons KM, Hogan BL. Involvement of bone morphogenetic protein-4 (BMP-4) and Vgr-1 in morphogenesis and neurogenesis in the mouse. *Development* 1991;111:531-42.
- Francis PH, Richardson MK, Brickell PM, Tickle C. Bone morphogenetic proteins and a signalling pathway that controls patterning in the developing chick limb. *Development* 1994;120:209-18.
- Vainio S, Karavanova I, Jowett A, Thesleff I. Identification of BMP-4 as a signal mediating secondary induction between epithelial and mesenchymal tissues during early tooth development. *Cell* 1993;75:45-58.
- Kingsley DM, Bland AE, Grubber JM, et al. The mouse short ear skeletal morphogenesis locus is associated with defects in a bone morphogenetic member of the TGF beta superfamily. *Cell* 1992;71:399-410.
- Storm EE, Huynh TV, Copeland NG, Jenkins NA, Kingsley DM, Lee SJ. Limb alterations in brachypodism mice due to mutations in a new member of the TGF beta superfamily. *Nature* 1994;368:639-43.
- Nakase T, Nomura S, Yoshikawa H, et al. Transient and localized expression of bone morphogenetic protein 4 messenger RNA during fracture healing. *J Bone Miner Res* 1994;9:651-9.
- Bostrom MP, Lane JM, Berberian WS, et al. Immunolocalization and expression of bone morphogenetic proteins 2 and 4 in fracture healing. *J Orthop Res* 1995;13:357-67.
- Johansson BM, Wiles MV. Evidence for involvement of activin A and bone morphogenetic protein 4 in mammalian mesoderm and hematopoietic development. *Mol Cell Biol* 1995;15:141-51.
- Winnier G, Blessing M, Labosky PA, Hogan BL. Bone morphogenetic protein-4 is required for mesoderm formation and patterning in the mouse. *Genes Dev* 1995;9:2105-16.
- Padgett RW, Wozney JM, Gelbart WM. Human BMP sequences can confer normal dorsal-ventral patterning in the *Drosophila* embryo. *Proc Natl Acad Sci U S A* 1993;90:2905-9.
- Zecca M, Basler K, Struhl G. Sequential organizing activities of engrailed, hedgehog and decapentaplegic in the *Drosophila* wing. *Development* 1995;121:2265-78.
- Takaoka K, Yoshikawa H, Hashimoto J, Ono K, Matsui M, Nakazato H. Transfilter bone induction by Chinese hamster ovary (CHO) cells transfected by DNA encoding bone morphogenetic protein-4. *Clin Orthop* 1994;300:269-73.
- Shimizu K, Yoshikawa H, Matsui M, Masuhara K, Takaoka K. Periosteal and intratumorous bone formation in athymic nude mice by Chinese hamster ovary tumors expressing murine bone morphogenetic protein-4. *Clin Orthop* 1994;300:274-80.
- Springer TA. Traffic signals for lymphocyte recirculation and leukocyte emigration: the multistep paradigm. *Cell* 1994;76:301-14.
- Buring K. On the origin of cells in heterotopic bone formation. *Clin Orthop* 1975;110:293-307.
- Reddi AH, Cunningham NS. Initiation and promotion of bone differentiation by bone morphogenetic proteins. *J Bone Miner Res* 1993;8:Suppl 2:S499-S502.
- Katagiri T, Yamaguchi A, Komaki M, et al. Bone morphogenetic protein-2 converts the differentiation pathway of C2C12 myoblasts into the osteoblast lineage. *J Cell Biol* 1994;127:1755-66. [Erratum, *J Cell Biol* 1995;128:713.]
- Einhorn TA, Majeska RJ, Rush EB, Levine PM, Horowitz MC. The expression of cytokine activity by fracture callus. *J Bone Miner Res* 1995;10:1272-81.
- Brighton CT, Lorich DG, Kupcha R, Reilly TM, Jones AR, Woodbury RA II. The pericyte as a possible osteoblast progenitor cell. *Clin Orthop* 1992;275:287-99.
- Liebowitz D, Kieff E. Epstein-Barr virus. In: Roizman B, Whitley RJ, Lopez C, eds. *The human herpesviruses*. New York: Raven Press, 1993:107-72.