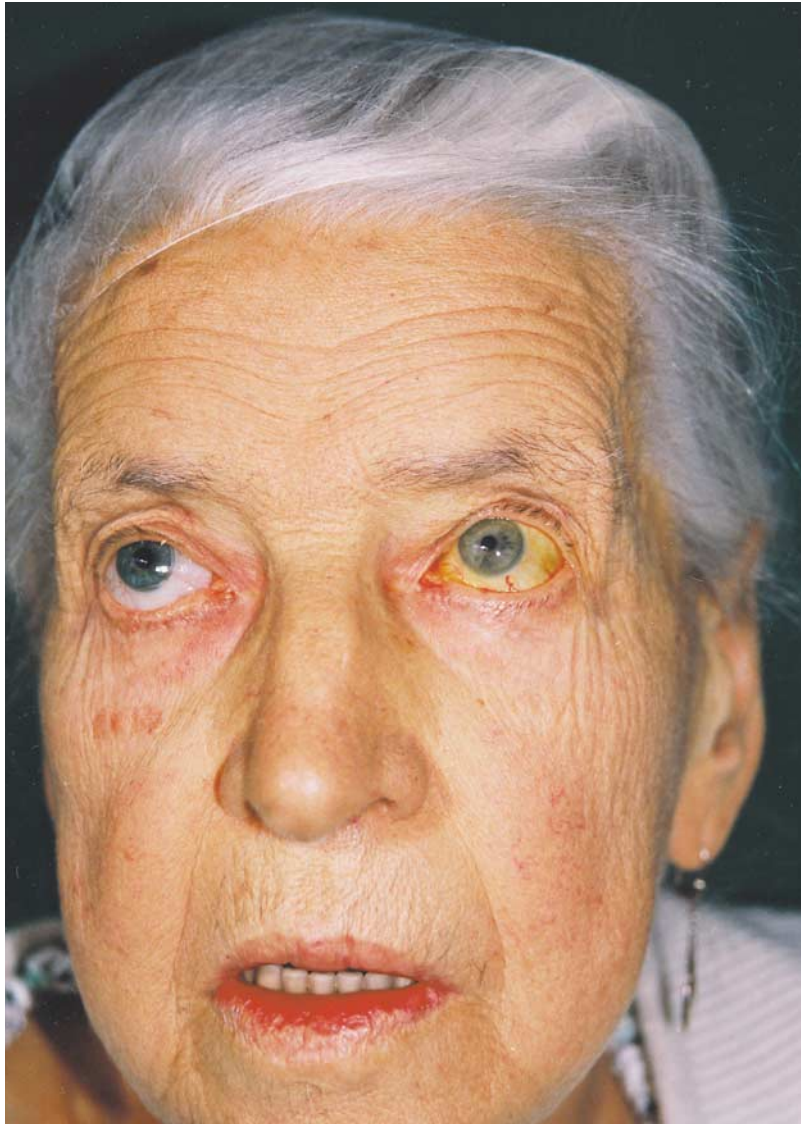




Images in Clinical Medicine



A Medical Mystery

A single diagnosis explains the unusual findings in this 79-year-old woman.

HEINRICH KREMER, M.D.
Kreiskrankenhaus Füssen
D-87629 Füssen, Germany

Editor's note: What is the diagnosis? We invite our readers to offer their opinions by either e-mail (letters@nejm.org) or fax (617-739-9864). We will publish the diagnosis in a forthcoming issue. All replies must be received by April 3, 1997.

©1997, Massachusetts Medical Society.