

## DIAGNOSIS OF PULMONARY EMBOLISM WITH MAGNETIC RESONANCE ANGIOGRAPHY

JAMES F.M. MEANEY, M.D., JOHN G. WEG, M.D., THOMAS L. CHENEVERT, PH.D., DAVID STAFFORD-JOHNSON, M.D., BRIAN H. HAMILTON, M.D., AND MARTIN R. PRINCE, M.D., PH.D.

### ABSTRACT

**Background** Diagnosing pulmonary embolism may be difficult, because there is no reliable noninvasive imaging method. We compared a new noninvasive method, gadolinium-enhanced pulmonary magnetic resonance angiography, with standard pulmonary angiography for diagnosing pulmonary embolism.

**Methods** A total of 30 consecutive patients with suspected pulmonary embolism underwent both standard pulmonary angiography and magnetic resonance angiography during the pulmonary arterial phase at the time of an intravenous bolus of gadolinium. All magnetic resonance images were reviewed for the presence or absence of pulmonary emboli by three independent reviewers who were unaware of the findings on standard angiograms.

**Results** Pulmonary embolism was detected by standard pulmonary angiography in 8 of the 30 patients in whom pulmonary embolism was suspected. All 5 lobar emboli and 16 of 17 segmental emboli identified on standard angiograms were also identified on magnetic resonance images. Two of the three reviewers reported one false positive magnetic resonance angiogram each. As compared with standard pulmonary angiography, the three sets of readings had sensitivities of 100, 87, and 75 percent and specificities of 95, 100, and 95 percent, respectively. The interobserver correlation was good ( $k=0.57$  to  $0.83$  for all vessels,  $0.49$  to  $1.0$  for main and lobar vessels, and  $0.40$  to  $0.81$  for segmental vessels).

**Conclusions** In this preliminary study, gadolinium-enhanced magnetic resonance angiography of the pulmonary arteries, as compared with conventional pulmonary angiography, had high sensitivity and specificity for the diagnosis of pulmonary embolism. This new technique shows promise as a noninvasive method of diagnosing pulmonary embolism without the need for ionizing radiation or iodinated contrast material. (N Engl J Med 1997;336:1422-7.)

©1997, Massachusetts Medical Society.

THE estimated incidence of pulmonary embolism in the United States exceeds 600,000 cases per year.<sup>1</sup> If untreated, pulmonary embolism has an estimated mortality of 30 percent,<sup>2</sup> which is more than 10 times the mortality at one year for treated pulmonary embolism (2.5 percent).<sup>3</sup> As recently as the 1970s, a study reported that only 30 percent of patients with major pulmonary embolism at autopsy had received

the diagnosis before death.<sup>4</sup> The diagnosis had not been made in any of the patients in that study who had pneumonia as well as pulmonary embolism.

The initial diagnostic study in patients with suspected pulmonary embolism is often ventilation-perfusion scanning. In the Prospective Investigation of Pulmonary Embolism Diagnosis (PIOPED) trial, however, only 27 percent of the patients had imaging studies that permitted definitive clinical decision making.<sup>5</sup> In this group, 13 percent of the patients had scans indicating a high probability of pulmonary embolism, and 14 percent had normal or nearly normal scans; an additional 9 percent had a low probability of pulmonary embolism on the basis of both the lung scans and the clinical findings, a combination that satisfactorily rules out pulmonary embolism. In the majority of patients with indeterminate findings on ventilation-perfusion scans, pulmonary angiography is needed to confirm or rule out pulmonary embolism. However, this approach is underused by physicians because it is invasive and expensive.<sup>6-9</sup>

Recent advances in cross-sectional imaging have stimulated interest in the development of a reliable, accurate, and readily available technique for diagnosing pulmonary embolism.<sup>8,9</sup> Dynamic contrast-enhanced spiral or electron-beam computed tomography (CT) has already shown promise as a noninvasive method of diagnosing pulmonary embolism.<sup>10-14</sup> Magnetic resonance imaging (MRI) and magnetic resonance angiography have also been employed. The initial results were poor because of respiratory-motion artifact and poor contrast between flowing blood and an embolus.<sup>15-24</sup> The use of faster magnetic resonance hardware combined with dynamic gadolinium enhancement has made it possible to perform high-resolution angiography during a single suspended breath. This technique has already proved successful in detecting abnormalities in the thoracic and abdominal aorta and visceral arteries.<sup>25,26</sup> In this article, we report our preliminary experience with the use of magnetic resonance angiography for diagnosing pulmonary embolism.

From the Division of Magnetic Resonance Imaging (J.F.M.M., T.L.C., D.S.-J., B.H.H., M.R.P.), Department of Radiology, and the Pulmonary and Critical Care Medicine Division (J.G.W.), Department of Internal Medicine, University of Michigan Hospitals, Ann Arbor. Address reprint requests to Dr. Meaney at the Division of Magnetic Resonance Imaging, Department of Radiology, University of Michigan Hospitals, 1500 E. Medical Center Dr., Ann Arbor, MI 48109.

## METHODS

All consecutive patients referred to our center for pulmonary angiography during an eight-month period were considered for inclusion in the study. Only patients with contraindications to MRI (5 patients), those receiving mechanical ventilation (10), and those who declined to participate in the study (8) were excluded. All studies were carried out in accordance with the guidelines of the institutional review board. Written informed consent was obtained from all patients.

MRI was performed with a commercially available 1.5-T system with a fast gradient-echo capability (Signa-Horizon, GE Medical Systems, Milwaukee). In all cases, the body coil was used for signal transmission and reception. A sagittal fast multiplanar gradient-echo sequence with a repetition time of 140 msec, an echo time of 2.3 msec, and a flip angle of 60 degrees, a 256-by-128 matrix, and 1 signal average was used for the purpose of localization. A coronal three-dimensional spoiled gradient-echo pulse sequence (repetition time, 6.5 msec; echo time, 1.8 msec; flip angle, 40 to 45 degrees; a 256-by-128 matrix; and 1 signal average) was prescribed from the midline slice. The posterior aspect of the imaging slab was placed at or near the posterior border of the vertebral body at the level of the inferior border of the heart. The position of the imaging slab was checked on the slices to the left and right of midline to ensure that the descending pulmonary artery and its proximal posterior branches were included in the imaging region. The slice thickness ranged from 3 to 4 mm, depending on the size of the patient. Thirty-two coronal slices were obtained within the imaging region; the anterior and posterior two slices were not displayed. Thus, the effective imaging volume was 8.4 to 11.2 cm thick. The field of view, which varied according to the patient's size, was typically 32 cm (range, 30 to 36 cm). The imaging time was 27 seconds.

An intravenous catheter was placed in the antecubital vein and connected to tubing (Smart Set, TopSpins, Plymouth, Mich.). The patient was placed feet first within the bore of the magnet, with the arms extended over the head for the dynamic scan, to reduce wraparound artifact. An initial scan was obtained during free breathing to ensure an appropriate imaging volume. Immediately before the administration of gadolinium, the patient was instructed to take several deep breaths over a 30-second period and then suspend breathing in full inspiration during the scan. The gadolinium infusion was begun 7 to 10 seconds before the start of scanning. To ensure that the administration of the bolus of gadolinium was timed correctly, scanning was started manually by the radiologist administering the injection, with the use of controls mounted on the magnet chassis. A dose of 40 to 60 ml of gadopentetate dimeglumine (approximately 0.3 mmol per kilogram of body weight) was injected over a 20-second period, followed by a 20-ml saline flush to ensure maximal enhancement of the pulmonary arteries.

All patients also underwent conventional pulmonary angiography with a 7-French Van Aman catheter introduced into each pulmonary artery through the common femoral or antecubital route under fluoroscopic guidance. A total dose of 40 to 60 ml of iodinated contrast material was injected for each arteriographic run, at a rate of 20 to 30 ml per injection. Multiple injections and magnification views were employed as necessary. The angiographer was unaware of the results of magnetic resonance angiography in cases in which that procedure was performed first. However, the angiographer knew the results of ventilation-perfusion scanning or plain radiography, as well as the side on which the patient reported symptoms, and this information was used to decide which lung to study first.

### Interpretation of Images

All magnetic resonance images were interpreted by three independent radiologists who had no knowledge of the findings on other imaging tests. The images were reviewed in hard copy, as well as on a computer workstation (Advantage Windows, GE Medical Systems), with the use of multiple operator-defined planes.

Each reviewer was skilled in the interpretation of both conventional and magnetic resonance angiograms; reviewer 1 had four years of experience with both modes, and reviewers 2 and 3 each had one year of experience with both modes.

All conventional angiograms were reviewed on the computer screen and in hard copy by two experienced radiologists to reach a consensus. For both conventional angiography and magnetic resonance angiography, the diagnostic criterion for pulmonary embolism was the presence of an intravascular filling defect. Non-visualization of a vessel alone was considered insufficient evidence for the diagnosis.

The result of conventional angiography was accepted as the gold standard. If the reviewers disagreed about the presence or absence of embolism on magnetic resonance angiography, a consensus was reached, and this interpretation was used to determine the overall sensitivity and specificity of magnetic resonance angiography as compared with conventional angiography.

### Statistical Analysis

The sensitivity, specificity, and positive and negative predictive values of magnetic resonance angiography in detecting pulmonary embolism, along with exact two-sided 95 percent confidence intervals for binomial proportions, were calculated for each reviewer's reading and for the final consensus of opinion. Interobserver variation was calculated with the use of the kappa statistic, along with 95 percent confidence intervals.

A vessel was considered to be demonstrated by magnetic resonance angiography if it was seen by at least two of the three reviewers. A vessel was included in the assessment of variation between two reviewers only when it was seen by both reviewers. When there was disagreement about the presence or absence of embolism, a consensus of opinion was used for the assessment of overall sensitivity, specificity, and predictive values.

## RESULTS

Thirty patients (15 men and 15 women) with clinically suspected pulmonary embolism underwent both conventional pulmonary angiography and magnetic resonance angiography. Their mean age was 52 years (range, 22 to 83). Both studies were completed in all 30 patients. All magnetic resonance studies were carried out within 24 hours of conventional angiography. Because of time constraints in the scheduling of magnetic resonance angiography, no attempt was made to randomly assign patients to magnetic resonance or conventional angiography first. (Five patients underwent magnetic resonance angiography first.)

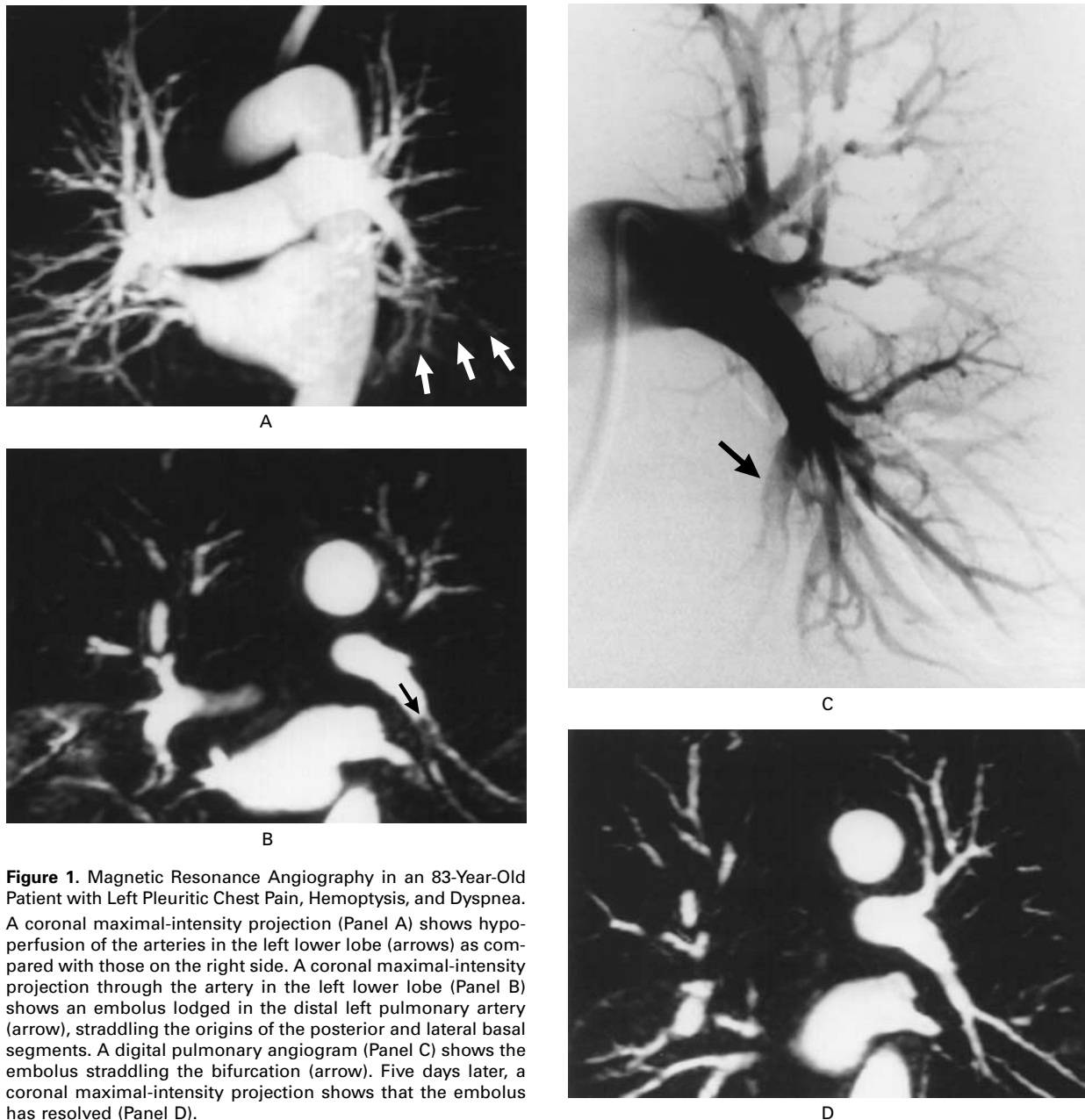
Overall, 669 of 720 vascular segments (93 percent) were adequately identified by magnetic resonance angiography. The remaining 51 segments were inadequately identified because of blurring artifacts, but in each case, there was no evidence of an intravascular filling defect at the vessel's origin that suggested the presence of an embolus. Forty-nine of these nonvisualized segments were in three patients with poor-quality scans in whom the visualization of most segments was deemed nondiagnostic because of breathing motion; two additional segments in the left lower lobe were not identified.

Eight patients (5 men and 3 women) had evidence of pulmonary embolism on conventional angiograms; in the other 22 patients, the conventional

angiograms revealed no abnormalities. Four lobar emboli and 17 segmental emboli were identified in seven of the eight patients, and a solitary lobar embolus was present in the eighth. Overall, 21 of the 22 sites of embolism identified by conventional angiography were also identified by magnetic resonance angiography (Fig. 1); 1 segmental embolus identified by conventional angiography was not identified by magnetic resonance angiography. Four additional sites of embolism (all in segmental vessels) thought to contain emboli on magnetic resonance

angiography were not corroborated by conventional angiography.

In the group of 22 patients with normal findings on conventional pulmonary angiograms, reviewers 1 and 2 each reported one false positive finding on the magnetic resonance angiogram. In one case, the consensus was that the angiogram showed no evidence of embolism; in the other case, the three reviewers agreed on the presence of an embolus within the pulmonary artery in the right upper lobe, despite the normal findings on the conventional angio-



**Figure 1.** Magnetic Resonance Angiography in an 83-Year-Old Patient with Left Pleuritic Chest Pain, Hemoptysis, and Dyspnea. A coronal maximal-intensity projection (Panel A) shows hypoperfusion of the arteries in the left lower lobe (arrows) as compared with those on the right side. A coronal maximal-intensity projection through the artery in the left lower lobe (Panel B) shows an embolus lodged in the distal left pulmonary artery (arrow), straddling the origins of the posterior and lateral basal segments. A digital pulmonary angiogram (Panel C) shows the embolus straddling the bifurcation (arrow). Five days later, a coronal maximal-intensity projection shows that the embolus has resolved (Panel D).

gram. In 3 of the 22 patients with negative studies, the images were of poor quality, and the presence of pulmonary embolism could be neither confirmed nor refuted in 49 of 528 vascular segments (9 percent) in these patients.

The sensitivity, specificity, and positive and negative predictive values of each reviewer's interpretation of the magnetic resonance studies and of the final consensus are shown in Table 1, along with 95 percent confidence intervals. Interobserver variation in reporting is shown in Table 2.

**DISCUSSION**

Because of the limitations of standard lung scanning, the diagnosis of pulmonary embolism cannot be made with certainty in 75 to 80 percent of patients without underlying pulmonary disease and in up to 90 percent of patients with chronic obstructive pulmonary disease.<sup>27</sup> The high mortality rate associated with untreated pulmonary embolism and the substantial incidence of severe and potentially fatal complications of anticoagulation therapy make it essential to diagnose pulmonary embolism accurately so that treatment can be given to the patients in whom the benefits of anticoagulation outweigh its risks.<sup>6,28</sup>

For patients with indeterminate findings on ventilation-perfusion scans and those with discrepancies between the results of ventilation-perfusion studies

and the clinical assessment, further imaging is indicated.<sup>5,8,9</sup> To decrease the use of pulmonary angiography in patients with nondiagnostic lung scans, noninvasive studies of the legs (duplex ultrasonography or impedance plethysmography) are recommended. A positive finding is sufficient grounds for initiating treatment, since the treatment for pulmonary embolism and deep venous thrombosis is the same.<sup>8,9,27</sup> This approach also eliminates the problem of radiation exposure in pregnant women.<sup>29</sup> Pulmonary magnetic resonance angiography is a promising approach for diagnosing pulmonary embolism without incurring the risks associated with the use of iodinated contrast medium, ionizing radiation, and pulmonary arterial catheterization.

Because of its exquisite resolution, conventional pulmonary angiography is the gold standard for the diagnosis of pulmonary embolism, and its accuracy has been validated in many large studies. Although concern has been expressed about the accuracy of digital-subtraction angiography as compared with conventional plain-film angiography because of the lower spatial resolution with digital techniques, most centers use digital subtraction for pulmonary angiography. The spatial resolution of both CT and MRI is lower than that of conventional pulmonary angiography, but despite this limitation, imaging of the pulmonary arteries to the segmental level is possible. The sensitivity and specificity of spiral and electron-

**TABLE 1.** SENSITIVITY, SPECIFICITY, AND POSITIVE AND NEGATIVE PREDICTIVE VALUES OF MAGNETIC RESONANCE ANGIOGRAPHY FOR DETECTING PULMONARY EMBOLISM, ACCORDING TO THE READINGS OF THREE REVIEWERS.

READING	SENSITIVITY	SPECIFICITY	POSITIVE PREDICTIVE VALUE	NEGATIVE PREDICTIVE VALUE
		percent (95 percent confidence interval)		
Overall (consensus)	100	95 (87-100)	87 (74-100)	100
Reviewer 1	100	95 (87-100)	87 (74-100)	100
Reviewer 2	87 (75-100)	100	100	96 (89-100)
Reviewer 3	75 (57-93)	95 (87-100)	83 (68-98)	92 (82-100)

**TABLE 2.** INTEROBSERVER CORRELATION IN THE READINGS OF THE THREE REVIEWERS.\*

REVIEWER	ALL VESSELS	MAIN AND LOBAR VESSELS	SEGMENTAL VESSELS
1 and 2	0.64 (0.47 to 0.81)	0.59 (0.19 to 0.99)	0.75 (0.39 to 1.09)
1 and 3	0.57 (0.37 to 0.77)	0.49 (0.1 to 0.98)	0.40 (-0.28 to 1.07)
2 and 3	0.83 (0.69 to 0.98)	1	0.81 (0.64 to 0.97)

\*Interobserver correlation was determined with the kappa test. Numbers in parentheses are 95 percent confidence intervals.

beam CT have ranged from 63 to 100 percent and 80 to 95 percent, respectively,<sup>9-15</sup> for detecting emboli in the main and segmental pulmonary vessels, as compared with conventional pulmonary angiography. In patients with indeterminate clinical and scintigraphic evidence of pulmonary embolism, however, the sensitivity was reported to be 63 percent when subsegmental vessels were also included.<sup>8</sup> The poorer performance of CT for the detection of emboli in subsegmental vessels is related to limitations of spatial resolution and to the fact that the small subsegmental vessels of both the upper and lower lobes lie outside the imaging range of CT. Although magnetic resonance angiography in our current study had a slightly lower resolution than CT in similar studies, high-definition magnetic resonance images that rival the images obtained with digital-subtraction angiography have recently been reported in a study in which the lungs were imaged one at a time in the sagittal plane. This approach, however, requires two injections of gadolinium.<sup>30</sup>

The clinical significance of small emboli in subsegmental vessels remains uncertain.<sup>8,9,31</sup> Follow-up in the PIOPED study showed that the sequelae of pulmonary embolism did not develop in patients with negative pulmonary angiograms, even though small emboli may have been missed in these patients.<sup>6</sup> This finding supports the belief of some that subsegmental emboli may not be clinically important. Noninvasive imaging with CT and MRI may thus be acceptable despite the possibility of missing small emboli.

In the current study, magnetic resonance angiography proved highly accurate, as compared with pulmonary angiography, in detecting pulmonary embolism. Because of the small number of patients and the even smaller number of positive studies, however, the confidence limits are large and optimism must be tempered by caution. Artifacts from breathing resulted in an inadequate assessment of 7 percent of arterial segments, a higher proportion than that reported for pulmonary angiography in the PIOPED study (4.6 percent)<sup>5</sup> but similar to that reported in a recent study of CT (a 4 percent failure rate with an additional 4 percent of vascular segments inadequately imaged).<sup>11</sup> All failures in our study were due to artifacts from breathing, but recent work at our institution has shown that altering the temporal order in which the magnetic resonance signal is acquired can make breath holding necessary for only the first half of the scan.<sup>32</sup> This change, in combination with shorter imaging times, will make magnetic resonance angiography possible in patients with severe dyspnea.

Although a direct comparison of our study with previous studies is not possible because most earlier studies used consensus between two reviewers rather than analyses by single reviewers unaware of the re-

sults obtained with a gold standard, our overall data on interobserver variation are similar to those reported previously. In the PIOPED study<sup>5</sup> and a more recent study that specifically addressed interobserver variation in the interpretation of angiograms,<sup>33</sup> there was disagreement over the interpretation of 19 to 36 percent of conventional plain-film arteriograms and 4 to 11 percent of digital-subtraction arteriograms. In the latter study, the kappa values were similar to those in our study, and interobserver variation was lower for digital-subtraction angiography than for conventional angiography, because of the ability to manipulate the images on the monitor in order to detect subtle filling defects and the ability to eliminate overlapping structures. Both these features, which are inherent advantages of digital imaging, are shared by MRI and CT. A further advantage of MRI and CT is their superior detection of non-occlusive emboli, which probably contribute to at least some of the interobserver variation in the interpretation of conventional angiograms and possibly also some of the false negative angiograms reported in the literature.<sup>6,33</sup> Because interobserver variation is inherent in the reading of all imaging studies of the pulmonary arteries, we endorse the view that the best results are probably achieved with a consensus of reviewers with experience in both conventional pulmonary angiography and magnetic resonance angiography.<sup>33</sup>

Some of the contraindications to angiography also apply to CT, such as sensitivity to iodinated contrast medium, and should CT studies not prove conclusive, pulmonary angiography may not be acceptable, because of concern about the renal toxicity of iodinated contrast material. MRI is potentially more acceptable as a diagnostic tool, since gadolinium is not nephrotoxic and will not preclude the use of iodinated contrast medium in patients with non-diagnostic magnetic resonance studies.<sup>34</sup>

For a new test to replace ventilation-perfusion scanning or conventional pulmonary angiography for the definitive diagnosis of pulmonary embolism, it must be accurate, readily available, cost effective, and acceptable to both the physician and the patient. In our study, magnetic resonance angiography met most of these criteria. In terms of charges to the patient, magnetic resonance angiography is more expensive than ventilation-perfusion scanning but cheaper than conventional angiography. When one takes into account the high number of indeterminate findings on ventilation-perfusion scans, however, the effective cost of magnetic resonance angiography per diagnosis is considerably lower than the cost of ventilation-perfusion scanning, despite the 10 percent rate of poor-quality scans. Moreover, magnetic resonance angiography is more acceptable to patients (all the patients in our study reported that they preferred it to conventional pulmonary an-

giography), does not require hospitalization, is performed with the use of a non-nephrotoxic contrast medium, and does not involve ionizing radiation.

In conclusion, our preliminary findings suggest that gadolinium-enhanced, three-dimensional magnetic resonance angiography during a single held breath shows promise as a safe, rapid, accurate, and cost-effective imaging technique for the diagnosis of pulmonary embolism. With rapid improvements being made in MRI, it is likely that the resolution of magnetic resonance angiograms will soon rival that of conventional pulmonary angiograms.

Supported in part by a grant from the Whitaker Foundation.

*We are indebted to Michael Keane, David Williams, Kyung Cho, Vickie Marx, Sabira Kazanjian, Mark Wilson, Jennifer Ward, and Frank Londy for contributing helpful suggestions; to Darren Greenwood for statistical advice; and to Bob Combs for photography.*

## REFERENCES

1. Prevention of venous thrombosis and pulmonary embolism. *JAMA* 1986;256:744-9.
2. Weg JG. Pulmonary embolism: diagnosis and treatment. *Appl Cardio-pulm Pathophysiol* 1988;2:23-5.
3. Carson JL, Kelley MA, Duff A, et al. The clinical course of pulmonary embolism. *N Engl J Med* 1992;326:1240-5.
4. Goldhaber SZ, Hennekens CH, Evans DA, Newton EC, Godleski JJ. Factors associated with correct antemortem diagnosis of major pulmonary embolism. *Am J Med* 1982;73:822-6.
5. The PIOPED Investigators. Value of the ventilation/perfusion scan in acute pulmonary embolism: results of the Prospective Investigation of Pulmonary Embolism Diagnosis (PIOPED). *JAMA* 1990;263:2753-9.
6. Stein PD, Athanasoulis C, Alavi A, et al. Complications and validity of pulmonary angiography in acute pulmonary embolism. *Circulation* 1992;85:462-8.
7. Hudson ER, Smith TP, McDermott VG, et al. Pulmonary angiography performed with iopamidol: complications in 1,434 patients. *Radiology* 1996;198:61-5.
8. Goodman LR, Lipchik RJ. Diagnosis of acute pulmonary embolism: time for a new approach. *Radiology* 1996;199:25-7.
9. Gefter WB, Hatabu H, Holland GA, Gupta KB, Henschke CI, Palevsky HI. Pulmonary thromboembolism: recent developments in diagnosis with CT and MR imaging. *Radiology* 1995;197:561-74.
10. Verschakelen JA, Vanwijck E, Bogaert J, Baert AL. Detection of unsuspected central pulmonary embolism with conventional contrast-enhanced CT. *Radiology* 1993;188:847-50.
11. Remy-Jardin M, Remy J, Deschildre F, et al. Diagnosis of pulmonary embolism with spiral CT: comparison with pulmonary angiography and scintigraphy. *Radiology* 1996;200:699-706.
12. Teigen CL, Maus TP, Sheedy PF II, Johnson CM, Stanson AW, Welch TJ. Pulmonary embolism: diagnosis with electron-beam CT. *Radiology* 1993;188:839-45.
13. Teigen CL, Maus TP, Sheedy PF, et al. Pulmonary embolism: diagnosis with contrast-enhanced electron-beam CT and comparison with pulmonary angiography. *Radiology* 1995;194:313-9.
14. Goodman LR, Curtin JJ, Mewissen MW, et al. Detection of pulmonary embolism in patients with unresolved clinical and scintigraphic diagnosis: helical CT versus angiography. *AJR Am J Roentgenol* 1995;164:1369-74.
15. Woodard PK, Sostman HD, MacFall JR, et al. Detection of pulmonary embolism: comparison of contrast-enhanced spiral CT and time-of-flight MR techniques. *J Thorac Imaging* 1995;10:59-72.
16. Hatabu H, Gefter WB, Kressel HY, Axel L, Lenkinski RE. Pulmonary vasculature: high-resolution MR imaging. *Radiology* 1989;171:391-5.
17. Hatabu H, Gefter WB, Axel L, et al. MR imaging with spatial modulation of magnetization in the evaluation of chronic central pulmonary thromboemboli. *Radiology* 1994;190:791-6.
18. Foo TKF, MacFall JR, Hayes CE, Sostman HD, Slayman BE. Pulmonary vasculature: single breath-hold MR imaging with phased-array coils. *Radiology* 1992;183:473-7.
19. MacFall JR, Sostman HD, Foo TK, et al. Thick-section, single breath-hold magnetic resonance pulmonary angiography. *Invest Radiol* 1992;27:318-22.
20. Foo TK, MacFall JR, Sostman HD, Hayes CE. Single-breath-hold venous or arterial flow-suppressed pulmonary vascular MR imaging with phased-array coils. *J Magn Reson Imaging* 1993;3:611-6.
21. Wielopolski PA, Haacke EM, Adler LP. Evaluation of the pulmonary vasculature with three-dimensional magnetic resonance imaging techniques. *MAGMA* 1993;1:231-4.
22. Wielopolski PA. Pulmonary arteriography. *Magn Reson Imaging Clin North Am* 1993;1:295-313.
23. Grist TM, Sostman HD, MacFall JR, et al. Pulmonary angiography with MR imaging: preliminary clinical experience. *Radiology* 1993;189:523-30.
24. Rubin GD, Herfkens RJ, Pelc NJ, et al. Single breath-hold pulmonary magnetic resonance angiography: optimization and comparison of three imaging strategies. *Invest Radiol* 1994;29:766-92.
25. Prince MR, Yucel EK, Kaufman JA, Harrison DC, Geller SC. Dynamic gadolinium-enhanced three-dimensional abdominal MR arteriography. *J Magn Reson Imaging* 1993;3:877-81.
26. Prince MR, Narasimham DL, Stanley JC, et al. Breath-hold gadolinium-enhanced MR arteriography of the abdominal aorta and its major branches. *Radiology* 1995;197:785-92.
27. Lesser BA, Leeper KV Jr, Stein PD, et al. The diagnosis of acute pulmonary embolism in patients with chronic obstructive pulmonary disease. *Chest* 1992;102:17-22.
28. Weg JG. Pulmonary embolism and deep vein thrombosis. In: Kippe JM, Irwin RS, Alpert JS, Fink MP, eds. *Intensive care medicine*. 3rd ed. Boston: Little, Brown, 1995:660-79.
29. Togli MR, Weg JG. Venous thromboembolism during pregnancy. *N Engl J Med* 1996;335:108-14.
30. Wielopolski PA, Oudkerk M, Hicks SG, Berghout A. Breath-hold 3D MR pulmonary angiography after contrast material administration in patients with pulmonary embolism: correlation with conventional pulmonary angiography. *Radiology* 1996;201:Suppl:202. abstract.
31. Oser RF, Zuckerman DA, Gutierrez FR, Brink JA. Anatomic distribution of pulmonary emboli at pulmonary angiography: implications for cross-sectional imaging. *Radiology* 1996;199:31-5.
32. Maki J, Prince MR, Chenevert TL. Optimizing breath holding strategies for 3D MRI. *J Magn Reson Imaging* (in press).
33. van Beek EJR, Bakker AJ, Reekers JA. Pulmonary embolism: interobserver agreement in the interpretation of conventional angiographic and DSA images in patients with nondiagnostic lung scan results. *Radiology* 1996;198:721-4.
34. Prince MR, Arnoldus C, Frisoli JK. Nephrotoxicity of high-dose gadolinium compared with iodinated contrast. *J Magn Reson Imaging* 1996;6:162-6.