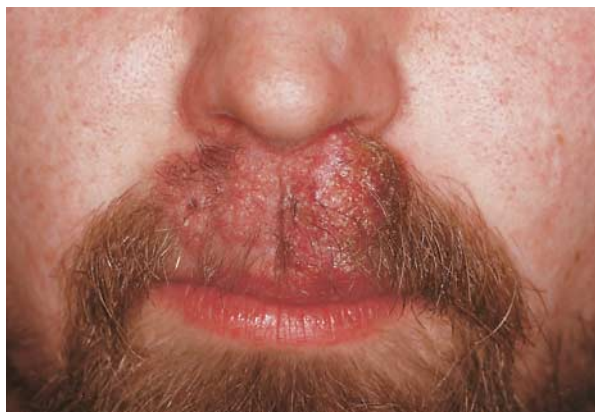
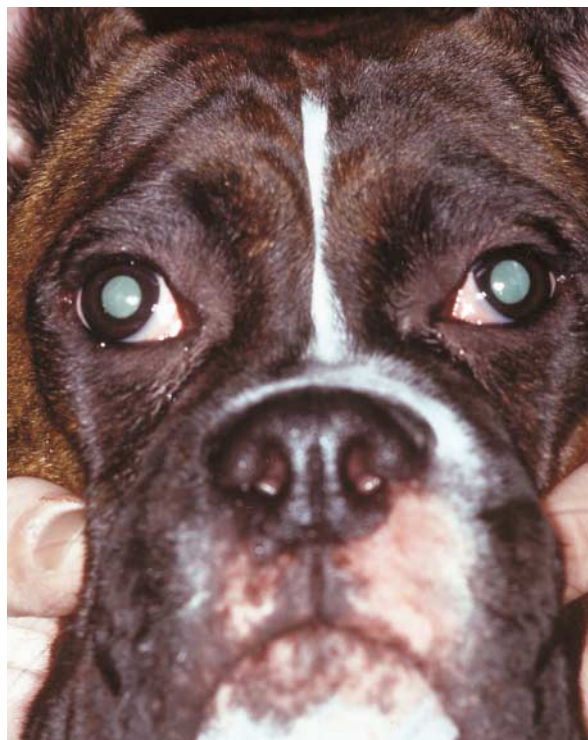


 Images in Clinical Medicine



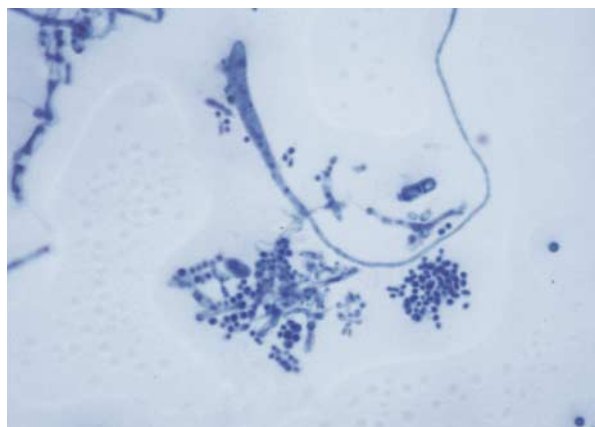
A



B



C



D

Tinea Barbae: Man and Beast

A 23-year-old brick mason presented with a three-month history of a boggy, crusted nodule on his upper lip (Panel A). Areas of alopecia and pustules were noted within the lesion. The man owned a bull mastiff, which also had alopecia on his snout that had begun approximately five months previously (Panel B). The patient recalled being nipped on the upper lip by his dog about five months earlier. Culture of the man's lesion revealed a buff-colored powdery colony, with growth within 7 to 10 days (Panel C). Microscopical examination revealed spiral, coiled hyphae and microconidia that were arranged in grape-like clusters (Panel D; lactophenol cotton blue, $\times 40$) and were identified as *Trichophyton mentagrophytes* variant *mentagrophytes*. The patient was treated with 200 mg of ketoconazole orally twice a day for one month, and his dog was referred to a veterinarian for treatment of its dermatophyte infection. Neither the patient nor the dog returned for follow-up.

DEE ANNA GLASER, M.D.
 ANNE T. RIORDAN, M.D.
 St. Louis University
 St. Louis, MO 63104