

Brief Report

DELAYED CEREBELLAR DISEASE AND DEATH AFTER ACCIDENTAL EXPOSURE TO DIMETHYLMERCURY

DAVID W. NIERENBERG, M.D.,

RICHARD E. NORDGREN, M.D., MORRIS B. CHANG, M.D.,

RICHARD W. SIEGLER, M.D., MICHAEL B. BLAYNEY, PH.D.,

FRED HOCHBERG, M.D., TAFT Y. TORIBARA, PH.D.,

ELSA CERNICHIARI, M.S., AND THOMAS CLARKSON, PH.D.

INGESTION of fish or grain contaminated with methylmercury resulted in epidemics of severe neurotoxicity and death in Japan in the 1950s and 1960s¹ and in Iraq in 1972.² The World Health Organization and other organizations have warned of the dangers of methylmercury compounds to the environment and to scientific researchers.^{1,3-6} Dimethylmercury may be even more dangerous than methylmercury compounds. The physical properties of dimethylmercury permit transdermal absorption, and the volatility of this liquid permits toxic exposure through inhalation. Since dimethylmercury is lethal at a dose of approximately 400 mg of mercury (equivalent to a few drops, or about 5 mg per kilogram of body weight), it is supertoxic according to the rating in a classic toxicology textbook.⁷

We report a case of accidental dimethylmercury poisoning in a chemist whose research focused on the biologic toxicity of heavy metals.^{8,9} Records suggest that she handled dimethylmercury on only one day, while wearing latex gloves and working under a ventilated hood designed to prevent exposure to chemical fumes. She had delayed but ultimately fatal neurotoxic effects similar to those caused by methylmercury compounds. This case illustrates the potent toxicity of dimethylmercury and the need for additional safety precautions if it is to be used in any scientific research.¹⁰⁻¹²

From the Section of Clinical Pharmacology, Departments of Medicine and Pharmacology/Toxicology (D.W.N.), the Section of Neurology, Departments of Medicine and Pediatrics (R.E.N., M.B.C.), and the Department of Pathology (R.W.S.), Dartmouth Medical School; and the Office of Environmental Health and Safety, Dartmouth College (M.B.B.) — both in Hanover, N.H.; the Neurology Service, Massachusetts General Hospital, Boston (F.H.); and the Department of Environmental Medicine, University of Rochester School of Medicine, Rochester, N.Y. (T.Y.T., E.C., T.C.). Address reprint requests to Dr. Nierenberg at the Dartmouth-Hitchcock Medical Center, Hinman Box 7506, Lebanon, NH 03756.

©1998, Massachusetts Medical Society.

CASE REPORT

A 48-year-old chemistry professor was admitted to Dartmouth-Hitchcock Medical Center, in Lebanon, New Hampshire, on January 20, 1997, with a five-day history of progressive deterioration in balance, gait, and speech. She had lost 6.8 kg (15 lb) over a period of two months and had experienced several brief episodes of nausea, diarrhea, and abdominal discomfort.

The patient recalled that in August 1996, while transferring liquid dimethylmercury from a container to a capillary tube, she spilled several drops from the tip of the pipette onto the dorsum of her gloved hand. (A subsequent review of her dated laboratory notebooks, a history provided by a coworker, and examination of the dated materials used in the experiment later pinpointed the date as August 14, 1996.) She reported that she had cleaned up the spill and then removed her protective gloves.

The patient was thin but appeared healthy and was appropriately concerned about her neurologic problems. The examination showed moderate upper-extremity dysmetria, dystaxic handwriting, a widely based gait, and mild "scanning speech." The results of routine laboratory tests were normal. The results of computed tomography (CT) and magnetic resonance imaging (MRI) of the head were normal except for the incidental finding of a probable meningioma, 1 cm in diameter. The cerebrospinal fluid was clear, with a protein concentration of 42 mg per deciliter and no cells.

Because of the possibility of methylmercury neurotoxicity, blood and urine samples were sent for urgent measurement of mercury content. In view of the long interval between the date of exposure to mercury and the onset of neurologic symptoms (154 days) as well as the rapid progression of symptoms, other causes of acute cerebellar dysfunction were considered.

In the ensuing days, the patient noted tingling in her fingers, brief flashes of light in both eyes, a soft background noise in both ears, and progressive difficulty with speech, walking, hearing, and vision (constricted visual fields). A preliminary laboratory report indicated that the whole-blood mercury concentration was more than 1000 μg per liter. Chelation therapy with oral succimer (10 mg per kilogram orally every eight hours) was begun on day 168 after exposure. The next day, the following laboratory values were reported: whole-blood mercury, 4000 μg per liter (normal range, 1 to 8; toxic level, >200); urinary mercury, 234 μg per liter (normal range, 1 to 5; toxic level, >50).^{13,14}

The patient's neurologic deterioration continued; neuropsychiatric testing revealed marked deficits in all areas. Chelation therapy was initially successful, with an increase in urinary excretion of mercury from 257 μg per 24 hours (before chelation therapy) to 39,800 μg per 24 hours. Vitamin E was added to the regimen as a potentially protective antioxidant.

The patient was transferred to Massachusetts General Hospital in Boston. Vitamin E and succimer were continued. An exchange transfusion reduced the mean whole-blood mercury concentration from 2230 μg per liter before the procedure to 1630 μg per liter 2 hours afterward, but reequilibration resulted in a concentration of 2070 μg per liter 16 hours later. The mercury content of bile was 30 to 99 μg per liter. Repeated CT and MRI scans of the head remained normal, with no evidence of occipital or cerebellar damage. Audiometry revealed mild-to-moderate sensorineural hearing loss. Neuro-ophthalmologic testing revealed moderately constricted concentric fields, with no evidence of papilledema. On February 6, 22 days after the first neurologic symptoms developed (and 176 days after exposure), the patient became unresponsive to all visual, verbal, and light-touch stimuli.

The patient was transferred back to Dartmouth-Hitchcock Medical Center, and aggressive general support was continued, along with 21-day cycles of chelation therapy with succimer (10 mg per kilogram given orally every 12 hours). The decline in blood mercury concentrations over time is shown in Figure 1. Mercury half-lives (with chelation therapy) were 29 to 37 days. Urinary excretion of mercury declined rapidly despite ongoing chelation therapy (Fig. 1). Analysis of a long strand of hair revealed that after a brief lag, the mercury content rose rapidly to

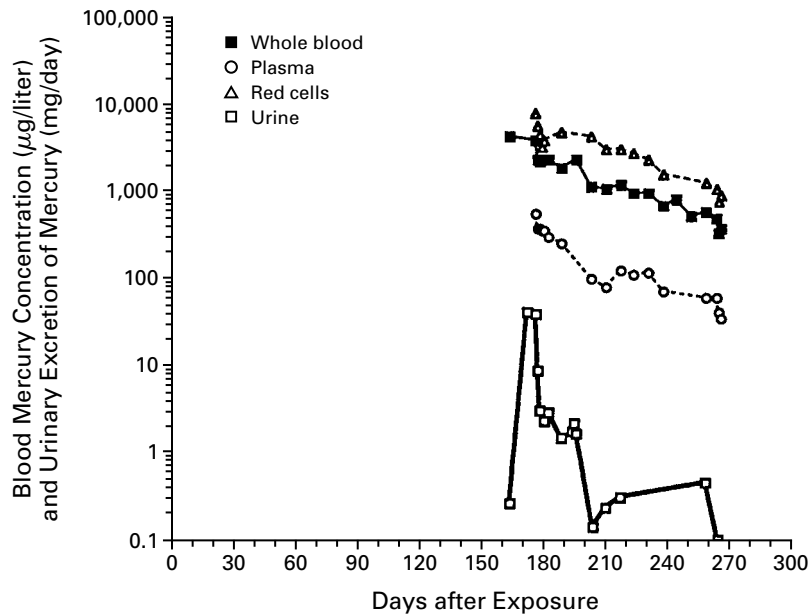


Figure 1. Blood Concentrations and Urinary Excretion of Mercury over Time in a 48-Year-Old Woman. The values are plotted on a logarithmic scale. The elimination half-lives of mercury were 29 days in plasma, 33 days in whole blood, and 37 days in red cells.

almost 1100 ng per milligram (normal level, <0.26 ng per milligram; potentially toxic level, >50 ng per milligram)¹⁵ and then declined slowly, with a half-life of 74.6 days (Fig. 2).

The patient's neurologic status was marked by periods of spontaneous eye opening, but without awareness of or any response to visual, sound, or light-touch stimuli. The Babinski sign was equivocal, and decerebrate and decorticate posturing were absent. Painful stimuli resulted in limb withdrawal. Corneal and pupillary reflexes were sluggish but present. Spontaneous yawning, moaning, and limb movements occurred, with periods of agitation and crying, requiring large doses of chlorpromazine and lorazepam. Her condition appeared to resemble a persistent vegetative state with spontaneous episodes of agitation and crying.

Testing of family members, laboratory coworkers, and laboratory surfaces failed to reveal any unsuspected mercury spills or other cases of toxic blood or urinary mercury concentrations.

We could find only three previously reported cases of poisoning with dimethylmercury, all of which were fatal.^{3,16} Equally bleak outcomes have been reported in patients with severe methylmercury toxicity.² In view of the dismal prognosis and after more than three months of aggressive treatment and support, the patient's advance directives were followed, and she died peacefully on June 8, 1997, 298 days after exposure.

At autopsy, dehydration and bronchopneumonia were noted. The cortex of the cerebral hemispheres was diffusely thinned, to 3 mm. The visual cortex around the calcarine fissure was grossly gliotic, as was the superior surface of the superior temporal gyri. The cerebellum showed diffuse atrophy of both vermal and hemispheric folia (Fig. 3). Microscopical study showed extensive neuronal loss and gliosis bilaterally within the primary visual and auditory cortices, with milder loss of neurons and gliosis in the motor and sensory cortices. There was widespread loss of cerebellar granular-cell neurons, Purkinje cells, and basket-cell neurons, with evidence of loss of parallel fibers in the molecular layer. Bergmann gliosis was well developed and widespread.

An extremely high mercury content was found in the frontal

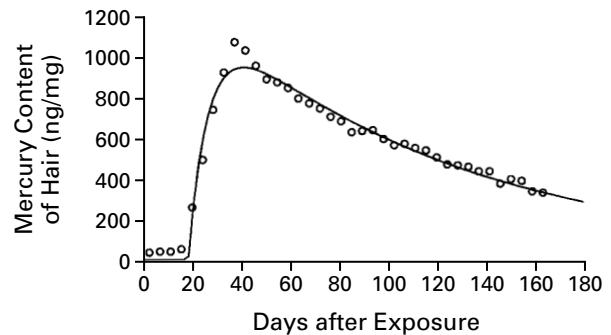


Figure 2. Mercury Content of a Sample of Hair.

The sample was obtained on January 31, 1997 (day 170 after exposure). The mercury content of a single strand of hair was measured every 2 mm from the scalp end. The apparent rate of hair growth was 78 mm over a period of 170 days, or 1.38 cm per month. On the basis of this rate, there was a lag phase of 17.4 days, followed by the distribution of mercury from blood to hair during a period of 21.8 days (half-life, 5.6 days) and a subsequent decline in the mercury content of hair (and presumably blood) during a period of 130.7 days (half-life, 74.6 days). These two first-order processes are represented by the curve, with the circles indicating the observed data.

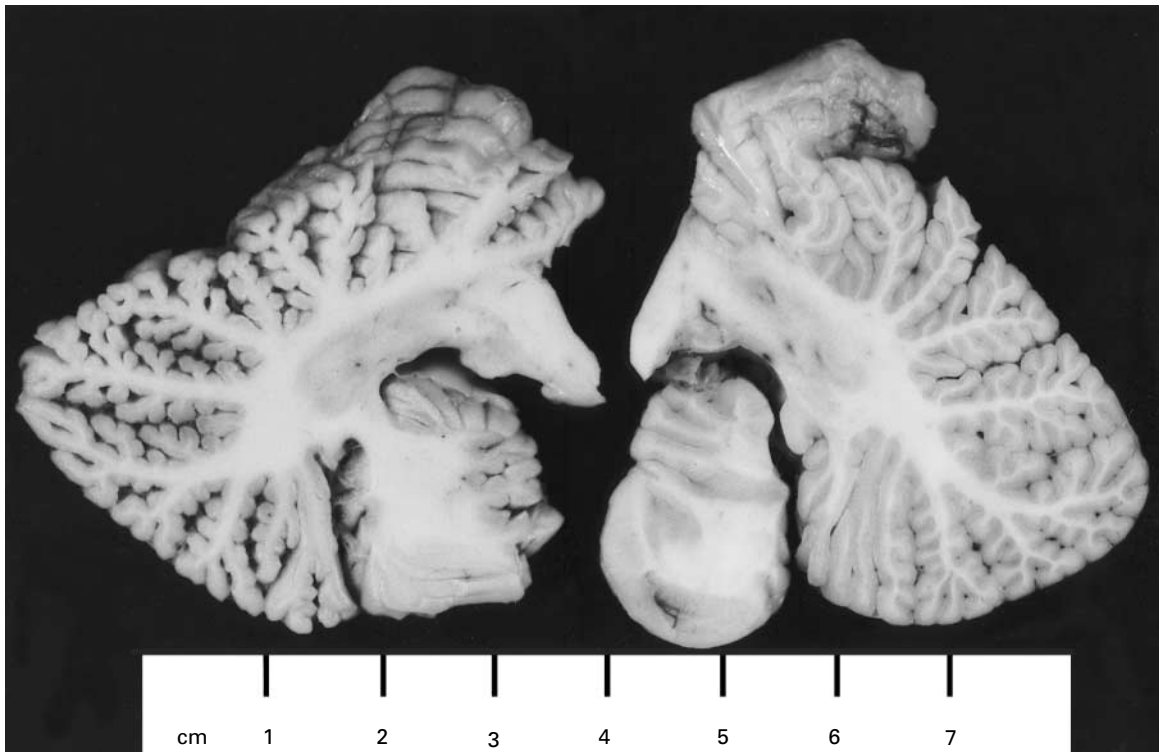


Figure 3. Cerebellar Hemispheric Sections from the Patient (Left) and from a Woman of Approximately the Same Age without Neurologic Disease (Right).

Widespread shrinkage of the folia and diminution of the cerebellar cortical thickness are evident in the section from the patient.

lobe and visual cortex (average value, $3.1 \mu\text{g}$ per gram, or 3100 ppb), liver ($20.1 \mu\text{g}$ per gram), and kidney cortex ($34.8 \mu\text{g}$ per gram). The mercury content of the brain was approximately six times that of whole blood at the time of death and was much higher than levels in brain samples obtained at autopsy from patients not previously exposed to mercury (2 to 50 ppb).¹⁷

METHODS

The total mercury content of blood, urine, and bile was determined with the use of atomic absorption analysis.¹⁸ The mercury content of hair was measured by x-ray fluorescence every 2 mm along one entire strand of hair.¹⁹ The mercury content of formalin-preserved brain tissue obtained at autopsy was determined by preparing tissue homogenates with the use of hot alkaline digestion, as previously described.^{17,20} The first whole-blood sample obtained from the patient was processed by SmithKline Beecham Clinical Laboratories (Waltham, Mass.).

Elimination half-lives of mercury in plasma, red cells, and whole blood were determined by analysis with the use of Win-NonLin software (SCI, Louisville, Ky.). The same software was used to calculate the first-order distribution of mercury from blood to hair and the first-order decline in the mercury content of hair, with the assumption of an initial lag time.

Glove testing for permeation by dimethylmercury was performed in standard fashion by Inchscape Testing Services (Cortland, N.Y.).

DISCUSSION

In 1865, two laboratory assistants died several weeks after helping to synthesize dimethylmercury

for the first time.³ Nearly 100 years later, another laboratory worker died after synthesizing the compound. He had a rapid downhill course very similar to that of our patient, and chelation therapy with penicillamine was without clinical benefit.¹⁶

Several conclusions can be drawn from these case reports, the epidemics of poisoning with methylmercury compounds, and the information obtained from this case. First, even an accidental, brief exposure to dimethylmercury can be fatal. The data in Figure 2 are consistent with a lag phase after exposure, rapid conversion of dimethylmercury to methylmercury, rapid movement of methylmercury from blood to hair (half-life of uptake into hair, 5.6 days), and a first-order decline in the mercury content of hair (half-life, 74.6 days) that paralleled the decline in blood mercury. Qualitatively similar observations have been made in mice exposed to dimethylmercury through intravenous or inhalational routes.²¹

In our patient, the rapid, monophasic, first-order increase in the mercury content of hair is consistent with either one or several episodes of exposure to dimethylmercury beginning on or about August 14, 1996, and is consistent with the evidence (reports from coworkers and information from labeled vials and laboratory notebooks) that a single accidental

exposure to dimethylmercury occurred on August 14. Our findings are also consistent with earlier reports that methylmercury has a half-life of about 78 days in humans, that excretion of methylmercury is first-order in mice and humans, and that the toxicity of dimethylmercury is apparently mediated by methylmercury metabolites in mice.²¹

Second, disposable latex gloves do not provide adequate protection against dimethylmercury. Permeation tests showed that several types of disposable latex or polyvinyl chloride gloves (typically, about 0.1 mm thick) had high and maximal rates of permeation by dimethylmercury within 15 seconds. In contrast, gloves designed to be chemically resistant are made of materials specifically selected for their ability to withstand chemical permeation. For example, under standard test conditions, no permeation of a flexible, plastic-laminate glove (SilverShield) was observed after four hours of exposure to dimethylmercury. This thin glove can be worn under a heavy-duty outer glove (e.g., one made of neoprene) for increased protection. Our patient's accidental exposure may have resulted from both transdermal absorption of the liquid (given the lack of protection provided by disposable latex gloves) and inhalation of vapors (even though the work was conducted under a fume hood).

Since research in animals suggests that dimethylmercury is either promptly exhaled or converted to methylmercury metabolites that can bind to tissues,²¹ we can estimate the body burden of mercury in our patient.⁴ At the time of the diagnosis, the blood concentration was 4000 μg per liter, which represents about 16.8 mg of mercury in the blood (total volume of blood, about 4.2 liters) and about 336 mg in the entire body (since only about 5 percent of an absorbed dose of methylmercury remains in blood). Since dimethylmercury has a density of 3.2 g per milliliter, this amount of mercury is contained in only 0.11 ml of liquid dimethylmercury. Since the elimination half-life in hair was about 75 days and the interval between exposure and blood studies was just over 150 days, the original body burden of mercury may have been four times the amount at diagnosis, or about 1344 mg, requiring absorption of 0.44 ml of liquid dimethylmercury (perhaps more if a portion of the absorbed dose was promptly excreted through exhalation, as reported in mice exposed to dimethylmercury²¹).

Third, the interval between exposure and the onset of neurologic symptoms (154 days) is a longer latent period than that reported after oral ingestion of the more common methylmercury compounds.² However, there have been reports of latent periods lasting for years after the administration of methylmercury in monkeys.²² The reason for this latency is unclear.

Fourth, the brain damage caused by dimethylmer-

cury in our patient was similar to that reported previously in patients who died from exposure to either dimethylmercury or methylmercury.^{16,20} In all these cases, the damage involved the cerebral cortex, especially the calcarine area, with necrosis of neurons and gliosis. Extensive neuronal death and loss in the cerebellum was another characteristic finding. In previous cases, most of the mercury found in the brain at autopsy was in an inorganic form, which is probably not responsive to chelation therapy.²⁰ Research in animals indicates that dimethylmercury does not enter the brain until it has been metabolized after several days to methylmercury, a metabolite capable of forming covalent bonds with cellular proteins.²¹

Fifth, the role of chelation therapy in such cases remains unclear.²³ Succimer has been recommended as the treatment of first choice for methylmercury poisoning,²⁴ and other chelators used in Iraq failed to show a significant clinical benefit.²⁵ Dimercaprol may actually be contraindicated in cases of poisoning with organic mercury compounds.² One study of chelation therapy in mice exposed to methylmercury suggested that treatment with succimer, begun a few days after exposure, is most effective in reducing brain and blood mercury levels.²⁶ Our experience confirms previous reports that treatment begun long after exposure to methylmercury, and after serious neurotoxicity has developed, is of little or no clinical benefit (even if urinary excretion and the elimination half-life are improved).

Contact with various forms of mercury is possible in occupational or other settings. The American Conference of Governmental Industrial Hygienists has established "threshold limit values" and "biological exposure indices" for a variety of chemicals, including mercury.²⁷ Material Safety Data Sheets may be inadequate sources of information on how to handle a particular chemical safely.²⁸ For example, the Material Safety Data Sheet for dimethylmercury states, "Wear appropriate chemical-resistant gloves,"²⁹ which is simply too vague to provide adequate guidance for glove selection. Increased awareness of personal protection on the part of scientists and more detailed and specific safety information from manufacturers could make research with toxic chemicals safer.

Dimethylmercury appears to be so dangerous that scientists should use less toxic mercury compounds whenever possible. Since dimethylmercury is a "super-toxic" chemical that can quickly permeate common latex gloves and form a toxic vapor after a spill, its synthesis, transportation, and use by scientists should be kept to a minimum, and it should be handled only with extreme caution and with the use of rigorous protective measures.^{11,12}

Supported by a grant (ES 01247) from the National Institute of Environmental Health Sciences.

We are indebted to the health care workers at both hospitals who provided excellent care of the patient; to Dr. Lionel Lewis, for the kinetic analyses; to Dr. William Hickey, for his direction of the neuropathological work; to Drs. Leslie A. Shinobu and Dean Le, for their clinical care of the patient and useful comments; to Dr. John S. Winn, for his help in establishing the chronology of the exposure and providing information about the chemical and physical characteristics of mercury; and to the staff of the laboratory of the Department of Environmental Medicine, University of Rochester School of Medicine and Dentistry, especially Margaret Langdon, for analyses of the mercury content of blood, urine, hair, and tissue samples.

Before she lapsed into a vegetative state, the patient requested that her case be presented to the general medical community, to scientists working with mercury, and to toxicologists, in the hope of improving the recognition, treatment, and prevention of future cases of mercury poisoning.

REFERENCES

1. Junghans RP. A review of the toxicity of methylmercury compounds with application to occupational exposures associated with laboratory uses. *Environ Res* 1983;31:1-31.
2. Bakir F, Damluji SF, Amin-Zaki L, et al. Methylmercury poisoning in Iraq. *Science* 1973;181:230-41.
3. Dewhurst F. Edward Franklin and COSHH. *Chem Britain* 1989;25:702-5.
4. Methylmercury. No. 101 of Environmental health criteria. Geneva: World Health Organization, 1990.
5. Weiss B. Perspectives on methylmercury as a global health hazard. *Neurotoxicology* 1995;16:577-8.
6. Mercury — environmental aspects. No. 86 of Environmental health criteria. Geneva: World Health Organization, 1989.
7. Gosselin RE, Smith RP, Hodge HC, eds. *Clinical toxicology of commercial products*. 5th ed. Baltimore: Williams & Wilkins, 1984.
8. O'Neill H. A deadly drop: the death of Karen Wetterhahn. *Valley News*. September 14, 1997:A1, A7.
9. Goldberg C. Colleagues vow to learn from chemist's death. *New York Times*. October 3, 1997:A10.
10. Toribara TY, Clarkson TW, Nierenberg DW. Chemical safety: more on working with dimethylmercury. *Chem Eng News* 1997;75:6.
11. Blayney MB, Winn JS, Nierenberg DW. Chemical safety: handling dimethylmercury. *Chem Eng News* 1997;75:7.
12. Zacks R. Looking for alternatives: a scientist's death raises questions about a toxic mercury compound. *Sci Am* 1997;277:20.
13. Toxicological profile for mercury (update). Atlanta: Agency for Toxic Substances and Disease Registry, 1993:166-7. (Publication no. TP-93/10.)
14. Clarkson TW. The toxicology of mercury. *Crit Rev Clin Lab Sci* 1997;34:369-403.
15. Lipfert FW. Estimating exposure to methyl mercury: effects of uncertainties. *Water Air Soil Pollut* 1997;97:119-45.
16. Pazderova J, Jirasek A, Mraz M, Pechan J. Post-mortem findings and clinical signs of dimethyl mercury poisoning in man. *Int Arch Arbeitsmed* 1974;33:323-8.
17. Lapham LW, Cernichiari E, Cox C, et al. An analysis of autopsy brain tissue from infants prenatally exposed to methylmercury. *Neurotoxicology* 1995;16:689-704.
18. Cernichiari E, Toribara TY, Liang L, et al. The biological monitoring of mercury in the Seychelles study. *Neurotoxicology* 1995;16:613-28.
19. Toribara TY, Jackson DA, French WR, Thompson AC, Jaklevic JM. Nondestructive X-ray fluorescence spectrometry for determination of trace elements along a single strand of hair. *Anal Chem* 1982;54:1844-9.
20. Davis LE, Kornfeld M, Mooney HS, et al. Methylmercury poisoning: long-term clinical, radiological, toxicological, and pathological studies of an affected family. *Ann Neurol* 1994;35:680-8.
21. Östland K. Studies on the metabolism of methyl mercury and dimethyl mercury in mice. *Acta Pharmacol Toxicol* 1969;27:Suppl 1.
22. Rice DC. Evidence for delayed neurotoxicity produced by methylmercury. *Neurotoxicology* 1996;17:583-96.
23. Kosnett MJ. Unanswered questions in metal chelation. *Clin Toxicol* 1992;30:529-47.
24. Aaseth J, Jacobsen D, Andersen O, Wickstrom E. Treatment of mercury and lead poisonings with dimercaptosuccinic acid and sodium dimercaptopropanesulfonate. *Analyst* 1995;120:853-4.
25. Clarkson TW, Magos L, Cox C, et al. Tests of efficacy of antidotes for removal of methylmercury in human poisoning during the Iraq outbreak. *J Pharmacol Exp Ther* 1981;218:74-83.
26. Aaseth J, Fricheim EAH. Treatment of methyl mercury poisoning in mice with 2,3-dimercaptosuccinic acid and other complexing thiols. *Acta Pharmacol Toxicol (Copenh)* 1978;42:248-52.
27. Threshold limit values and biological exposure indices. Cincinnati: American Conference of Governmental Industrial Hygienists, 1997.
28. Kolp P, Sattler B, Blayney M, Sherwood T. Comprehensibility of Material Safety Data Sheets. *Am J Ind Med* 1993;23:135-41.
29. Material Safety Data Sheet for dimethylmercury. St. Louis: Sigma Chemical, February 1997–April 1997. (Product no. 328081.)

ELECTRONIC ACCESS TO THE JOURNAL'S CUMULATIVE INDEX

At the *Journal's* site on the World Wide Web (<http://www.nejm.org>) you can search an index of all articles published since January 1990. You can search by author, subject, title, type of article, or date. The results will include the citations for the articles plus links to the abstracts of articles published since 1993. Single articles and past issues of the *Journal* can also be ordered for a fee through the Internet (<http://www.nejm.org/customer/>).
