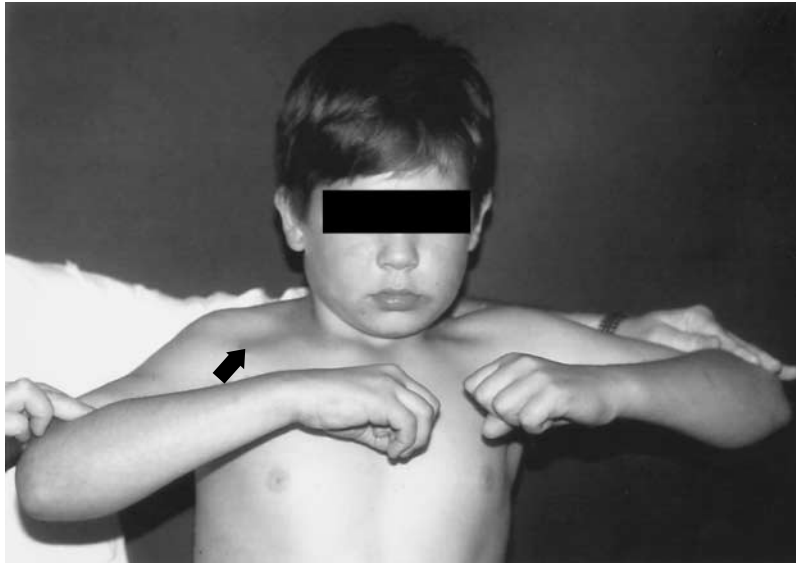
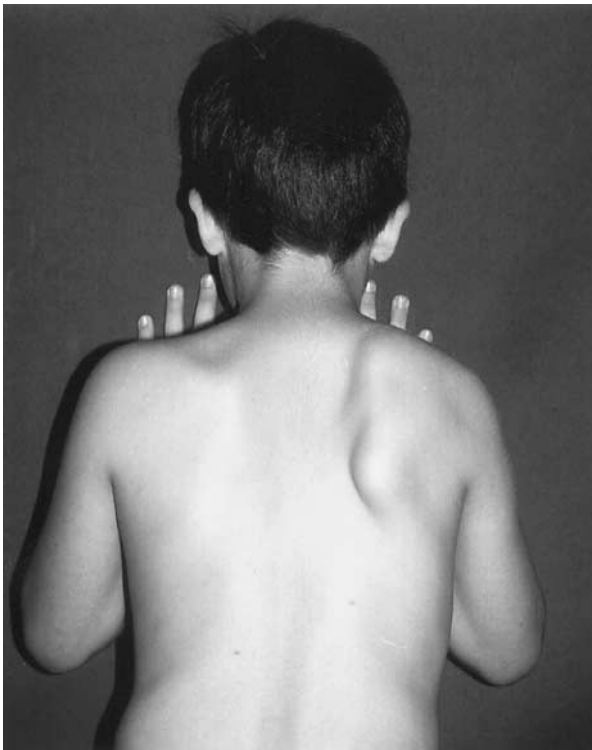




Images in Clinical Medicine



A



B

*Postinfectious
Brachial Neuritis*

A nine-year-old boy presented with a two-day history of extreme pain in his right shoulder girdle after an upper respiratory tract infection that was accompanied by fever (temperature, 39.5°C). Physical examination revealed paresthesia of the lateral aspect of the arm, atrophy (arrow in Panel A), weakness of the deltoid muscle (4/5) during abduction of the shoulder, and weakness of the serratus anterior muscle, with scapular winging (Panel B). Symptomatic therapy with acetaminophen was administered. The patient recovered uneventfully within four months.

COBI LIDOR, M.D., PH.D.
ELLA GOICHMAN, M.D.
*Kupat-Holim Meuchedet
Herzeliya 46782, Israel*

©1998, Massachusetts Medical Society.