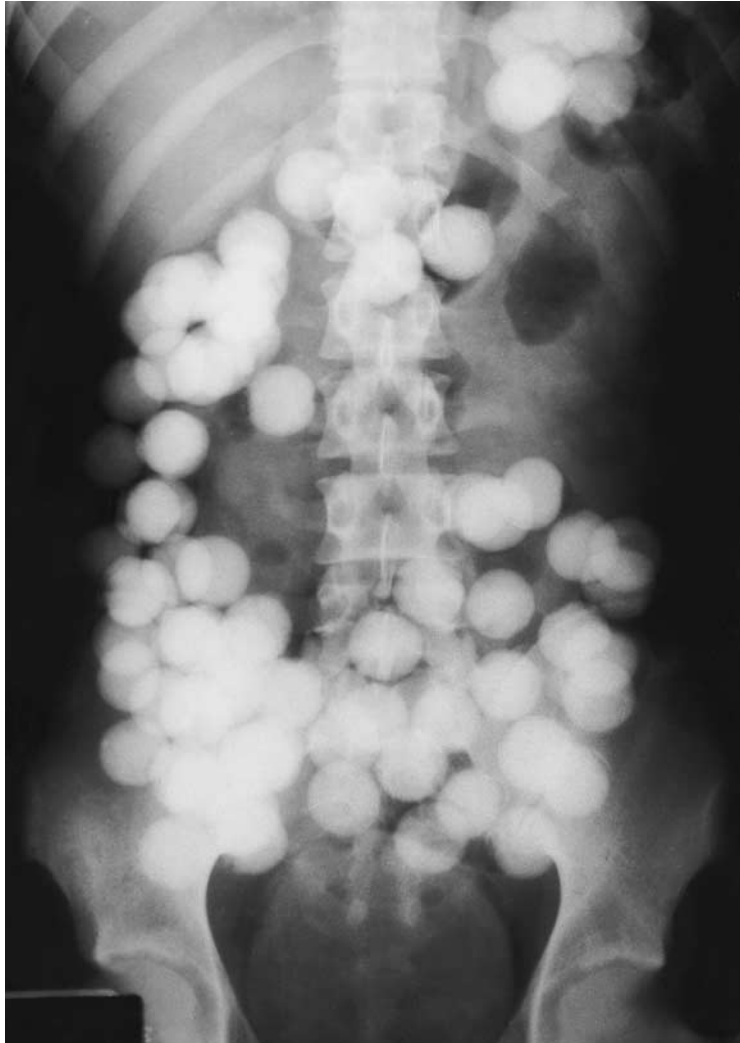




Images in Clinical Medicine



A Medical Mystery

A 20-year-old college student, newly arrived in the United States, was evaluated for severe abdominal pain. What is the diagnosis?

MICHAEL S. MAHONEY, M.D.
MARC KAHN, M.D.

*Tulane University School of Medicine
New Orleans, LA 70112-2699*

Editor's note: We invite our readers to offer their opinions by e-mail (mystery@nejm.org) or fax (617-739-9864). We will not be able to acknowledge the receipt of responses. We will publish the diagnosis in the Correspondence section of the October 29, 1998, issue. All replies must be received by September 24, 1998.

©1998, Massachusetts Medical Society.