

CYCLIC ADMINISTRATION OF PAMIDRONATE IN CHILDREN WITH SEVERE OSTEOGENESIS IMPERFECTA

FRANCIS H. GLORIEUX, M.D., PH.D., NICHOLAS J. BISHOP, M.D., HORACIO PLOTKIN, M.D., GILLES CHABOT, M.D., GINETTE LANOUE, R.N., AND ROSE TRAVERS, R.T.

ABSTRACT

Background Severe osteogenesis imperfecta is a disorder characterized by osteopenia, frequent fractures, progressive deformity, loss of mobility, and chronic bone pain. There is no effective therapy for the disorder. We assessed the effects of treatment with a bisphosphonate on bone resorption.

Methods In an uncontrolled observational study involving 30 children who were 3 to 16 years old and had severe osteogenesis imperfecta, we administered pamidronate intravenously (mean [\pm SD] dose, 6.8 ± 1.1 mg per kilogram of body weight per year) at 4-to-6-month intervals for 1.3 to 5.0 years. Clinical status, biochemical characteristics reflecting bone turnover, the bone mineral density of the lumbar spine, and radiologic changes were assessed regularly during treatment.

Results Administration of pamidronate resulted in sustained reductions in serum alkaline phosphatase concentrations and in the urinary excretion of calcium and type I collagen N-telopeptide. There was a mean annualized increase of 41.9 ± 29.0 percent in bone mineral density, and the deviation of bone mineral density from normal, as indicated by the z score, improved from -5.3 ± 1.2 to -3.4 ± 1.5 . The cortical width of the metacarpals increased by 27.0 ± 20.2 percent per year. The increases in the size of the vertebral bodies suggested that new bone had formed. The mean incidence of radiologically confirmed fractures decreased by 1.7 per year ($P < 0.001$). Treatment with pamidronate did not alter the rate of fracture healing, the growth rate, or the appearance of the growth plates. Mobility and ambulation improved in 16 children and remained unchanged in the other 14. All the children reported substantial relief of chronic pain and fatigue.

Conclusions In children with severe osteogenesis imperfecta, cyclic administration of intravenous pamidronate improved clinical outcomes, reduced bone resorption, and increased bone density. (N Engl J Med 1998;339:947-52.)

©1998, Massachusetts Medical Society.

OSTEOGENESIS IMPERFECTA, often referred to as "brittle-bone disease," is a heritable disorder characterized in most affected persons by either a reduction in the production of normal type I collagen or the synthesis of abnormal collagen as a result of mutations in the type I collagen genes.¹ The clinical severity of its expression varies widely. In its milder form (type I), fractures before puberty occur occasionally, de-

formity is minimal, and stature is normal. In its most severe form (type II), fractures in utero lead to pulmonary insufficiency, causing perinatal death. In type III osteogenesis imperfecta, a high frequency of fractures causes severe deformities and short stature, whereas in type IV, deformities and dwarfism are present but are less severe.² In most children with type III and many with type IV osteogenesis imperfecta, the disorder is progressive, with increasing deformity of the limbs and spine, dependence on others for help in walking, and chronic pain. A variety of agents (including anabolic steroids, sodium fluoride, magnesium oxide, and calcitonin) have been used in attempts to increase bone mass and to reduce the risk of fracture, but none have resulted in sustained improvement.³⁻⁶

The bisphosphonate compounds are potent inhibitors of bone resorption, and they have been reported to have beneficial effects in children with osteogenesis imperfecta.⁷⁻¹⁰ We have reported the results of histomorphometric studies of bone suggesting that this disorder is associated with an increase in osteoclastic activity and a reduction in the formation of new bone.¹¹ Our study was designed to assess the effects of bisphosphonate treatment in children with severe osteogenesis imperfecta.

METHODS**Subjects**

Between October 1992 and December 1997, we administered pamidronate to 30 children, 3 to 16 years old, who had severe osteogenesis imperfecta (Table 1). All had severe osteopenia, and 27 were small for their age (below the third percentile for height). All but five had moderate-to-severe restrictions in ambulation. The study was approved by the ethics review board of our institution, and parents or legal guardians gave written informed consent.

In nine children the osteogenesis imperfecta was classified as type III, and in nine others as type IV. In 12 children the disorder could not be classified; these children had features similar to those of type IV osteogenesis imperfecta but with various combinations of severe long-bone deformity resulting from fractures after birth, vertebral collapse, and changes in the long-bone metaphyses. Four of these 12 patients had the clinical features of the newly described type V osteogenesis imperfecta.¹²

Treatment

Pamidronate disodium (Aredia, Ciba-Geigy, Dorval, Que., Canada) was diluted in 250 to 500 ml of isotonic saline and ad-

From the Genetics Unit, Shriners Hospital for Children (F.H.G., N.J.B., H.P., G.C., G.L., R.T.), and the Departments of Surgery and Pediatrics (F.H.G., N.J.B.), McGill University, Montreal. Address reprint requests to Dr. Glorieux at the Genetics Unit, Shriners Hospital for Children, 1529 Cedar Ave., Montreal, QC H3G 1A6, Canada.

TABLE 1. CHARACTERISTICS OF 30 CHILDREN WITH OSTEOGENESIS IMPERFECTA BEFORE PAMIDRONATE TREATMENT AND THEIR TREATMENT SCHEDULES.*

PATIENTS	No.	AGE	HEIGHT	SERUM	URINARY TYPE I	PAMIDRONATE TREATMENT		
				ALKALINE PHOSPHATASE†	COLLAGEN N-TELOPEPTIDE†	DURATION	DOSE	CYCLES‡
		yr	cm	U/liter	nmol of BCE/ nmol of creatinine	days	mg/kg/yr	no.
Girls								
Prepubertal	7	5±2	91.2±20.2	290±95	900±153	727±151	6.6±0.9	5.4±1.0
Pubertal	7	13±2	102.3±26.5	297±101	691±231	747±297	6.8±0.7	5.6±1.4
Boys								
Prepubertal	8	6±2	94.8±7.5	416±228	1403±1037	796±419	6.3±0.6	5.7±2.5
Pubertal	8	14±2	117.2±22.7	357±153	801±338	784±232	7.5±1.6	6.1±1.7
All children	30	9±4	101.7±21.8	340±158	961±618	765±282	6.8±1.1	5.7±1.7

*Plus-minus values are means ±SD.

†The normal value for serum alkaline phosphatase is <300 U per liter; for urinary excretion of type I collagen N-telopeptide the normal value is 957±432 nmol of bone collagen equivalents (BCE) per nanomole of creatinine before puberty and 714±374 thereafter.

‡One cycle was defined as one three-day infusion period.

ministered by slow intravenous infusion over a four-hour period on each of three successive days. The dose, based on the dose given to adults for the treatment of Paget's disease of bone,^{13,14} was 1.5 or 3.0 mg per kilogram of body weight per infusion cycle. Half the children received the lower dose during the first year of treatment, after which their regimen was shifted to the higher dose. The other half received only the higher dose. In one child, because of a slow initial response to therapy, the dose was increased after one year to 3.75 mg per kilogram per cycle. Overall, the children received a mean (±SD) of 6.8±1.1 mg per kilogram per year and 4 to 12 cycles of treatment. The mean duration of treatment was 765 days (range, 490 to 1813 [approximately 1.3 to 5.0 years]) (Table 1). Initially, the interval between cycles was six months. However, monthly measurements of the serum alkaline phosphatase concentration and the urinary excretion of calcium revealed an increase in both after four months, and therefore the interval between cycles was shortened to four months. The patients' calcium intake was regularly evaluated and was maintained at 800 to 1000 mg per day through diet and supplementation. Their vitamin D intake was at least 400 IU per day.

Measurements

Clinical evaluation, including assessment of anthropometric variables and pubertal development, occupational-therapy evaluation, and bone densitometric measurements, were performed at each admission for pamidronate infusion. Accurate records for use in evaluating the growth rate before treatment were available for 21 of the 30 children (10 prepubertal and 11 pubertal).

The subjects fasted overnight. Blood and urine (from the second morning voiding) were obtained before each infusion of pamidronate, and blood alone immediately thereafter. Serum and urine concentrations of calcium, phosphate, and creatinine and the serum concentration of alkaline phosphatase were measured by colorimetric methods (Monarch, Instrumentation Laboratory, Lexington, Mass.). The urinary excretion of the cross-linked N-telopeptide of type I collagen, a marker of bone resorption, was measured by enzyme-linked immunosorbent assay (Osteomark, Ostex, Seattle).

X-ray films of the skull, upper and lower limbs, and spine (anteroposterior and lateral views) were obtained at 6-to-12-month

intervals. Films were examined on an ongoing basis by pediatric radiologists unaware of the treatment status of the children. Changes in the bone mineral density of the lumbar spine, both in terms of absolute values and in terms of age-corrected values (z scores), were measured by dual-energy x-ray absorptiometry (QDR 2000W, Hologic, Waltham, Mass.). The coronal area of the first four lumbar vertebrae, automatically measured by the software used for absorptiometric analysis, was taken as an index of vertebral-body size. The coefficient of variation for the bone mineral density of the lumbar spine was 1 percent on repeated measures in healthy children. On posteroanterior radiographs of the hand taken at a uniform 40-in. (102-cm) tube-to-film distance, the cortical width of the metacarpals (defined as the distance between the external cortical surfaces minus the width of the medullary cavity) was measured with vernier calipers at the midpoint of the second left metacarpal. These measurements were made immediately before treatment and after one or two years of treatment. On the same radiographs, the bone age was determined according to the method of Greulich and Pyle.¹⁵ All available radiographs from the two years before treatment and those obtained during treatment were assessed for evidence of fractures.

Occupational therapists experienced in the care of children with osteogenesis imperfecta evaluated the subjects' mobility and ambulation using a five-point scale, as follows: 0 (bed- or wheelchair-bound), 1 (able to walk with aids, but not functionally mobile), 2 (able to walk in the household, with or without aids), 3 (able to walk short distances, with or without aids), and 4 (able to walk independently).¹⁶

Statistical Analysis

The children were treated for various lengths of time, and therefore the magnitude of the effect of treatment on most outcome measures was extrapolated to an annualized percent change from base line for each child. In general, the longer-term data were negatively skewed in distribution, and therefore the data were log-transformed to obtain a near-normal distribution. Analyses were performed with two-sided paired t-tests or the Mann-Whitney rank-sum test, as appropriate. All the analyses were performed with DataDesk software (version 5.0.1; Data Description, Ithaca, N.Y.).

RESULTS

Biochemical Changes

Before treatment, all 30 children had normal serum concentrations of calcium and phosphate. After each infusion cycle, there was a transient (two-to-four-week) decrease in serum calcium (mean decrease, 12 ± 7 percent) and serum phosphate (23 ± 18 percent). Over a three-to-four-month period, there were more sustained decreases in the serum concentration of alkaline phosphatase (14 ± 18 percent), the urinary excretion of calcium (66 ± 49 percent), and the urinary excretion of the *N*-telopeptide of type I collagen (43 ± 31 percent). Throughout the treatment period, there were steady decreases in serum levels of alkaline phosphatase (13 ± 8 percent per year, $P < 0.001$) and urinary excretion of *N*-telopeptide of type I collagen (26 ± 17 percent per year, $P < 0.001$).

Changes in Bone Density

All the children had low bone mineral density in the lumbar spine, with z scores ranging from -3.3 to -7.8 . During treatment, the mean bone mineral density increased markedly, by 41.9 ± 29.0 percent per year, and the mean z score improved from -5.3 ± 1.2 to -3.4 ± 1.5 ($P < 0.001$); the z scores of three patients reached the normal range. There were no significant differences between boys and girls or between prepubertal children and children undergoing puberty (Table 2). The changes in bone mineral density over time for the nine children treated for two or more years are shown in Figure 1. Concurrently with the change in bone mineral density, the mean coronal area of the first through fourth lumbar vertebrae increased markedly, from 21.8 ± 7.8 to 29.2 ± 8.8 cm² (Table 2).

Radiologic Changes

On successive radiologic examinations of the thoracic and lumbar regions of the spine, no new vertebral crush fractures were seen. Instead, an increase in vertebral height was noted over time (Fig. 2), corroborating the increase in vertebral coronal area (Table 2). Characteristic dense lines appeared under the growth plates, particularly in the bones around the knees and in the distal forearms, as well as in the vertebrae and along the iliac crests (Fig. 3). The regular spaces between these lines corresponded to the intervals between treatment cycles, demonstrating the continued growth of bone during therapy. Systematic surveys of the epiphyses showed no evidence of widening or rachitis. In all the children, the bone ages corresponded to the chronologic age.

An increase in the thickness of the cortex was often seen in the diaphyses of the long bones. In 26 of the 29 patients for whom previous x-ray films were available, the metacarpal cortical width increased by an average of 27.0 ± 20.2 percent per year (Table 2). This compares well with the gain of 8 to 9 percent per year in healthy children from 3 to 16 years of age.¹⁷

Effects on Growth

Before treatment, 10 prepubertal children grew an average of 4.4 ± 2.7 cm per year. During treatment, their growth rate was maintained, at 5.7 ± 2.2 cm per year ($P = 0.16$). In 11 children undergoing puberty, the pretreatment growth rate was 2.2 ± 1.7 cm per year and increased slightly, to 4.9 ± 3.4 cm per year, during treatment ($P = 0.11$). In healthy children the prepubertal growth rate averages 6 cm per year and increases to 9 to 10 cm per year during puberty.¹⁸

TABLE 2. CHANGES OBSERVED WITH PAMIDRONATE TREATMENT IN 30 CHILDREN WITH OSTEOGENESIS IMPERFECTA.*

PATIENTS	NO.	BONE MINERAL DENSITY		Z SCORE		VERTEBRAL AREA		METACARPAL CORTICAL WIDTH		FRACTURE RATE	
		ANNUALIZED % CHANGE		BEFORE TREATMENT	AFTER TREATMENT†	BEFORE TREATMENT	AFTER TREATMENT†	BEFORE TREATMENT	AFTER TREATMENT	BEFORE TREATMENT‡	DURING TREATMENT
		BEFORE TREATMENT	AFTER TREATMENT								
		g/cm ²				cm ²		mm		no./yr	
Girls											
Prepubertal	7	0.242±0.1	33.5±16.0	-5.2±1.4	-3.1±1.7	17.7±6.5	24.2±7.7	1.6±0.6	25.8±23.8	3.3±1.3	0.6±0.4
Pubertal	7	0.276±0.1	69.2±43.2	-5.5±1.6	-3.1±1.7	23.1±7.6	30.5±9.3	2.4±0.5	19.8±15.0	0.8±1.0	0.4±0.5
Boys											
Prepubertal	8	0.227±0.1	35.8±24.7	-5.1±1.1	-3.3±1.3	20.4±4.5	27.9±3.7	2.1±0.3	21.1±12.6	1.8±1.5	0.7±0.8
Pubertal	8	0.316±0.1	31.3±7.4	-5.5±0.9	-3.9±1.5	26.2±10.6	34.4±11.5	2.2±0.8	39.4±23.6	3.4±3.1	0.5±0.5
All children	30	0.266±0.1	41.9±29.0	-5.3±1.2	-3.4±1.5	21.8±7.8	29.2±8.8	2.1±0.6	27.0±20.2	2.3±2.2	0.6±0.5

*The bone mineral density was defined as the density of the first through fourth lumbar vertebrae, the bone mineral density z score as the difference between individual bone-mineral-density values and the mean value for age-matched healthy children, and the vertebral area as the coronal area of the first through fourth lumbar vertebrae. Significant changes occurred in all five variables with treatment, according to paired t-tests ($P < 0.001$).

†After-treatment values reflect measurements made at the last assessment.

‡The fracture rate before treatment was defined as the number of fractures per year during the two years before treatment.

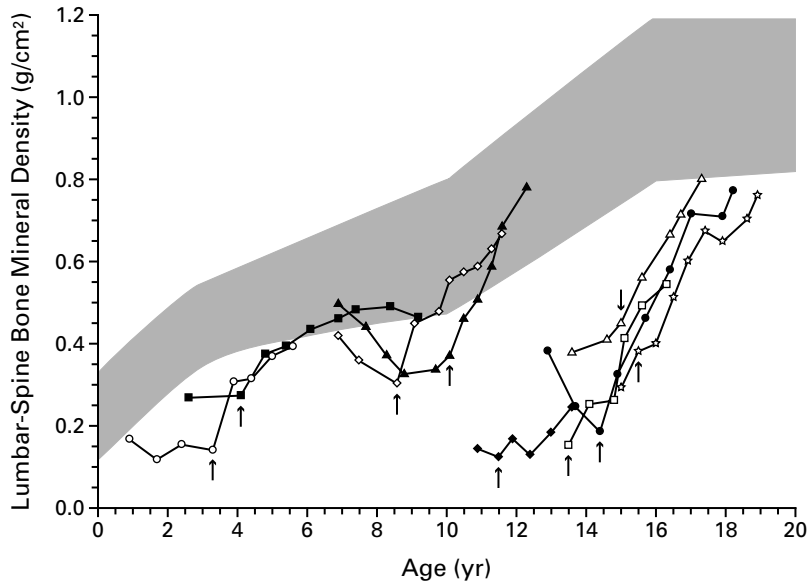


Figure 1. Changes in the Bone Mineral Density of the First through Fourth Lumbar Vertebrae in Nine Children with Osteogenesis Imperfecta Who Were Treated with Cyclic Administration of Intravenous Pamidronate for Two or More Years.

The shaded area represents the normal range (mean \pm 2 SD) for age-matched healthy children (data from Hologic). The arrows indicate the initiation of treatment. Each symbol represents one measurement.

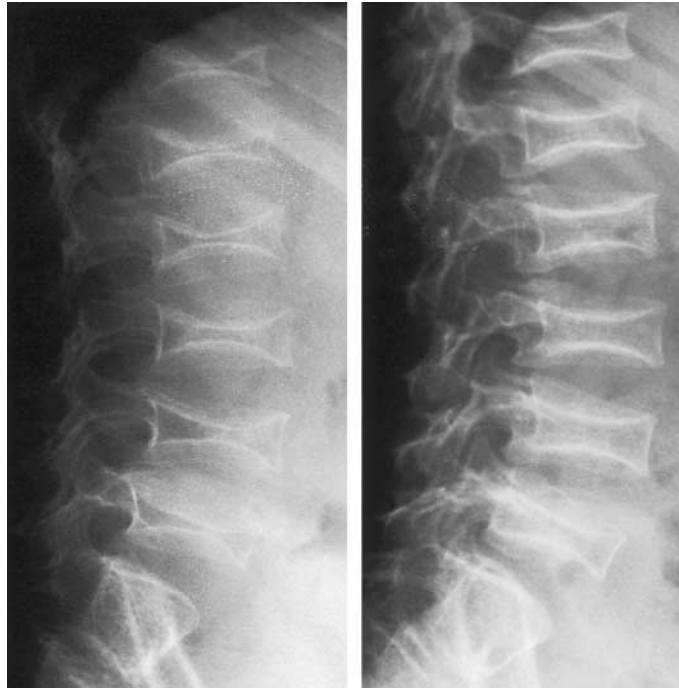


Figure 2. Lateral Radiographs of the Lumbar Spine of a Six-Year-Old Boy with Osteogenesis Imperfecta before (Left-Hand Panel) and after (Right-Hand Panel) 18 Months of Treatment with Pamidronate.

Increases in the heights of individual vertebrae are evident. The bone mineral density before treatment was 0.205 g per square centimeter, and after 18 months it was 0.371 g per square centimeter.

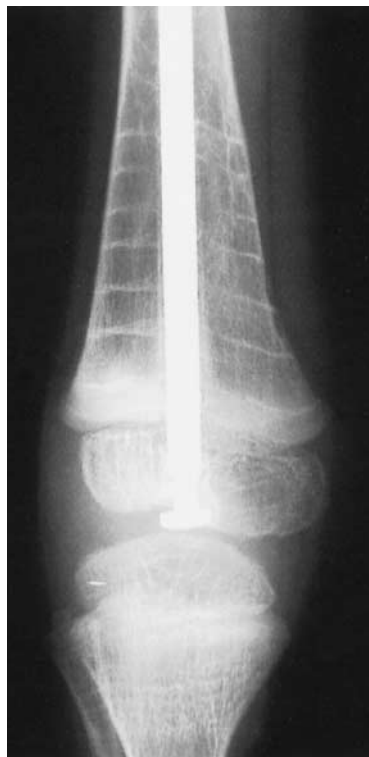

Figure 3. Anteroposterior Radiograph Showing Sclerotic Bands in the Metaphysis of the Distal Femur in an Eight-Year-Old Boy with Osteogenesis Imperfecta.

This child received seven cycles of treatment. The seven evenly spaced bands demonstrate that growth continued steadily during therapy.

Clinical Outcome and Side Effects

The earliest response to treatment was a marked reduction in chronic bone pain one to six weeks after the initiation of therapy, with only an occasional recurrence of pain in the days preceding a treatment cycle. Ambulation was assessed according to the children's degree of independence and mobility.¹⁶ Before therapy, 5 children were fully functional (grade 4), whereas 16 were confined to a bed or a wheelchair (grade 0 or 1). Ambulation scores improved in 16 children: 6 gained one grade, 5 gained two, and 1 gained three, and 4 children progressed from being wheelchair-bound (grade 0 or 1) to walking independently (grade 4). In the other 14 children, no change in grade was noticed.

The incidence of fractures decreased from 2.3 ± 2.2 per year before treatment to 0.6 ± 0.5 per year during treatment. Nine children had no fractures during treatment, as compared with three children in the two years before treatment. Fracture healing was not obviously delayed and there was no instance of fracture nonunion during treatment.

In 26 children, body temperature increased on

the second day of the first infusion cycle, a change accompanied by back and limb pain in some. This "acute-phase reaction"¹⁹ was controlled with standard doses of acetaminophen and did not recur during subsequent treatment cycles. Despite the small decreases in the serum calcium concentration that occurred soon after each infusion cycle, none of the children had symptomatic hypocalcemia. Renal function did not change with treatment.

DISCUSSION

Osteopenia and bone fragility, the hallmarks of severe osteogenesis imperfecta, probably result from structural abnormalities in bone tissue¹ and a reduced rate of osteogenesis.¹¹ Histochemical and biochemical studies have indicated that increased resorption of bone also contributes to the disorder.^{11,20,21} Our initial goal in undertaking this study was to reduce bone resorption and to increase bone mass in children with this disease. Cyclic administration of intravenous pamidronate resulted in a rapid increase in the mineral density of the lumbar vertebrae, resulting from an improvement in the balance between bone formation and bone resorption. The decrease in urinary excretion of the *N*-telopeptide of type I collagen, a measure of bone resorption, was rapid and progressive. Serum concentrations of alkaline phosphatase, a measure of bone formation, also fell, but to a lesser degree. Taken together, these results indicate that the rate of bone turnover declined during therapy as a result of changes in the balance between formation and resorption that favored an increase in bone mass. However, the decrease in resorption did not compromise bone growth or fracture healing.

The bone mineral density of the lumbar spine, as measured by x-ray absorptiometry, is an area-related measurement that is affected by both true bone mineral density and the volume of the vertebral body. In growing children, the area-related bone mineral density increases by 3 to 6 percent per year before puberty and by 14 to 16 percent per year during puberty.^{22,23} In our patients, annualized gains in bone mineral density during pamidronate therapy (41.9 ± 29 percent) substantially exceeded these values. The z scores for bone mineral density take into account the changes in volume caused by growth.²⁴ In all the children in our study, the z scores improved during therapy, suggesting that pamidronate has a positive effect on bone mineral density. These changes were not caused by any crush-fracture-related decreases in vertebral-body size, which would artifactually increase bone mineral density, since the vertebral area increased in all the children (Table 2) and radiographs showed evidence of new bone formation (Fig. 2).

These positive effects were accompanied by a significant increase in the width of the metacarpal cortices (Table 2). Thicker cortices were also seen on

x-ray films of the long bones. These changes may have resulted in part from the improvement in mobility in many children as the mechanical strain of walking stimulated new bone formation.²⁵ The biologic importance of these effects is underscored by the decrease in the rate of fractures, even though the risk of fractures may have increased with the children's improved mobility and greater activity. In addition, all the children reported relief of chronic pain. Pain relief from bisphosphonates has been noted previously in adults with fibrous dysplasia of bone²⁶ and in a child with vertebral collapse at the onset of acute lymphoblastic leukemia.²⁷

In children with severe osteogenesis imperfecta, the growth rate is greatly reduced before the age of six or seven years, and growth almost stops thereafter.²⁸ In the children in our study, growth was reduced but not arrested before treatment, and during treatment, linear growth proceeded at a slightly (but not significantly) increased rate. At least part of this gain was probably due to increases in the size of the vertebral bodies. The sclerotic lines that appeared in the metaphyses during treatment have no known functional importance and have been noted previously.^{7,9} Impairment of mineralization and widening of the growth plates have been reported in a 13-year-old boy who received pamidronate at a dose similar to those we used in the present study.²⁶ We found no evidence of such changes in any of the 30 children in our study.

In this observational study, both the patients and their physicians and other care givers had full knowledge of the treatment being administered. We cannot exclude the possibility that there was a placebo effect, particularly with respect to the relief of bone pain and the improvement in ambulation, or that the changes reflect the passage of time rather than the effects of the treatment. However, the consistency of the clinical, biochemical, and radiologic findings suggests that the changes resulted from the administration of pamidronate. This medical therapy does not stand alone: it should be considered part of a coordinated, multidisciplinary approach to the treatment of children with osteogenesis imperfecta, including timely corrective surgery, physiotherapy, and occupational therapy. Continued follow-up will help delineate the response to therapy over time and the limits of the gains that can be achieved.

Supported by the Shriners of North America. Dr. Bishop is the recipient of a European Society for Paediatric Endocrinology Research Fellowship, sponsored by Novo Nordisk.

We are indebted to Denyse Lavallée for secretarial help; to Mark Lepik for artwork; to Mireille Dussault and Anna Lis for technical help; to Nancy Mallinak (of Ostex) for the Osteomark kits; and to Kathleen Montpetit and Nathalie Gervais (occupational therapy), Joanne Gibis (physiotherapy), Rose-Marie Chiasson (social work), Jeffrey Hohenkerk (radiology), and the nursing staff of Shriners Hospital for their untiring assistance in the examination and treatment of our patients.

REFERENCES

1. Sykes B, Ogilvie D, Wordworth P, et al. Consistent linkage of dominantly inherited osteogenesis imperfecta to the type I collagen loci: COL1A1 and COL1A2. *Am J Hum Genet* 1990;46:293-307.
2. Silience DO, Senn A, Danks DM. Genetic heterogeneity in osteogenesis imperfecta. *J Med Genet* 1979;16:101-16.
3. Cattell HS, Clayton B. Failure of anabolic steroids in the therapy of osteogenesis imperfecta: a clinical, metabolic, and biochemical study. *J Bone Joint Surg Am* 1968;50:123-41.
4. Albright JA, Grunt JA. Studies of patients with osteogenesis imperfecta. *J Bone Joint Surg Am* 1971;53:1415-25.
5. Castells S. New approaches to treatment of osteogenesis imperfecta. *Clin Orthop* 1973;93:239-49.
6. Pedersen U, Charles P, Hansen HH, Elbrond O. Lack of effects of human calcitonin in osteogenesis imperfecta. *Acta Orthop Scand* 1985;56:260-4.
7. Devogelaer JP, Malghem J, Maldague B, Nagant de Deuxchaisnes C. Radiological manifestations of bisphosphonate treatment with APD in a child suffering from osteogenesis imperfecta. *Skeletal Radiol* 1987;16:360-3.
8. Huaux JP, Lokietek W. Is APD a promising drug in the treatment of severe osteogenesis imperfecta? *J Pediatr Orthop* 1988;8:71-2.
9. Brunsen C, Hamdy NAT, Papapoulos SE. Long-term effects of bisphosphonates on the growing skeleton: studies of young patients with severe osteoporosis. *Medicine (Baltimore)* 1997;76:266-83.
10. Bembi B, Parma A, Bottega M, et al. Intravenous pamidronate treatment in osteogenesis imperfecta. *J Pediatr* 1997;131:622-5.
11. Glorieux FH, Travers R, Chabot G, Lanoue G. Bone histomorphometric analysis in osteogenesis imperfecta. *J Bone Miner Res* 1994;9:Suppl 1:S226. abstract.
12. Glorieux FH, Bishop NJ, Travers R, et al. Type V osteogenesis imperfecta. *J Bone Miner Res* 1997;12:Suppl 1:S389. abstract.
13. Wimalawansa SJ, Gunasekera RD. Pamidronate is effective for Paget's disease of bone refractory to conventional therapy. *Calcif Tissue Int* 1993;53:237-41.
14. Harinck HJ, Bijvoet OLM, Blanksma HJ, Dahlinghaus-Nienhuys PJ. Efficacious management with aminobisphosphonate (APD) in Paget's disease of bone. *Clin Orthop* 1987;217:79-98.
15. Greulich WW, Pyle SI. Radiographic atlas of skeletal development of the hand and wrist. Stanford, Calif: Stanford University Press, 1959.
16. Bleck EE. Nonoperative treatment of osteogenesis imperfecta: orthotic and mobility management. *Clin Orthop* 1981;159:111-22.
17. Garn SM, Poznanski AK, Larson K. Metacarpal lengths, cortical diameters and areas from the 10-state nutrition survey including: estimated skeletal weights, weight, and stature for whites, blacks, and Mexican-Americans. In: Jaworski ZFG, ed. Proceedings of the first workshop on bone morphometry. Ottawa, Ont.: University of Ottawa Press, 1976:367-91.
18. Underwood LE, Van Wyk JJ. Normal and aberrant growth. In: Wilson JD, Foster DW, eds. Williams textbook of endocrinology. 8th ed. Philadelphia: W.B. Saunders, 1992:1079-138.
19. Adami S, Zamberlan N. Adverse effects of bisphosphonates: a comparative review. *Drug Saf* 1996;14:158-70.
20. Baron R, Gertner JM, Lang R, Vignery A. Increased bone turnover with decreased bone formation by osteoblasts in children with osteogenesis imperfecta tarda. *Pediatr Res* 1983;17:204-7.
21. Brenner RE, Vetter U, Bollen A-M, Mörke M, Eyre DR. Bone resorption assessed by immunoassay of urinary cross-linked collagen peptides in patients with osteogenesis imperfecta. *J Bone Miner Res* 1994;9:993-7.
22. Plotkin H, Nunez M, Alvarez Filgueira ML, Zanchetta JR. Lumbar spine bone density in Argentine children. *Calcif Tissue Int* 1996;58:144-9.
23. Davie MWJ, Haddaway MJ. Bone mineral content and density in healthy subjects and in osteogenesis imperfecta. *Arch Dis Child* 1994;70:331-4.
24. Reinus WR, McAlister WH, Schranck F, Chines A, Whyte MP. Differing lumbar vertebral mineralization rates in ambulatory pediatric patients with osteogenesis imperfecta. *Calcif Tissue Int* 1998;62:17-20.
25. Frost HM. Vital biomechanics: proposed general concepts for skeletal adaptations to mechanical usage. *Calcif Tissue Int* 1988;42:145-56.
26. Liens D, Delmas PD, Meunier PJ. Long-term effects of intravenous pamidronate in fibrous dysplasia of bone. *Lancet* 1994;343:953-4.
27. Oliveri MB, Mautalen CA, Rodriguez Fuchs CA, Romanelli MC. Vertebral compression fractures at the onset of acute lymphoblastic leukemia in a child. *Henry Ford Hosp Med J* 1991;39:45-8.
28. Vetter U, Pontz B, Zauner E, Brenner RE, Spranger J. Osteogenesis imperfecta: a clinical study of the first ten years of life. *Calcif Tissue Int* 1992;50:36-41.