

ENDOVASCULAR STENT-GRAFT PLACEMENT FOR THE TREATMENT OF ACUTE AORTIC DISSECTION

MICHAEL D. DAKE, M.D., NORIYUKI KATO, M.D., R. SCOTT MITCHELL, M.D., CHARLES P. SEMBA, M.D., MAHMOOD K. RAZAVI, M.D., TAKATSUGU SHIMONO, M.D., TADANORI HIRANO, M.D., KAN TAKEDA, M.D., ISAO YADA, M.D., AND D. CRAIG MILLER, M.D.

ABSTRACT

Background The standard treatment for acute aortic dissection is either surgical or medical therapy, depending on the morphologic features of the lesion and any associated complications. Irrespective of the form of treatment, the associated mortality and morbidity are considerable.

Methods We studied the placement of endovascular stent-grafts across the primary entry tear for the management of acute aortic dissection originating in the descending thoracic aorta. We evaluated the feasibility, safety, and effectiveness of transluminal stent-graft placement over the entry tear in 4 patients with acute type A aortic dissections (which involve the ascending aorta) and 15 patients with acute type B aortic dissections (which are confined to the descending aorta). Dissections involved aortic branches in 14 of the 19 patients (74 percent), and symptomatic compromise of multiple branch vessels was observed in 7 patients (37 percent). The stent-grafts were made of self-expanding stainless-steel covered with woven polyester or polytetrafluoroethylene material.

Results Placement of endovascular stent-grafts across the primary entry tears was technically successful in all 19 patients. Complete thrombosis of the thoracic aortic false lumen was achieved in 15 patients (79 percent), and partial thrombosis was achieved in 4 (21 percent). Revascularization of ischemic branch vessels, with subsequent relief of corresponding symptoms, occurred in 76 percent of the obstructed branches. Three of the 19 patients died within 30 days, for an early mortality rate of 16 percent (95 percent confidence interval, 0 to 32 percent). There were no deaths and no instances of aneurysm or aortic rupture during the subsequent average follow-up period of 13 months.

Conclusions These initial results suggest that stent-graft coverage of the primary entry tear may be a promising new treatment for selected patients with acute aortic dissection. This technique requires further evaluation, however, to assess its therapeutic potential fully. (N Engl J Med 1999;340:1546-52.)

©1999, Massachusetts Medical Society.

ACUTE aortic dissection is one of the most catastrophic diseases that can affect the aorta. There are 10 to 20 cases per million population per year,^{1,2} and if the condition is left untreated, 36 to 72 percent of patients die within 48 hours of diagnosis, and 62 to 91 percent die within one week.³ The number of deaths due to aortic dissection is reported to exceed the number of deaths due to rupture of an abdominal aortic aneurysm.⁴ During the past two decades, a consensus has evolved regarding acceptable treatment of patients with acute aortic dissection; however, despite recent advances in medical, surgical, and endovascular treatments, this disease remains a formidable clinical challenge. For patients with acute Stanford type A dissections (which involve the ascending aorta), surgical intervention is performed immediately after diagnosis to avert the high risk of death due to various complications, including cardiac tamponade, aortic regurgitation, and myocardial infarction.⁵

In contrast, the preferred treatment for most patients with Stanford type B dissections (which do not involve the ascending aorta) is medical therapy, including the use of antihypertensive drugs and beta-blockers. Surgical treatment is reserved for specific cases that are complicated by progression of dissection, impending rupture, refractory hypertension, localized false aneurysm, continued pain, or end-organ ischemia caused by compromise of the aortic branches.⁶ The current mortality rate among patients who receive medical therapy for type B dissection remains about 20 percent,^{7,8} whereas the mortality rates among patients who undergo surgical repair of acute type A and B dissections are currently about 29 percent⁹ and 35 percent,¹⁰ respectively. However, for acute disease complicated by end-organ ischemia, the surgical mortality rate exceeds 50 percent.^{11,12}

Endovascular stent-grafting is emerging as a less invasive alternative to surgical graft placement for patients with aneurysmal diseases. Its efficacy and safe-

From the Division of Cardiovascular and Interventional Radiology (M.D.D., C.P.S., M.K.R.) and the Department of Cardiovascular and Thoracic Surgery (R.S.M., D.C.M.), Stanford University School of Medicine, Stanford, Calif.; and the Departments of Radiology (N.K., T.H., K.T.) and Thoracic and Cardiovascular Surgery (T.S., I.Y.), Mie University School of Medicine, Tsu, Japan. Address reprint requests to Dr. Dake at the Division of Cardiovascular and Interventional Radiology, H-3647, Stanford University Medical Center, Stanford, CA 94305, or at mddake@leland.stanford.edu.

ty have been reported for the treatment of thoracic aortic aneurysms, abdominal aortic aneurysms, and peripheral arterial aneurysms.¹³⁻¹⁷ In this study, we used stent-grafts to cover the primary aortic intimal tear and thereby obliterate the aortic false lumen in 19 patients with acute aortic dissections.

METHODS

Selection of Patients

Between October 1996 and October 1998, 59 patients with aortic dissection underwent arteriographic examination at our two hospitals to evaluate their clinical symptoms and signs and to detect extension of the dissection process or infradiaphragmatic visceral or lower-extremity ischemic complications. All the patients underwent chest radiography and cross-sectional imaging of the chest and abdomen by spiral computed tomography (CT) or magnetic resonance imaging (MRI) before the endovascular procedure. Compromise of the aortic branch vessels was ruled out in 10 of these patients. Twenty-eight patients with impaired blood flow in the peripheral branches were treated percutaneously with endovascular-stent placement or with balloon fenestration of the dissection flap. These percutaneous techniques have been previously described.^{18,19} During the same two-year period, 53 patients (49 patients with type A dissection and 4 with type B dissection) underwent surgical procedures for the treatment of acute aortic dissection and 48 patients (26 with type A dissection and 22 with type B dissection) underwent operative repair of chronic aortic dissection.

Nineteen patients with acute aortic dissection (Patients 1 through 10 at Stanford University and Patients 11 through 19 at Mie University) underwent stent-graft placement over the primary entry tear. Approval for the study had been obtained from the institutional review board at each medical center, and informed consent was granted by each patient. The 15 men and 4 women ranged in age from 16 to 75 years (mean [\pm SD], 53 \pm 15 years). The interval between diagnosis and stent-grafting was from 1 to 13 days (mean, 3.9 \pm 3.6 days). These patients were selected for stent-graft intervention because they had symptoms of obstruction in multiple branch vessels, an atypical location of the entry tear, acute aortic rupture, or persistent severe back pain. Exclusion criteria included a distance of less than 1 cm between the left subclavian artery and the intimal tear and tortuosity or narrowness of the iliac or femoral arteries that prohibited introduction of the stent-graft delivery system. Seventeen of the 19 patients had a history of hypertension.

Specific characteristics of the patients are listed in Table 1. Of the 19 patients, 4 had an acute type A dissection and 15 had an acute type B dissection. The false lumen was patent in all the patients, and the dissection extended distally into one or both of the iliac arteries in 11 patients. Of the four patients with type A dissection, three (Patients 12, 13, and 16) had a primary entry tear in the proximal third of the descending aorta and one (Patient 9) had a tear in the middle third, with retrograde extension that involved the proximal ascending aorta. In two of these four patients, an associated pericardial effusion was identified by CT scanning.

Of the 15 patients with acute type B dissection, 6 had a "classic" entry-tear location, and 9 had a primary tear that was identified at an atypical site in the distal portion of the descending aorta. The dissection extended into the abdominal aorta in 7 patients and distally into the iliac arteries in 12. In none of the patients was the aortic dissection associated with a penetrating aortic ulcer or intramural hematoma. In three patients (Patients 5, 7, and 11), acute type B dissection was complicated by aortic rupture. Patient 2 underwent placement of a second stent-graft two months after the initial procedure for treatment of partial recanalization of the false lumen caused by a new entry tear 9 cm distal to the end of the first device. One patient considered for stent-graft therapy was excluded because the primary tear was less than

1 cm from the left subclavian artery. No patient considered for stent-graft placement was excluded because of excessively tortuous iliac arteries.

In cases of aortic dissection, involvement of the peripheral branch vessels is often complex and may be associated with substantial end-organ ischemia. The evaluation and diagnosis of branch-vessel compromise have been described elsewhere.^{18,19} Branch-vessel involvement was classified as "static" if the dissection flap extended directly into an aortic branch, thereby narrowing its lumen, and as "dynamic" if the flap prolapsed over the origin of the branch vessel or collapsed the true lumen of the aorta above it.

Endovascular Prosthesis

The endovascular stent-grafts were custom-designed for each patient according to measurements obtained from the diagnostic imaging studies. Since it is difficult to know the original diameter of the aorta in cases of aortic dissection, the diameter of the non-dissected portion of the aorta proximal to the entry tear (as measured by CT, MRI, or quantitative aortography with a calibrated catheter) was used to plan the diameter of the stent-graft. In this way, the residual radial force of the stent could provide an effective frictional seal against the aortic wall and dissection flap.

The inner framework of each device was composed of 2.5-cm-long Z-shaped stent elements (Cook, Bloomington, Ind.) interconnected with 2-0 polypropylene sutures to form a stent of the appropriate length. This metallic framework was covered with woven polyester graft material (Cooley Veri-Soft, Meadox Medicals, Oakland, N.J.) for Patients 1, 2 (first dissection), and 3 through 10 and with balloon-dilated polytetrafluoroethylene graft material (Impra, Tempe, Ariz.) for Patients 2 (second dissection) and 11 through 19. Stent-graft fabrication has been described in detail previously.^{13,14}

Stent-Graft Placement

Intensive medical therapy with antihypertensive drugs and beta-blockers was initiated immediately after acute aortic dissection was diagnosed. All stent-graft procedures were performed in an angiography suite. After informed consent had been obtained from each patient, a 5-French calibrated angiographic pigtail catheter was advanced into the ascending aorta to permit an arteriographic evaluation of the distance between the left subclavian artery and the entry tear. In all cases, it was possible to identify the entrance site precisely. Intravascular ultrasound imaging was used in most cases to characterize further the anatomical relations between the true and false aortic lumens and the branch vessels.

After the arteriographic evaluation, 5000 U of heparin sodium was administered intravenously and a 22-French sheath (Keller-Timmerman Sheath, Cook) was introduced transfemorally over a 0.035-in. (0.89-mm) stiff guide wire. The stent-graft was then delivered through the sheath and placed within the true lumen of the aorta. After the device was deployed, arteriography or intravascular ultrasonography was performed to confirm the position of the device relative to the entry tear and to evaluate the size of and flow within the aortic lumens and branch vessels. Details regarding the endovascular procedure, the deployment of the stent-graft, and postprocedural management have been reported previously.^{13,14} Adjunctive open thoracotomy was not necessary to treat sequelae of the aortic dissection or of the stent-graft procedure.

The average length of the entry tear was 1.9 cm (range, 1.2 to 2.9). The mean diameter of the implanted stent-graft was 29.7 \pm 5.1 mm, and the average length of the device was 6.9 \pm 1.5 cm. In two patients (11 percent), deployment of more than one stent-graft was required during the endovascular procedure to cover the tear completely.

Follow-up Imaging and Analysis

The follow-up protocol included CT scanning performed within 72 hours after the stent-graft procedure to assess the extent of thrombosis in the aortic false lumen, the size of the true and false lumens, and the perfusion of branch vessels. Spiral CT scans were then obtained six months after stent-graft placement, yearly

TABLE 1. CHARACTERISTICS OF 19 PATIENTS WHO RECEIVED ENDOVASCULAR STENT-GRAFTS TO TREAT ACUTE AORTIC DISSECTIONS.

PATIENT No.	STANFORD TYPE	COEXISTING CONDITIONS	EXTENT OF THROMBOSIS OF THE FALSE LUMEN	DURATION OF FOLLOW-UP
1	B	Hypertension	Complete	28 mo
2*	B	Hypertension, abdominal pain, bilateral claudication	Complete	20 mo
	B	Hypertension	Complete	18 mo
3	B	Hypertension, abdominal pain, ischemia of the right leg	Partial	16 mo
4	B	Hypertension, azotemia, abdominal pain, ischemia of the left leg	Complete	7 days (died)
5	B	Aortic rupture with hematoma periaortically and in the right side of the chest, abdominal pain, acute renal failure, ischemia and paralysis of legs	Partial	1 day (died)
6	B	Hypertension, abdominal pain, ischemia of the right leg	Complete	12 mo
7	B	Aortic rupture with hematoma of the left psoas, hypertension, abdominal pain, acute renal failure, ischemia of legs	Complete	10 mo
8	A	Hypertension, bilateral carotid and left subclavian dissection	Partial	5 mo
9	B	Hypertension	Partial	5 mo
10	B	Hypertension	Complete	4 mo
11	B	Aortic rupture with hematoma periaortically and in the left side of the chest, chronic renal failure, aortic regurgitation	Complete	9 days (died)
12	A	Hypertension	Complete	18 mo
13	A	Hypertension, cerebral hemorrhage, pericardial effusion	Complete	17 mo
14	B	Hypertension, diabetes mellitus, severe back pain	Complete	16 mo
15	B	Hypertension, aortic regurgitation	Complete	15 mo
16	A	Hypertension, pericardial effusion	Complete	12 mo
17	B	Hypertension	Complete	11 mo
18	B	Hypertension	Complete	10 mo
19	B	Hypertension, acute renal failure, ischemia of legs	Complete	9 mo

*Two months after the initial stent-graft procedure, Patient 2 underwent a second procedure for treatment of a new dissection.

thereafter, and at the onset of any new symptoms to evaluate the aortic characteristics listed above and to monitor the transverse diameters of the thoracic and abdominal segments of the aorta. The diameters of the true lumen, of the proximal, middle, and distal segments of the descending aorta, and of the abdominal aorta at the level of the renal arteries were measured by CT in all patients and supplemented by intravascular ultrasonographic measurements in Patients 1 through 8. At all the levels, the diameters of the true lumen and of the overall aorta were measured along a line perpendicular to the intimal flap. Early mortality and morbidity included events occurring within 30 days after the stent-graft procedure, either in the hospital or after discharge. Information about the patients was compiled from retrospective chart review and by contacting the patients or their treating physicians. Final follow-up status was determined between October 1998 and February 1999 and was 100 percent complete; the mean duration of follow-up was 13 months, and the maximal duration 28 months.

Statistical Analysis

Clinically important rates are reported with 95 percent confidence intervals, and continuous variables are expressed as means \pm SD (means \pm SE in the figures). Comparisons of aortic measurements before and after stent-graft treatment were performed with paired t-tests; P values of less than 0.05 were considered to indicate statistical significance.

RESULTS

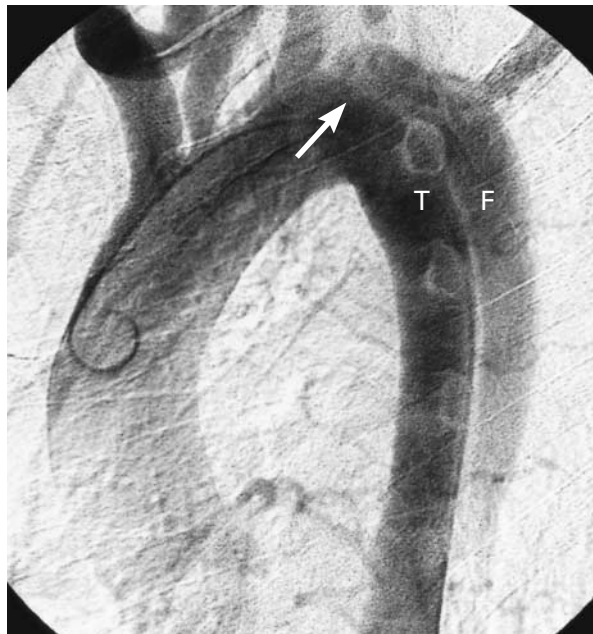
Stent-graft deployment within the true lumen of the aorta was technically successful in all cases (Fig.

1). In three patients (Patients 3, 6, and 15), a small amount of contrast medium was observed to be leaking through the intimal tear immediately after deployment of the stent-graft. In Patients 6 and 15, however, follow-up aortography or CT scans obtained within one month after stent-graft placement demonstrated complete coverage of the initial entry tear, without flow of contrast medium into the false lumen.

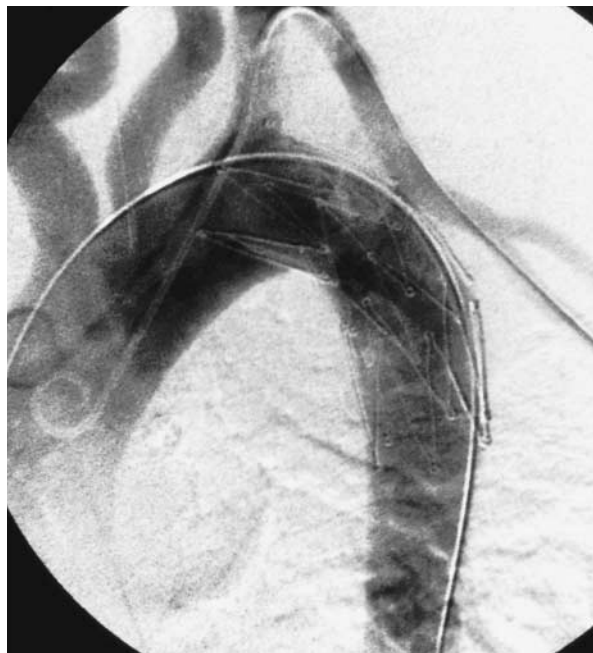
Two patients had residual flow into the false lumen from a proximal communication (Patient 14) or distal communication (Patient 4), and in each case more than one stent-graft was needed to cover the entry tear completely. Information about the extent of thrombosis in the false lumen of the thoracic aorta is given in Table 1.

Early Mortality

Three of the 19 patients died, for an early procedure-related mortality of 16 percent (95 percent confidence interval, 0 to 32 percent). Two patients (11 percent) with acute type B dissection had acute rupture of the false lumen of the distal aorta and died eight hours (Patient 5) and nine days (Patient 11) after the stent-graft procedure. Patient 5, a 16-



A



B

Figure 1. Thoracic Aortograms Obtained before and Immediately after Stent-Graft Placement over the Primary Entry Tear. Before stent-graft deployment (Panel A), there is flow of contrast medium from the true lumen (T) across the entry tear (arrow) into the false lumen (F). After stent-graft placement (Panel B), only the true lumen is evident.

year-old boy with Ehlers–Danlos syndrome type III, presented initially with serious complications of distal ischemia (including paraplegia, visceral ischemia, and lack of pulses in the legs) and had previously had a contained rupture of the thoracoabdominal aorta. Patient 11 was a 75-year-old man in whom pneumonia developed after the stent-graft procedure. Patient 4, a young cocaine abuser, died at 7 days as a result of sepsis associated with infarction of the gut and leg despite stent-graft treatment.

Early Morbidity

Serious complications early after the procedure included infarction of the colon and distal ileum, treated with total colectomy and partial resection of the small bowel (Patient 4); gangrene of a leg, requiring amputation above the knee (Patient 4); pneumonia (Patient 11); and renal failure, requiring hemodialysis for two weeks (Patient 7).

Branch-Vessel Obstruction

Symptomatic branch-vessel obstruction caused directly by the aortic dissection affected 11 patients and 38 infradiaphragmatic vascular beds, or 33 percent of the 114 peripheral vascular territories that were evaluated among all 19 patients. In addition, there was anatomical involvement of 17 other branch vessels in 10 patients without referable symptoms or corresponding hemodynamic evidence of substantial obstruction. In each of seven patients, more than two ischemic vascular territories were identified.

Ischemic branch-vessel obstruction involving the celiac, superior mesenteric, left and right renal, and left and right iliac arteries was caused exclusively by a dynamic process involving 22 arteries, by both dynamic and static mechanisms affecting 15 arteries, and by an exclusively static mechanism in 1 artery. After placement of a stent-graft over the entry tear, all 22 of the branch vessels with exclusively dynamic obstruction and 6 of the 15 arteries with combined dynamic and static involvement were immediately reperfused without arteriographic, hemodynamic, or clinical evidence of residual obstruction.

In Patients 5 and 7, the dissection extended into one iliac artery without a reentry tear in the false lumen. During the time between the onset of symptoms (which included pain, numbness, and extreme weakness of both legs) and the arteriographic evaluation, the false lumen of the infrarenal aorta had thrombosed. Consequently, the lower-extremity ischemia associated with the combined dynamic and static involvement of the iliac arteries in both patients did not change after stent-graft placement across the entry tear in the thoracic aorta. In both patients, reperfusion of the legs occurred after deployment of supplemental Wallstents (Schneider, Plymouth, Minn.) within the collapsed true lumen of the infrarenal aorta and proximal left iliac artery (Patient 5) and

within the aorta and both iliac arteries from the mid-level of the infrarenal aorta (Patient 7).

In the other five vascular beds with residual static obstruction despite resolution of the dynamic component after stent-graft placement (Patients 2, 3, 4, and 7), an uncovered stent was deployed within the true lumen of the affected branch artery to relieve the residual pressure gradient.

False Lumen

Complete thrombosis of the thoracic aortic false lumen was evident in 15 patients (79 percent) and partial thrombosis was evident in 4 patients (21 percent) on angiographic studies or CT images obtained within six months after stent-graft placement. Thrombosis of the false lumen in the abdominal aorta was observed in only one patient (5 percent).

In the four patients with type A dissection, the mean diameter of the ascending aorta decreased from 41 mm (range, 35 to 46) before the stent-graft procedure to 34 mm (range, 32 to 36) on the latest available CT image after the procedure. The mean diameters of the descending and abdominal aorta measured at various levels before and within 72 hours after stent-graft placement are shown in Figure 2A. Overall, the diameters before the procedure were similar to those after ($P=0.63$ for the middle third of the descending aorta, $P=0.47$ for the distal third, and $P=0.90$ for the abdominal aorta), but the diameter of the proximal descending aorta was significantly smaller after the procedure ($P=0.04$).

Figure 2B plots the mean diameters of the aortic true lumen before and immediately after stent-grafting. There was a significant increase in the diameter of the true lumen immediately after stent-graft deployment ($P<0.001$) at each level.

During the follow-up period, 13 patients underwent CT imaging a minimum of six months after stent-graft placement; no evidence of aneurysm formation in the false lumen was observed. In none of the patients was the diameter of the aorta larger at any level than the diameter measured before or immediately after stent-graft deployment. In six cases, the latest follow-up imaging study demonstrated disappearance of the false lumen, with no residual evidence of dissection, in the descending thoracic aorta.

Late Survival and Complications

None of the patients died late during the follow-up period. In addition, no cases of aneurysm or aortic rupture were documented, and in no case was aortic operation needed.

DISCUSSION

Aortic dissection is a catastrophic process associated with a wide variety of clinical manifestations. The cause of the associated symptoms can vary and is often complex. Part of the confusion stems from

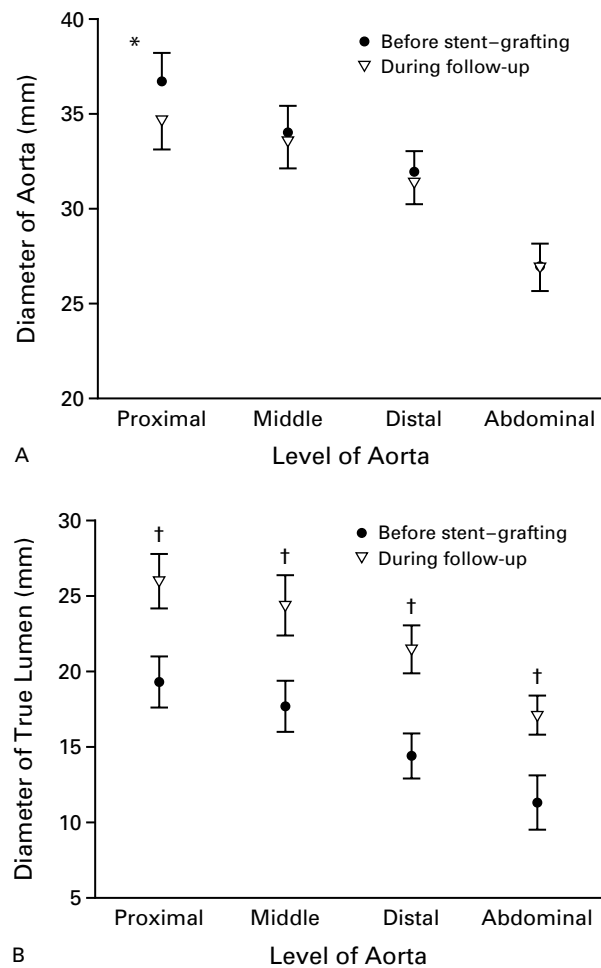


Figure 2. Mean (\pm SE) Diameters of the Aorta (Panel A) and True Lumen (Panel B) before and after Stent-Graft Placement.

The diameters of the descending (proximal, middle, and distal) and abdominal aorta and of the true lumen were measured at the same levels before and after stent-graft placement. The asterisk indicates a significant difference ($P=0.04$) between the measurements of the aorta before the procedure and during follow-up. The daggers indicate a significant difference ($P<0.001$) between measurements of the true lumen before the procedure and during follow-up.

the anatomical variability with which the dissection flap can propagate distally. As a result, the true and false lumens may appear in any of numerous complex configurations and the branch-vessel origins may be distributed in unpredictable patterns, occasionally in association with life-threatening ischemia of the viscera and extremities.

Assessment of anatomical involvement in aortic dissection can be simplified, however, by evaluating patients for indications for nonmedical intervention. Moreover, it is possible to distill the diverse constellations of clinical manifestations into four interventional imperatives. These include aortic rupture,

cardiac and coronary complications resulting from proximal extension of the dissection, branch-vessel ischemia, and aneurysm formation.

Among patients with acute type B aortic dissection, more than 60 percent of associated deaths are due to local rupture, usually of the false lumen.²⁰ Surgical therapy usually consists of limited replacement of the descending aorta at the level of the initial entry tear; flow into the false lumen is obliterated by circumferential reapposition of the dissected septum to the aortic wall at the distal graft anastomosis.²⁰ The rationale for surgical therapy is to obviate the most frequent cause of death. Our experience suggests that stent-graft placement over the primary entry tear in patients with acute type B dissections may be an alternative to open surgery. The result is similar to surgical obliteration of the entry tear because it can exclude flow through the initial tear in the intima and redirect aortic blood flow exclusively into the true lumen.

Acute type A aortic dissection due to a primary tear in the intima of the descending thoracic aorta (in which case involvement of the ascending aorta is due to retrograde proximal extension of the primary tear) is recognized as one of the most surgically challenging subtypes of aortic dissection. The incidence of this subtype among DeBakey type III dissections ranges from 10 to 27 percent.^{11,21,22} Among our four patients with type A dissection of this morphologic configuration, two had pericardial fluid, identified by CT scanning, without clinical evidence of cardiac tamponade. All four patients were considered poor candidates for extensive open surgical repair of the aorta. The primary intimal tears were closed by stent-graft placement, which led to thrombosis of the false lumen in the ascending aorta, arch, and descending aorta within 48 hours after the procedure (as confirmed by CT). Follow-up imaging in the two patients with pericardial fluid showed complete resolution of the process.

Several groups have conducted feasibility studies in animal models to test the use of uncovered stents for the treatment of acute aortic dissection.²³⁻²⁵ Charnsangavej et al. commented on the possibility of using uncovered Z-shaped stents for the treatment of aortic dissection on the basis of results in a cadaveric aorta.²⁶ In the experiments in animals, it was necessary to deploy the uncovered stent over the full length of the dissected aorta to obtain the desired caliber of the true lumen; however, even such extensive stenting could not completely reapproximate the intimal flap and the adventitia. Consequently, residual blood flow in the false lumen was evident in many of the animals. In contrast, complete thrombosis of the false lumen was consistently achieved by Kato and colleagues after closure of the initial intimal tear by endovascular placement of polyester-covered Z-shaped stents.²⁷

Aortic dissection is complicated by major symptoms of peripheral vascular ischemia in 30 to 50 percent of patients.^{12,28} Renal or mesenteric ischemia is an independent determinant of surgery-related mortality in patients with either type A or type B aortic dissection.¹¹ For the treatment of acute or chronic type A or type B aortic dissection, reperfusion of ischemic distal arterial beds by radiologically guided interventions has shown promise; however, these endovascular procedures — which include stent placement, balloon fenestration of the flap, or a combination of both — often are technically complex, require multiple steps, and are time consuming.^{18,19} Stent-graft placement across the primary entry tear is an effective single-step treatment that may be more efficient than previously described endovascular techniques for the relief of ischemic complications and less invasive than aortic graft replacement by thoracotomy. This strategy therefore has important potential because of the high mortality rate among patients with aortic dissections complicated by ischemia involving the renal, mesenteric, and lower-extremity vasculature, whether or not they undergo definitive surgical treatment of the thoracic aorta.

In this series, seven patients (37 percent) had evidence of ischemia in more than two major infradiaphragmatic vascular beds, as well as dynamic involvement of the branch vessels and collapse of the true lumen. In this subgroup, there was an increase in the diameter of the true lumen immediately after placement of the stent-graft across the intimal tear. The increase in size and improvement in flow in the true lumen correlated with clinical and hemodynamic relief of branch-vessel obstruction in all 22 of the ischemic vascular beds that were affected exclusively by dynamic branch-vessel involvement and in 6 of 15 (40 percent) of the vascular beds that were compromised by a combination of dynamic and static branch-vessel obstruction. The latter underscores the possibility that residual branch-vessel obstruction may persist after stent-graft treatment as a result of the static component, which may not be completely relieved by redirection of flow into the true lumen. Adjunctive deployment of a stent within the true lumen of the affected branch may still be necessary to treat effectively the obstruction caused by direct extension of the flap into the branch. Fortunately, the salutary effect of this endovascular technique for the treatment of peripheral ischemic sequelae of aortic dissection has been well established; restoration of the blood flow to compromised vessels and associated clinical improvements have been achieved in 92 to 100 percent of cases reported.^{18,19}

Surgical therapy involving direct approximation by suture of the dissected septum to the adventitia at the distal graft anastomosis and redirection of blood flow into the true lumen usually restores blood flow in compromised aortic branches in patients with acute

dissection.^{3,5,20} Adequate perfusion of a branch vessel originating exclusively from the false lumen, on the other hand, requires sufficient flow to the branch through a corresponding natural fenestration in the dissected septum that allows communication from the true lumen to the false lumen at that level.²⁹ In the majority of cases in this series, at least one major infradiaphragmatic branch vessel originated exclusively from the false lumen; however, after stent-grafting, no new clinical symptoms attributable to ischemia of the vascular beds supplied by these branches were observed.

In addition to promptly averting serious end-organ ischemia or infarction, stent-graft placement over the intimal tear can prevent the eventual formation of an aneurysm by facilitating complete thrombosis of the thoracic aortic false lumen. In this series, thrombosis and shrinkage of the false lumen in the descending thoracic aorta were observed in 15 of 19 patients after stent-graft placement, and partial thrombosis of the thoracic aortic false lumen was observed in the other 4. Even if only partial thrombosis of the false lumen is achieved, it still can be advantageous: it may protect the false lumen from enlarging over time, since systemic blood pressure is no longer directly transmitted from the aorta through a large primary tear in the intima.

During the first four to five years after the initial diagnosis, an aneurysm of the thoracic aortic false lumen develops in 14 to 20 percent of patients with acute type B dissection that is treated with medical therapy alone.^{3,7} In the chronic phase of aortic dissection, surgical treatment of a false-lumen aneurysm can be associated with substantial risk. Although we cannot draw any concrete conclusions from the short-term follow-up of this small number of patients, it is reasonable to speculate that interventional stent-grafting of aortic dissections in the acute phase may limit the frequency of this complication.

The short-term results of stent-graft placement in this highly selected series of patients with acute aortic dissections suggest that this endovascular approach provides an alternative to current surgical treatment of acute type B dissections in which the primary tear is located distal to the left subclavian artery. The four patients with an acute type A aortic dissection in this series had the primary tear in the descending aorta, with retrograde extension into the ascending aorta, and were not good candidates for surgery; whether on further examination the endovascular approach will prove to be prudent in such cases is unknown, but the preliminary results are promising. Finally, it remains to be determined whether this alternative treatment for uncomplicated, acute type B dissections will be associated with long-term results that are superior to those with medical therapy alone.

REFERENCES

- Sorenson HR, Olsen H. Ruptured and dissecting aneurysms of the aorta: incidence and prospects of surgery. *Acta Chir Scand* 1964;128:644-50.
- Pate JW, Richardson RJ, Eastridge CE. Acute aortic dissections. *Ann Surg* 1976;42:395-404.
- Anagnostopoulos CE, Prabhakar MJS, Kittle CE. Aortic dissections and dissecting aneurysms. *Am J Cardiol* 1972;30:263-73.
- Kouchoukos NT, Dougenis D. Surgery of the thoracic aorta. *N Engl J Med* 1997;336:1876-88.
- Miller DC, Stinson EB, Oyer PE, et al. Operative treatment of aortic dissections: experience with 125 patients over a sixteen-year period. *J Thorac Cardiovasc Surg* 1979;78:365-82.
- Fann JJ, Miller DC. Aortic dissection. *Ann Vasc Surg* 1995;9:311-23.
- Wheat MW. Current status of medical therapy of acute dissecting aneurysms of the aorta. *World J Surg* 1980;4:563-9.
- Elefteriades JA, Hartleroad J, Gusberg RJ, et al. Long-term experience with descending aortic dissection: the complication-specific approach. *Ann Thorac Surg* 1992;53:11-21.
- Ergin MA, Phillips RA, Galla JD, et al. Significance of distal false lumen after type A dissection repair. *Ann Thorac Surg* 1994;57:820-5.
- Crawford ES, Svensson LG, Coselli JS, Safi HJ, Hoss KR. Aortic dissection and dissecting aortic aneurysms. *Ann Surg* 1988;208:254-73.
- Miller DC, Mitchell RS, Oyer PE, Stinson EB, Jamieson SW, Shumway NE. Independent determinants of operative mortality for patients with aortic dissection. *Circulation* 1984;70:Suppl I:1-153-I-164.
- Cambria RP, Brewster DC, Gertler J, et al. Vascular complications associated with spontaneous aortic dissection. *J Vasc Surg* 1988;7:199-209.
- Dake MD, Miller DC, Semba CP, Mitchell RS, Walker PJ, Liddell RP. Transluminal placement of endovascular stent-grafts for the treatment of descending thoracic aortic aneurysms. *N Engl J Med* 1994;331:1729-34.
- Mitchell RS, Dake MD, Semba CP, et al. Endovascular stent-graft repair of thoracic aortic aneurysms. *J Thorac Cardiovasc Surg* 1996;111:1054-62.
- Parodi JC, Palmaz JC, Barone HD. Transfemoral intraluminal graft implantation for abdominal aortic aneurysms. *Ann Vasc Surg* 1991;5:491-9.
- Blum U, Voshage G, Lammer J, et al. Endoluminal stent-grafts for infrarenal abdominal aortic aneurysms. *N Engl J Med* 1997;336:13-20.
- Razavi MK, Dake MD, Semba CP, Nyman URO, Liddell RP. Percutaneous endoluminal placement of stent-grafts for the treatment of isolated iliac artery aneurysms. *Radiology* 1995;197:801-4.
- Slonim SM, Nyman URO, Semba CP, Miller DC, Mitchell RS, Dake MD. Aortic dissection: percutaneous management of ischemic complications with endovascular stents and balloon fenestration. *J Vasc Surg* 1996;23:241-53.
- Williams DM, Lee DY, Hamilton BH, et al. The dissected aorta: percutaneous treatment of ischemic complications — principles and results. *J Vasc Interv Radiol* 1997;8:605-25.
- Miller DC. Surgical management of aortic dissections: indications, perioperative management, and long-term results. In: Doroghazi RM, Slater EE, eds. *Aortic dissection*. New York: McGraw-Hill, 1983:193-243.
- Erbel R, Oelert H, Meyer J, et al. Effect of medical and surgical therapy on aortic dissection evaluated by transesophageal echocardiography: implications for prognosis and therapy. *Circulation* 1998;97:1604-15.
- Kazui T, Tamiya Y, Tanaka T, Komatsu S. Extended aortic replacement for acute type A dissection with the tear in the descending aorta. *J Thorac Cardiovasc Surg* 1996;112:973-8.
- Trent MS, Parsonnet V, Shoenfeld R, et al. A balloon-expandable intravascular stent for obliterating experimental aortic dissection. *J Vasc Surg* 1990;11:707-17.
- Moon MR, Dake MD, Pelc LR, et al. Intravascular stenting of acute experimental type B dissections. *J Surg Res* 1993;54:381-8.
- Kato N, Hirano T, Takeda K, Nakagawa T, Mizumoto T, Yuasa H. Treatment of acute aortic dissections with expandable metallic stents: experimental study. *J Vasc Interv Radiol* 1994;5:417-23.
- Charnsangavej C, Wallace S, Wright KC, Carrasco CH, Gianturco C. Endovascular stent for use in aortic dissection: an in vitro experiment. *Radiology* 1985;157:323-4.
- Kato N, Hirano T, Takeda K, et al. Treatment of aortic dissections with a percutaneous intravascular endoprosthesis: comparison of covered and bare stents. *J Vasc Interv Radiol* 1994;5:805-12.
- Fann JJ, Sarris GE, Mitchell RS, et al. Treatment of patients with aortic dissection presenting with peripheral vascular complications. *Ann Surg* 1990;212:705-13.
- White RD, Ullyot DJ, Higgins CB. MR imaging of the aorta after surgery for aortic dissection. *AJR Am J Roentgenol* 1988;150:87-92.