

RADIAL SCARS IN BENIGN BREAST-BIOPSY SPECIMENS AND THE RISK OF BREAST CANCER

TIMOTHY W. JACOBS, M.D., CELIA BYRNE, PH.D., GRAHAM COLDITZ, M.D., JAMES L. CONNOLLY, M.D.,
AND STUART J. SCHNITT, M.D.

ABSTRACT

Background Radial scars are benign breast lesions of uncertain clinical significance. In particular, it is not known whether these lesions alter the risk of breast cancer in women with benign breast disease. We conducted a case-control study of women who had benign breast lesions with or without radial scars.

Methods We reviewed benign breast-biopsy specimens from 1396 women enrolled in the Nurses' Health Study, including 255 women in whom breast cancer subsequently developed and 1141 women without subsequent breast cancer (controls). The controls were matched to the women with subsequent breast cancer according to age and the year when the benign lesion was identified. The median follow-up after biopsy of the benign lesions was 12 years.

Results Radial scars were identified in biopsy specimens from 99 women (7.1 percent). Most biopsy specimens with radial scars had only one radial scar (60.6 percent), and they tended to be incidental microscopical findings (median size, 4.0 mm). The women with radial scars had a risk of breast cancer that was almost twice the risk of the women without scars, regardless of the histologic type of benign breast disease (relative risk, 1.8; 95 percent confidence interval, 1.1 to 2.9). Among women who had proliferative disease without atypia as compared with women who had nonproliferative disease, the relative risk of breast cancer was 3.0 (95 percent confidence interval, 1.7 to 5.5) for those with radial scars and 1.5 (95 percent confidence interval, 1.1 to 2.1) for those without radial scars. Among women with atypical hyperplasia as compared with women with nonproliferative disease, the relative risk of breast cancer was 5.8 (95 percent confidence interval, 2.7 to 12.7) for those with radial scars and 3.8 (95 percent confidence interval, 2.4 to 5.9) for those without radial scars.

Conclusions Radial scars are an independent histologic risk factor for breast cancer. (N Engl J Med 1999;340:430-6.)

©1999, Massachusetts Medical Society.

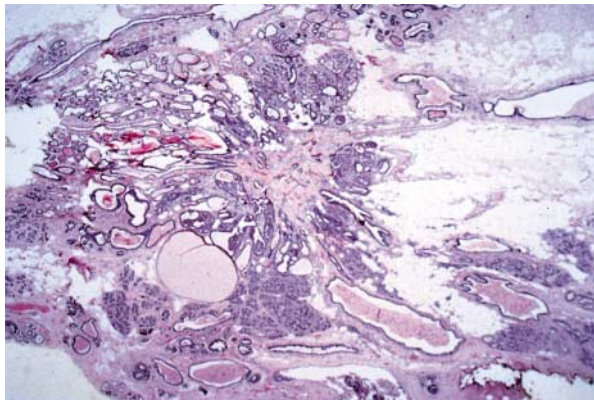
CLINICAL studies have shown that among women with benign breast disease on biopsy, the risk of subsequent breast cancer is associated with the histologic category of the benign disease.¹⁻³ In particular, the risk of breast cancer among women with benign proliferative lesions without atypia is almost twice the risk among women with nonproliferative disease, whereas the risk among those with atypical hyperplasia is four to five times the risk among those with nonproliferative disease. Other studies have refined the risk estimates by evaluating the risk of breast cancer associated with different types of atypical hyperplasia⁴ or specific benign lesions such as sclerosing adenosis,⁵ fibroadenomas,⁶ and papillomas.⁷

Radial scars are a specific type of benign breast lesion that pathologists commonly detect, yet the risk of subsequent breast cancer associated with these lesions is unknown. Furthermore, it is not known whether the presence of radial scars in women with different histologic categories of benign breast disease alters the risk of breast cancer.

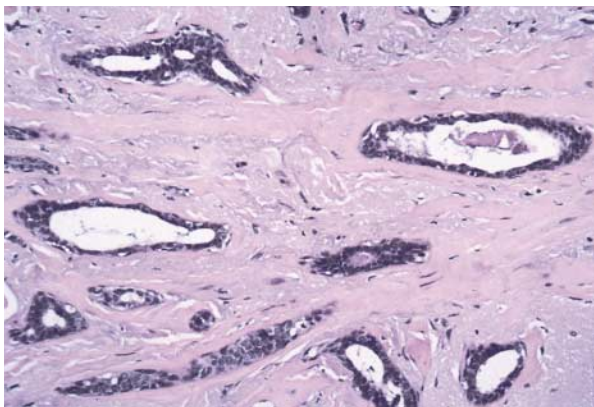
Radial scars are characterized microscopically by a fibroelastotic core from which ducts and lobules radiate. These ducts and lobules exhibit various alterations, including cysts and proliferative lesions (Fig. 1). Radial scars are most often incidental microscopical findings in breast tissue removed because of other possible abnormalities. However, larger radial scars are being detected with increasing frequency in women who undergo mammographic screening. The morphologic similarity of radial scars to cancer⁸⁻¹² and the finding of carcinoma in some radial scars¹³⁻¹⁵ have suggested that these lesions may represent an early phase in the development of certain types of breast cancer. Several studies have evaluated the frequency of radial scars in women with breast cancer, but with conflicting results.¹⁶⁻¹⁹ The few clinical follow-up studies that have been performed have not demonstrated an increased risk of cancer among women with radial scars, but these studies were small and lacked suitable controls.^{20,21}

To examine the association between the presence

From the Department of Pathology, Beth Israel Deaconess Medical Center (T.W.J., J.L.C., S.J.S.); Harvard Medical School (T.W.J., C.B., G.C., J.L.C., S.J.S.); and Channing Laboratory, Department of Medicine, Brigham and Women's Hospital (C.B., G.C.) — all in Boston. Address reprint requests to Dr. Schnitt at the Department of Pathology, Beth Israel Deaconess Medical Center, East Campus, 330 Brookline Ave., Boston, MA 02215.



A



B

Figure 1. Histologic Features of a Radial Scar.

A low-power view shows the fibroelastotic core, with radiating ducts and lobules exhibiting proliferative changes and microcysts (Panel A, $\times 20$). A high-power view of the central fibroelastotic area shows entrapped benign ducts (Panel B, $\times 400$).

of radial scars and the subsequent risk of breast cancer in women with various categories of benign breast disease, we conducted a case-control study within the Nurses' Health Study, which is a long-term, prospective study of risk factors for breast carcinoma in women in the United States.

METHODS

Study Population

The first Nurses' Health Study began in 1976, when 121,701 female registered nurses born between 1921 and 1946 responded to a mailed questionnaire about potential risk factors for breast cancer and medical history. The second Nurses' Health Study began in 1989, when 116,671 female registered nurses born between 1946 and 1964 responded to a similar mailed questionnaire. Every two years, participants in both studies complete a questionnaire that updates this information. On all questionnaires, participants are asked about a past diagnosis of benign breast disease requiring hospitalization or confirmed by a breast biopsy.

Eligible participants in the current study included all women in

the Nurses' Health Study who had not received a diagnosis of cancer (other than nonmelanoma skin cancer) at the beginning of each two-year follow-up interval and who reported a diagnosis of benign breast disease with either hospitalization or biopsy on the initial questionnaire or a subsequent questionnaire. Among these participants, any woman who reported a diagnosis of breast cancer (except lobular carcinoma in situ) at least one year after the first reported diagnosis of benign breast disease and before July 1992 (for participants in the first Nurses' Health Study) or July 1991 (for those in the second) was considered to have breast cancer. For each of the women with breast cancer, up to four controls without cancer were randomly selected from the women who were born the same year and who received the diagnosis of benign disease the same year.

All eligible participants were asked to provide written consent to allow retrieval and review of the pathology slides from the first biopsy showing benign breast disease. Seventy percent of the respondents confirmed a prior diagnosis of benign disease and provided permission to obtain the slides; the other 30 percent did not provide permission or had died shortly after the diagnosis of breast cancer. We were able to obtain slides for 49 percent of the women who provided consent. Slides were not available for the other 51 percent because the hospital no longer existed, the slides had not been kept, or the policy of the pathology department was not to release pathological material of any kind. Although the overall rate of success in obtaining slides was low (34 percent), the rate did not differ significantly between women who had a subsequent diagnosis of breast cancer and those who did not. For 16 of the participants, the submitted slides contained no breast tissue, and these women were excluded from subsequent analyses. Reports on earlier stages of this ongoing, nested case-control study provide detailed descriptions of case ascertainment and review of biopsy specimens from 1976 through 1988.^{2,4} For the present analysis, we reviewed biopsy specimens from 1396 women.

Histologic Examination

Each biopsy specimen was initially evaluated by one of us without knowledge of whether breast cancer subsequently developed. Included in these analyses were 255 women with subsequent breast cancer and 1141 controls whose slides had been reviewed before March 1997. For the purpose of this analysis, breast cancer was defined as invasive carcinoma or ductal carcinoma in situ. For women with bilateral biopsies that confirmed the presence of benign disease in both breasts, the side with the more pronounced histologic abnormalities was used for the purpose of histologic classification. If the two sides showed equally pronounced abnormalities, one was selected randomly.

The benign lesions were initially classified as nonproliferative lesions, proliferative lesions without atypia, or atypical hyperplasia, according to the criteria of Dupont and Page et al.^{1,22} Nonproliferative lesions included unremarkable breast tissue, cysts, ductal ectasia, apocrine metaplasia, and mild ductal hyperplasia; proliferative lesions without atypia included radial scars, intraductal papillomas, sclerosing adenosis, fibroadenomas, and moderate-to-florid ductal hyperplasia; and atypical hyperplasia included ductal and lobular types.^{1,22} In keeping with the evidence that women with fibroadenomas have a higher risk of breast cancer than women without these lesions,⁶ fibroadenomas and fibroadenomatous changes were classified as proliferative lesions without atypia. Biopsy specimens showing possible or definite atypical hyperplasia were subsequently reviewed jointly by two of us, and a consensus on the classification was obtained.

A total of 103 women who were considered to have radial scars according to the initial review had slides available for reexamination. Biopsy specimens with equivocal features of radial scars and those with radial scars that showed possible or definite atypia were subsequently reviewed by three of us, and a consensus was obtained. On this subsequent review, radial scars were not identified in four women, and these findings were recoded appropriately. The following additional features were recorded for the bi-

TABLE 1. RELATION BETWEEN RADIAL SCARS AND OTHER RISK FACTORS FOR BREAST CANCER IN WOMEN WITH SUBSEQUENT BREAST CANCER AND CONTROLS.*

COVARIATE†	RADIAL SCARS		NO RADIAL SCARS	
	WOMEN WITH SUBSEQUENT BREAST CANCER (N=32)	CONTROLS (N=67)	WOMEN WITH SUBSEQUENT BREAST CANCER (N=223)	CONTROLS (N=1074)
	no. of women (%)			
Age				
<45 yr	1 (3.1)	3 (4.5)	32 (14.3)	142 (13.2)
45–54 yr	11 (34.4)	21 (31.3)	102 (45.7)	472 (43.9)
≥55 yr	20 (62.5)	43 (64.2)	89 (39.9)	460 (42.8)
Age at menarche				
<13 yr	15 (46.9)	31 (46.3)	105 (47.1)	481 (44.8)
≥13 yr	17 (53.1)	35 (52.2)	115 (51.6)	588 (54.7)
Parity and age at first birth				
Nulliparous	1 (3.1)	4 (6.0)	18 (8.1)	76 (7.1)
Parous				
<25 yr at first birth	12 (37.5)	32 (47.8)	99 (44.4)	543 (50.6)
25–29 yr at first birth	17 (53.1)	26 (38.8)	75 (33.6)	343 (31.9)
≥30 yr at first birth	1 (3.1)	5 (7.5)	28 (12.6)	95 (8.8)
Family history of breast cancer	11 (34.4)	9 (13.4)	33 (14.8)	131 (12.2)
Menopausal status				
Premenopausal	8 (25.0)	16 (23.9)	90 (40.4)	410 (38.2)
Postmenopausal	24 (75.0)	46 (68.7)	109 (48.9)	544 (50.7)
Body-mass index‡				
<25	22 (68.8)	44 (65.7)	163 (73.1)	695 (64.7)
≥25	10 (31.2)	23 (34.3)	60 (26.9)	376 (35.0)

*Numbers may not sum to total numbers, because of missing data for some covariates. In addition, not all covariates are shown.

†For the women with subsequent breast cancer, age was recorded as the age at the time of the diagnosis of cancer; all other covariate information was obtained from the questionnaire preceding the diagnosis. For the matched controls, age was recorded as the age at the end of the corresponding follow-up interval; all other covariate information was obtained from the questionnaire preceding the end of the relevant follow-up interval.

‡The body-mass index was calculated as the weight in kilograms divided by the square of the height in meters.

opsy specimens from the 99 women found to have radial scars on the second review: the number of radial scars and their size and the presence or absence of atypical hyperplasia (ductal or lobular) within the radial scars.

Statistical Analysis

To determine the relative risk of breast cancer associated with radial scars in women with various types of benign breast disease, we performed logistic-regression analyses adjusted for age, the year of the biopsy showing benign breast disease, and other potential confounding factors in order to obtain maximum-likelihood estimates and 95 percent confidence intervals, using the SAS software package.^{23,24} Chi-square analyses were conducted to compare the proportions of women with breast cancer and controls who had radial scars, according to the number and size of the scars.²⁵

Data on covariates were obtained from the biennial questionnaires completed by the study participants from the time of the diagnosis of benign breast disease until the follow-up interval during which breast cancer was diagnosed. In this way, data on covariates were updated as appropriate.

We first examined the prevalence of risk factors for breast cancer among women with and those without radial scars to determine whether there were confounding factors. In keeping with accepted epidemiologic practice, we identified confounding factors on the basis of the magnitude of the association rather than on the basis of statistical significance. The covariates included in the analyses were age at menarche (less than 12, 12, 13, or 14 or

more years), presence or absence of a history of breast cancer in first-degree relatives, body-mass index (categorized according to the quartile distribution in controls), menopausal status (premenopausal, postmenopausal, or uncertain), and parity and age at birth of first child (nulliparous, parous with first birth before the age of 25 years, parous with first birth between the ages of 25 and 29, and parous with first birth at the age of 30 or older). In all models, women with breast cancer and controls were matched for age at the time of the diagnosis of breast cancer, the year of the diagnosis of benign breast disease, and the follow-up interval.

RESULTS

Among the 1396 women with benign breast disease whose biopsy specimens we reviewed, radial scars were identified in 99 (7.1 percent). The relation between radial scars and other risk factors for breast cancer is shown in Table 1. Women with radial scars were older and more likely to be postmenopausal than those without radial scars, and women with radial scars and subsequent breast cancer were more likely to have a family history of breast cancer. There was no relation between the presence of a radial scar and age at menarche, parity, age at birth of first child, or body-mass index.

TABLE 2. SIZE, NUMBER, AND MORPHOLOGIC FEATURES OF RADIAL SCARS.*

CHARACTERISTIC	TOTAL (N=99)	WOMEN WITH SUBSEQUENT BREAST CANCER (N=32)	CONTROLS (N=67)
Size of radial scar — mm†			
Mean	4.5	4.7	4.4
Median	4.0	4.0	4.0
Range	1.5–13.5	1.5–9.5	1.5–13.5
No. of radial scars — no. of women (%)			
1	60 (60.6)	15 (46.9)	45 (67.2)
2	21 (21.2)	8 (25.0)	13 (19.4)
3	4 (4.0)	2 (6.2)	2 (3.0)
4	8 (8.1)	5 (15.6)	3 (4.5)
≥5	6 (6.1)	2 (6.2)	4 (6.0)
Radial scars with atypical hyper- plasia — no. of women (%)	8 (8.1)	4 (12.5)	4 (6.0)
Ductal	6	3	3
Lobular	2	1	1

*Percentages may not sum to 100, because of rounding.

†For women with more than one radial scar, the largest scar was used for the analysis of size.

Most radial scars were incidental microscopical findings, with an overall median size of 4.0 mm (range, 1.5 to 13.5) (Table 2). The mean size of the radial scars was similar in the women with subsequent diagnoses of breast cancer and the controls (mean sizes, 4.7 mm and 4.4 mm, respectively; P=0.58). A single radial scar was present in biopsy specimens from 60.6 percent of the women, two radial scars were present in specimens from 21.2 per-

cent, and three or more scars were present in the remainder of the biopsy specimens. The number of radial scars per biopsy specimen was similar for women with subsequent breast cancer and controls. Atypical hyperplasia was identified within radial scars in biopsy specimens from eight women (six with atypical ductal hyperplasia and two with atypical lobular hyperplasia), with equal numbers among the women with subsequent cancer and the controls (Table 2).

The benign lesions were classified as nonproliferative disease in 65 women with subsequent breast cancer (25.5 percent) and in 453 controls (39.7 percent), proliferative disease without atypia in 129 women with subsequent breast cancer (50.6 percent) and 570 controls (50.0 percent), and atypical hyperplasia in 61 women with subsequent breast cancer (23.9 percent) and 118 controls (10.3 percent) (Table 3). Radial scars were present in 12.5 percent of the women with subsequent breast cancer and 5.9 percent of the controls.

Overall, the presence of a radial scar was associated with almost a doubling of the risk of breast cancer, regardless of the histologic category of benign breast disease (relative risk for women with radial scars as compared with those without radial scars, 1.8; 95 percent confidence interval, 1.1 to 2.9). When the analysis was adjusted for the presence of a radial scar, the relative risk of breast cancer was 1.5 (95 percent confidence interval, 1.1 to 2.1) for women who had proliferative disease without atypia and 3.6 (95 percent confidence interval, 2.4 to 5.6) for those with atypical hyperplasia, in comparison with women who had nonproliferative disease.

The presence of a radial scar further increased the

TABLE 3. RELATIVE RISK OF BREAST CANCER ACCORDING TO HISTOLOGIC CATEGORY OF BENIGN BREAST DISEASE.

HISTOLOGIC CATEGORY	WOMEN WITH SUBSEQUENT BREAST CANCER	CONTROLS	RELATIVE RISK (95% CI)*	ADJUSTED RELATIVE RISK (95% CI)†
	no. of women			
Nonproliferative‡	65	453	1.0	1.0
Proliferative without atypia				
Without radial scars	110	521	1.5 (1.1–2.1)	1.5 (1.1–2.1)
With radial scars	19	49	3.0 (1.7–5.5)	2.7 (1.5–5.0)
Atypical hyperplasia				
Without radial scars	48	100	3.8 (2.4–5.9)	3.7 (2.4–5.9)
With radial scars	13	18	5.8 (2.7–12.7)	5.3 (2.4–11.6)

*These relative risks were adjusted for age, year of biopsy, and follow-up interval. CI denotes confidence interval.

†These relative risks were further adjusted for age at menarche (<12, 12, 13, or ≥14 years), family history of breast cancer (yes or no), body-mass index (in quintiles), menopausal status, and parity and age at birth of first child (nulliparous; parous, <25 years; parous, 25 to 29 years; or parous, ≥30 years). CI denotes confidence interval.

‡Nonproliferative disease was the reference category.

TABLE 4. RISK OF BREAST CANCER ACCORDING TO HISTOLOGIC CATEGORY OF BENIGN BREAST DISEASE AND NUMBER OF RADIAL SCARS.

HISTOLOGIC CATEGORY AND NO. OF RADIAL SCARS	WOMEN WITH SUBSEQUENT BREAST CANCER		RELATIVE RISK (95% CI)*
	BREAST CANCER	CONTROLS	
	no. of women		
Nonproliferative†	65	453	1.0
Proliferative without atypia			
0 scars	110	521	1.5 (1.1–2.1)
1 scar	11	35	2.5 (1.2–5.2)
>1 scar	8	14	4.3 (1.7–10.8)
Atypical hyperplasia			
0 scars	48	100	3.8 (2.4–5.9)
1 scar	4	10	3.5 (1.0–11.7)
>1 scar	9	8	8.4 (3.1–22.9)

*Relative risks were adjusted for age, year of biopsy, and follow-up interval. CI denotes confidence interval.

†Nonproliferative disease was the reference category.

risk of breast cancer among women who had proliferative disease without atypia and those who had atypical hyperplasia, as compared with those who had nonproliferative disease (Table 3). The relative risk of breast cancer for women who had proliferative disease without atypia and who did not have radial scars was 1.5 (95 percent confidence interval, 1.1 to 2.1), whereas the risk for women with radial scars and proliferative lesions without atypia was 3.0 (95 percent confidence interval, 1.7 to 5.5). Thus, among women who had proliferative disease without atypia, the risk of breast cancer was 90 percent greater if radial scars were present than if they were absent (relative risk, 1.9; 95 percent confidence interval, 1.1 to 3.5; $P=0.028$). For women who had atypical hyperplasia without radial scars, the relative risk of breast cancer was 3.8 (95 percent confidence interval, 2.4 to 5.9), whereas for those who had atypical hyperplasia with radial scars, the relative risk was 5.8 (95 percent confidence interval, 2.7 to 12.7). Therefore, among women with atypical hyperplasia, the presence of radial scars increased the risk of subsequent breast cancer by 70 percent (relative risk, 1.7; 95 percent confidence interval, 0.7 to 4.0; $P=0.226$). These relative risks were adjusted for age, year of biopsy of benign breast lesions, and follow-up interval. Adjustment for other known risk factors for breast cancer, including age at menarche, family history of breast cancer, body-mass index, menopausal status, parity, and age at birth of first child, did not substantially alter these associations (Table 3).

When the data were stratified according to the number of radial scars per biopsy specimen, the relative risk of breast cancer among the women with proliferative disease with or without atypia, as com-

TABLE 5. RISK OF BREAST CANCER ACCORDING TO HISTOLOGIC CATEGORY OF BENIGN BREAST DISEASE AND SIZE OF THE LARGEST RADIAL SCAR.

HISTOLOGIC CATEGORY AND SIZE OF RADIAL SCAR	WOMEN WITH SUBSEQUENT BREAST CANCER		RELATIVE RISK (95% CI)*
	BREAST CANCER	CONTROLS	
	no. of women		
Nonproliferative†	65	453	1.0
Proliferative without atypia			
No radial scar	110	521	1.5 (1.1–2.1)
Radial scar			
<4 mm	7	22	2.4 (1.0–6.0)
≥4 mm	12	27	3.5 (1.7–7.3)
Atypical hyperplasia			
No radial scar	48	100	3.8 (2.4–5.9)
Radial scar			
<4 mm	2	8	2.0 (0.4–10.0)
≥4 mm	11	10	8.8 (3.5–22.0)

*Relative risks were adjusted for age, year of biopsy, and follow-up interval. CI denotes confidence interval.

†Nonproliferative disease was the reference category.

pared with those who had nonproliferative disease, increased with the number of radial scars. Among the women who had proliferative disease without atypia and more than one radial scar, the relative risk was 4.3 (95 percent confidence interval, 1.7 to 10.8), and among the women with atypical hyperplasia and more than one radial scar, the relative risk was 8.4 (95 percent confidence interval, 3.1 to 22.9) (Table 4). Similarly, the relative risk of breast cancer increased with the size of the radial scars. Among the women who had proliferative disease without atypia and who had a radial scar that was 4 mm or more in diameter, the relative risk was 3.5 (95 percent confidence interval, 1.7 to 7.3), and among those with atypical hyperplasia and a radial scar that was 4 mm or more in diameter, the relative risk was 8.8 (95 percent confidence interval, 3.5 to 22.0) (Table 5).

Information on the laterality of the initial benign breast disease and subsequent breast cancer was available for 197 women. Overall, cancer developed on the same side as the previous benign disease in 97 (49.2 percent) of these women. Of the 24 women with radial scars, 11 (46 percent) had subsequent cancer in the ipsilateral breast, and 13 (54 percent) had subsequent cancer in the contralateral breast. Of the 16 women who had proliferative disease without atypia and who had radial scars, 8 had subsequent cancer in the ipsilateral breast and 8 had subsequent cancer in the contralateral breast. Of the eight women with atypical hyperplasia and radial scars, three had subsequent cancer in the ipsilateral breast and five had subsequent cancer in the contralateral breast. None of the women with bilateral breast cancer had radial scars as part of their benign breast disease.

DISCUSSION

Prior studies have shown that women with proliferative breast disease, with or without atypia, have a significantly increased risk of breast cancer.^{1-7,26,27} Our results demonstrate that the presence of radial scars almost doubles the risk of breast cancer, regardless of the histologic type of benign breast disease. This risk is further increased in women with larger or multiple radial scars.

The observation that the epithelial elements entrapped in the central zone of fibroelastosis in radial scars may resemble the features of tubular carcinoma^{9,12,13,20,28-31} has led several authors to postulate that radial scars represent an early phase in the development of some breast cancers.⁸⁻¹² The observation that hyaluronic acid levels are similar in radial scars and tubular carcinomas³² has been cited as further evidence in this regard. The presence of invasive or in situ carcinoma in some radial scars¹³⁻¹⁵ has also been cited as evidence of their malignant potential. However, the similar features of radial scars and some carcinomas and the coexistence of in situ or invasive carcinoma within some radial scars, although of interest, do not constitute evidence of a relation between the two types of lesions.

Other authors have compared the frequency of radial scars in women with and those without breast cancer. Wellings and Alpers¹⁶ postulated that radial scars are associated with a risk of cancer on the basis of their finding that women with breast cancer had an increased number of radial scars. Other, similar studies, however, have found no association between the presence of radial scars and breast cancer.¹⁷⁻¹⁹

The potential relation between radial scars and breast cancer postulated in observational reports has until now not been validated by clinical follow-up. The few follow-up studies that have been conducted involved small numbers of patients and lacked suitable controls.^{20,21}

As in previous studies,^{9,17} most of the radial scars in our study were incidental microscopical findings, with a median diameter of 4 mm. There was no statistically significant difference between the mean size of the scars in the women with subsequent breast cancer and the controls, but when the analysis was stratified according to the histologic type of proliferative disease and the size of the radial scar, the risk of breast cancer was greater among the women with larger scars.

Similarly, when the analysis was stratified according to the histologic category of proliferative disease and the number of radial scars, the risk of breast cancer was greater among the women with a larger number of scars. However, because of the small numbers of women in certain strata, the confidence intervals were wide. In a study in which extensive sampling of the whole breast was performed, the number of radial scars was greater in the women

with breast cancer than in those without breast cancer, and this finding was cited as evidence that radial scars are premalignant lesions.¹⁶ In our study, in contrast, the number of radial scars in excisional-biopsy specimens did not differ significantly between the women with subsequent breast cancer and the controls.

Several investigators have reported bilateral and multicentric radial scars,¹⁷⁻¹⁹ with frequencies as high as 43 and 67 percent, respectively.¹⁸ Since our histologic specimens were obtained by excisional biopsy, not mastectomy, multicentricity could not be adequately addressed. In an autopsy study of women who had undergone mastectomy for carcinoma, Nielsen et al.¹⁹ did not find an increased frequency of radial scars in the contralateral breast. Although in our study only limited data were available for an analysis of the laterality of breast cancer in relation to radial scars, we found no significant relation between the presence of radial scars and the subsequent development of cancer in the contralateral breast or the ipsilateral breast. Therefore, radial scars are probably best considered markers of an overall increase in the risk of breast cancer.

We can only speculate about why radial scars are associated with an increased risk of breast cancer. Although the pathogenesis of radial scars in the breast is uncertain, a disturbance in the normal reciprocal interaction between stromal and epithelial cells may be involved. This disturbance, in turn, may reflect a more general perturbation in the interaction between stromal and epithelial cells in the breast, a phenomenon that has been postulated to be important in the pathogenesis of breast cancer.³³

Our findings have implications for pathologists who examine breast-biopsy specimens and for clinicians. The data suggest that pathologists should specifically report the presence of radial scars in benign breast lesions and should note the size of the largest radial scar and the number of such lesions. Patients in whom a breast biopsy reveals one or more radial scars should undergo the same regular clinical and mammographic follow-up recommended for other patients with benign breast lesions associated with a moderately increased risk of breast cancer in either breast. The radial scars evaluated in our study were primarily small, incidentally detected lesions. Whether or not our results can be extrapolated to radial scars large enough to be detected by mammography is an unresolved issue that merits further investigation, particularly in view of the apparent association between larger radial scars and a higher risk of breast cancer in our study population.

Supported by grants (CA 46475, CA 40356, and CA 50385) from the National Institutes of Health.

We are indebted to Maureen Ireland for her extra effort in the collection of slides and data entry for this study.

REFERENCES

1. Dupont WD, Page DL. Risk factors for breast cancer in women with proliferative breast disease. *N Engl J Med* 1985;312:146-51.
2. London SJ, Connolly JL, Schnitt SJ, Colditz GA. A prospective study of benign breast disease and the risk of breast cancer. *JAMA* 1992;267:941-4. [Erratum, *JAMA* 1992;267:1780.]
3. Dupont WD, Parl FF, Hartmann HW, et al. Breast cancer risk associated with proliferative breast disease and atypical hyperplasia. *Cancer* 1993;71:1258-65.
4. Marshall LM, Hunter DJ, Connolly JL, et al. Risk of breast cancer associated with atypical hyperplasia of lobular and ductal types. *Cancer Epidemiol Biomarkers Prev* 1997;6:297-301.
5. Jensen RA, Page DL, Dupont WD, Rogers LW. Invasive breast cancer risk in women with sclerosing adenosis. *Cancer* 1989;64:1977-83.
6. Dupont WD, Page DL, Parl FF, et al. Long-term risk of breast cancer in women with fibroadenoma. *N Engl J Med* 1994;331:10-5.
7. Page DL, Salhany KE, Jensen RA, Dupont WD. Subsequent breast carcinoma risk after biopsy with atypia in a breast papilloma. *Cancer* 1996;78:258-66.
8. Semb C. Pathologico-anatomical and clinical investigations of fibroadenomatous cystica mammae and its relation to other pathological conditions in the mamma, especially cancer. *Acta Chir Scand Suppl* 1928;10:1-484.
9. Fisher ER, Palekar AS, Kotwal N, Lipana N. A nonencapsulated sclerosing lesion of the breast. *Am J Clin Pathol* 1979;71:240-6.
10. Linell F, Ljungberg O, Andersson I. Breast carcinoma: aspects of early stages, progression and related problems. *Acta Pathol Microbiol Scand Suppl* 1980;272:1-233.
11. Fisher ER, Palekar AS, Sass R, Fisher B. Scar cancers: pathologic findings from the National Surgical Adjuvant Breast Project (protocol no. 4) — IX. *Breast Cancer Res Treat* 1983;3:39-59.
12. Andersen JA, Carter D, Linell F. A symposium on sclerosing duct lesions of the breast. *Pathol Annu* 1986;21:145-79.
13. Sloane JP, Mayers MM. Carcinoma and atypical hyperplasia in radial scars and complex sclerosing lesions: importance of lesion size and patient age. *Histopathology* 1993;23:225-31.
14. Frouge C, Tristant H, Guinebretiere JM, et al. Mammographic lesions suggestive of radial scars: microscopic findings in 40 cases. *Radiology* 1995;195:623-5.
15. Douglas-Jones AG, Pace DP. Pathology of R4 spiculated lesions in the breast screening programme. *Histopathology* 1997;30:214-20.
16. Wellings SR, Alpers CE. Subgross pathologic features and incidence of radial scars in the breast. *Hum Pathol* 1984;15:475-9.
17. Anderson TJ, Battersby S. Radial scars of benign and malignant breasts: comparative features and significance. *J Pathol* 1985;147:23-32.
18. Nielsen M, Jensen J, Andersen JA. An autopsy study of radial scar in the female breast. *Histopathology* 1985;9:287-95.
19. Nielsen M, Christensen L, Andersen J. Radial scars in women with breast cancer. *Cancer* 1987;59:1019-25.
20. Fenoglio C, Lattes R. Sclerosing papillary proliferations in the female breast: a benign lesion often mistaken for carcinoma. *Cancer* 1974;33:691-700.
21. Andersen JA, Gram JB. Radial scar in the female breast: a long-term follow-up study of 32 cases. *Cancer* 1984;53:2557-60.
22. Page DL, Dupont WD, Rogers LW, Rados MS. Atypical hyperplastic lesions of the female breast: a long-term follow-up study. *Cancer* 1985;55:2698-708.
23. Breslow NE, Day NE. *Statistical methods in cancer research. Vol. 1. The analysis of case-control studies.* Lyon, France: International Agency for Research on Cancer, 1980. (IARC scientific publications no. 32.)
24. *SAS/STAT user's guide, version 6. Vol. 2.* Cary, N.C.: SAS Institute, 1989.
25. *SAS procedures guide, version 6.* Cary, N.C.: SAS Institute, 1990.
26. Carter CL, Corle DK, Micozzi MS, Schatzkin A, Taylor PR. A prospective study of the development of breast cancer in 16,692 women with benign breast disease. *Am J Epidemiol* 1988;128:467-77.
27. Palli D, Rosselli del Turco M, Simoncini R, Bianchi S. Benign breast disease and breast cancer: a case-control study in a cohort in Italy. *Int J Cancer* 1991;47:703-6.
28. Bloodgood JC. Border-line breast tumors: encapsulated and non-encapsulated cystic adenomata, observed from 1890 to 1931. *Am J Cancer* 1932;16:103-76.
29. Tremblay G, Buell RH, Seemayer TA. Elastosis in benign sclerosing ductal proliferation of the female breast. *Am J Surg Pathol* 1977;1:155-66.
30. Rickert RR, Kalisher L, Hutter RV. Indurative mastopathy: a benign sclerosing lesion of breast with elastosis which may simulate carcinoma. *Cancer* 1981;47:561-71.
31. Weidner N. Benign breast lesions that mimic malignant tumors: analysis of five distinct lesions. *Semin Diagn Pathol* 1990;7:90-101.
32. de la Torre M, Wells AF, Bergh J, Lindgren A. Localization of hyaluronan in normal breast tissue, radial scar, and tubular breast carcinoma. *Hum Pathol* 1993;24:1294-7.
33. Ronnov-Jessen L, Petersen OW, Bissell MJ. Cellular changes involved in conversion of normal to malignant breast: importance of the stromal reaction. *Physiol Rev* 1996;76:69-125.