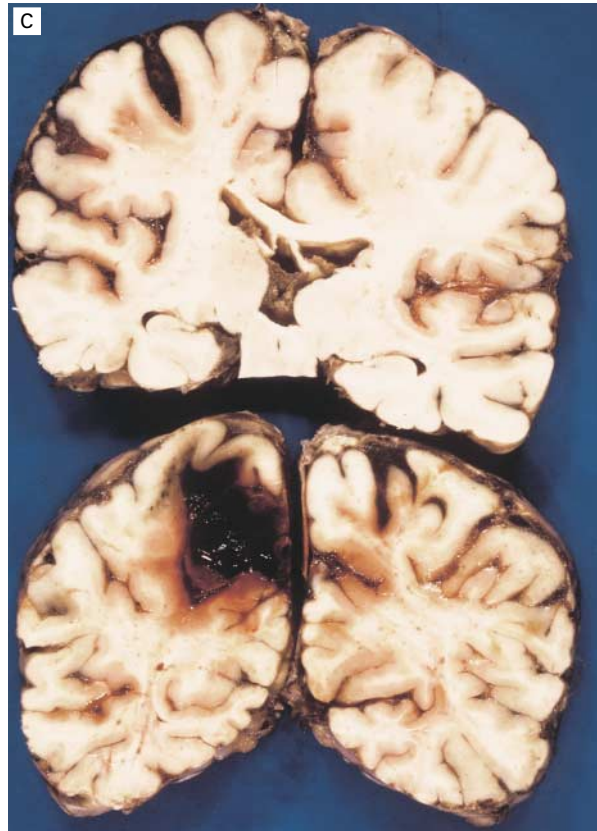
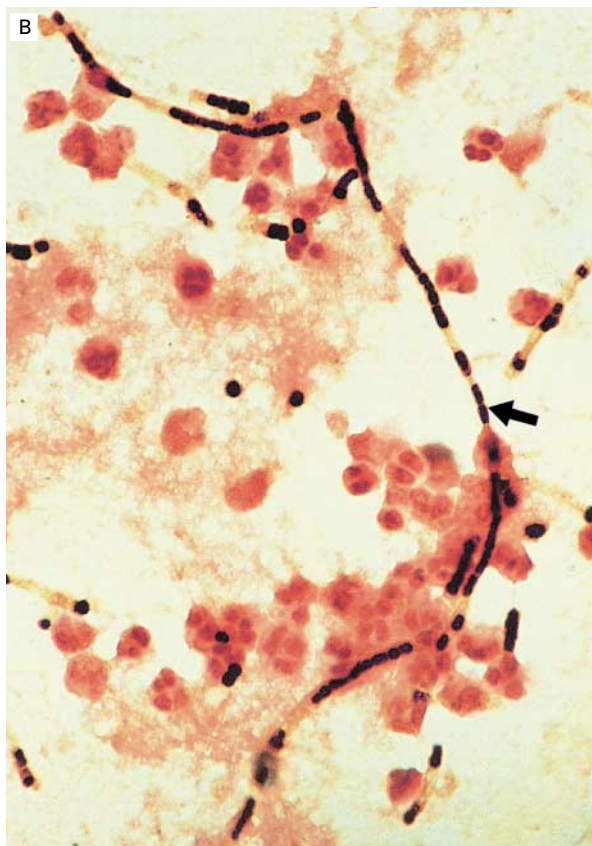
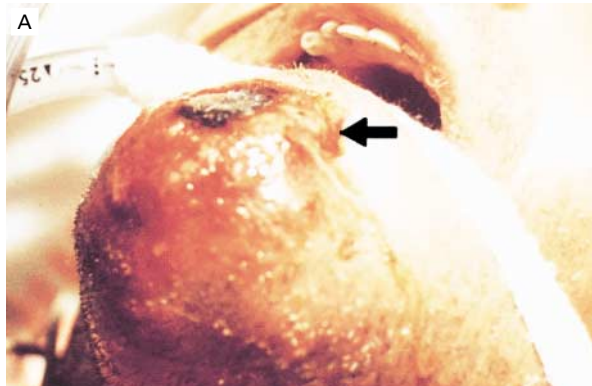



Images in Clinical Medicine



Bacillus anthracis Meningitis

A 49-year-old sheep farmer came to us with a necrotic lesion on his chin, with surrounding gelatinous edema (arrow in Panel A), and a three-day history of obtundation. On examination, he had a temperature of 39°C, a stiff neck, Kernig's sign, generalized hyperreflexia, and bilateral Babinski signs. His left pupil was fixed and dilated. A specimen of cerebrospinal fluid was grossly bloody, and microscopical examination revealed chains of gram-positive bacilli (arrow in Panel B). Cultures of blood and cerebrospinal fluid yielded *Bacillus anthracis*. Treatment was begun with 24 million U of penicillin G per day. One week later, seizures developed, followed by hemiplegia of the

right side. Multisystem failure occurred, and the patient died. Autopsy revealed a left frontal and parietal hematoma and congested leptomeninges (Panel C), with hemorrhagic infiltration by lymphocytes, polymorphonuclear leukocytes, and aggregates of gram-positive bacilli. The walls of the blood vessels were thickened, with areas of necrosis. The lungs showed marked congestion of both lower lobes, with gram-positive bacilli in the exudate.

ASCENSION GONZALEZ GARCIA, M.D.
 RAFAEL RODRIGUEZ JIMENEZ, M.D.
Hospital Universitario Virgen Macarena
 41071 Seville, Spain

©1999, Massachusetts Medical Society.