

## A COMPARISON OF VIRTUAL AND CONVENTIONAL COLONOSCOPY FOR THE DETECTION OF COLORECTAL POLYPS

HELEN M. FENLON, M.B., DAVID P. NUNES, M.B., PAUL C. SCHROY III, M.D., M.P.H., MATTHEW A. BARISH, M.D., PETER D. CLARKE, M.D., AND JOSEPH T. FERRUCCI, M.D.

### ABSTRACT

**Background** Virtual colonoscopy is a new method of imaging the colon in which thin-section, helical computed tomography (CT) is used to generate high-resolution, two-dimensional axial images. Three-dimensional images of the colon simulating those obtained with conventional colonoscopy are then reconstructed off-line. We compared the performance of virtual and conventional colonoscopy for the detection of colorectal polyps.

**Methods** We prospectively studied 100 patients at high risk for colorectal neoplasia (60 men and 40 women; mean age, 62 years). We performed virtual colonoscopy immediately before conventional colonoscopy. We inserted a rectal tube and insufflated the colon with air to the maximal level that the patient could tolerate. We administered 1 mg of glucagon intravenously immediately before CT scanning to minimize the degree of smooth-muscle spasm and peristalsis and to reduce the patient's discomfort.

**Results** The entire colon was clearly seen by virtual colonoscopy in 87 patients and by conventional colonoscopy in 89. Fifty-one patients had normal findings on conventional colonoscopy. In the other 49, we identified a total of 115 polyps and 3 carcinomas. Virtual colonoscopy identified all 3 cancers, 20 of 22 polyps that were 10 mm or more in diameter (91 percent), 33 of 40 that were 6 to 9 mm (82 percent), and 29 of 53 that were 5 mm or smaller (55 percent). There were 19 false positive findings of polyps and no false positive findings of cancer. Of the 69 adenomatous polyps, 46 of the 51 that were 6 mm or more in diameter (90 percent) and 12 of the 18 that were 5 mm or smaller (67 percent) were correctly identified by virtual colonoscopy. Although discomfort was not specifically recorded, none of the patients requested that virtual colonoscopy be stopped because of discomfort or pain.

**Conclusions** In patients at high risk for colorectal neoplasia, virtual and conventional colonoscopy have similar efficacy for the detection of polyps 6 mm or more in diameter. (N Engl J Med 1999;341:1496-503.)  
©1999, Massachusetts Medical Society.

**C**OLORECTAL cancer is the second leading cause of cancer-related death in the United States. A total of approximately 129,000 new cases of carcinoma of the colon will be diagnosed in 1999, and 56,600 patients will die of the disease.<sup>1</sup> Screening and surveillance are cost-effective strategies for reducing both the incidence of and mortality due to colorectal cancer.<sup>2-6</sup> To date, however, implementation of these procedures has been limited, partly because of the lack of an optimal screening strategy that is safe and acceptable to patients and that provides high diagnostic accuracy at low cost.

Virtual colonoscopy is a new method of imaging the colon in which thin-section, helical computed tomography (CT) is used to generate high-resolution, two-dimensional axial images. Three-dimensional images of the colon, simulating those obtained with conventional colonoscopy, are then reconstructed off-line.<sup>7-27</sup> Studies suggest that this technique may be an attractive alternative to existing screening tests for colorectal cancer, since it is relatively safe and minimally invasive. The diagnostic accuracy of virtual colonoscopy remains unknown. We conducted a prospective study of the diagnostic performance of virtual colonoscopy, as compared with conventional colonoscopy performed on the same day, in a group of patients at high risk for colorectal neoplasia.

### METHODS

#### Study Group

Between March 1997 and January 1999, we recruited 100 patients at high risk for colorectal neoplasia (60 men and 40 women; mean age, 62 years; range, 50 to 77 years). Patients were considered to be at high risk if they were 50 years of age or older and if they had a history of adenomatous polyps, recent sigmoidoscopic evidence of one or more polyps, a positive finding on fecal occult-blood testing, or a history of colorectal cancer in one or more first-degree relatives. Exclusion criteria were clinical or radiologic evidence of large-bowel obstruction or ischemia; colonic biopsy or polypectomy within the previous 14 days; retained barium on a scout film; colostomy; a known allergy to glucagon; known glucagonoma, insulinoma, or pheochromocytoma; and pregnancy. Logistical constraints (e.g., scheduling conflicts) and the availability of endoscopy without the requirement of a prior

---

From the Departments of Radiology (H.M.F., M.A.B., P.D.C., J.T.F.) and Gastroenterology (D.P.N., P.C.S.), Boston University School of Medicine, Boston Medical Center, Boston. Address reprint requests to Dr. Barish at the Department of Radiology, Boston University School of Medicine, Boston Medical Center, Boston, MA 02118, or at mbarish@virtualcolonoscopy.net.

consultation precluded the use of a consecutive-enrollment scheme. The study protocol was approved by the institutional review board of the Boston Medical Center, and written informed consent was obtained from all participants.

**Technique**

The patients underwent bowel preparation with either 4 liters of a polyethylene glycol–electrolyte solution or a 48-hour liquid diet combined with two 8-oz (240-ml) doses of magnesium citrate, after which a commercially available bisacodyl and sodium phosphate enema was administered. All virtual colonoscopic examinations were performed immediately before conventional colonoscopy.

Virtual colonoscopic examinations were performed according to a previously described protocol.<sup>13,21-25</sup> A rectal tube was inserted, and the colon was gently insufflated with room air to the maximal level tolerated by the patient. One milligram of glucagon was given immediately before helical CT imaging of the abdomen and pelvis in order to minimize the degree of smooth-muscle spasm and peristalsis and to reduce discomfort. A standard CT scout film of the abdomen and pelvis was acquired to assess the degree of colonic distention, and additional air was insufflated as required.

All CT examinations were performed with the use of a helical CT scanner (model PQ-5000, Picker International, Cleveland). Images were acquired with the use of 5-mm collimation, a table speed of 6.25 mm per second at 110 mA and 110 kV, and a matrix of 512 by 512. Images were obtained during a single breath-holding session when possible in order to visualize the entire colon. Images were reconstructed at 2-mm intervals, with a 3-mm slice overlap. The procedure was first performed with the patient in the supine position and then repeated with the patient in the prone position.

The CT data were downloaded to a workstation (Voxel Q, Picker International) equipped with software for three-dimensional rendering (epi-Scope 3.4 and Voyager 3.4, Picker International). Using this software, a single radiologist, who was unaware of the results of conventional colonoscopy, generated both antegrade and retrograde endoluminal virtual endoscopic navigations of the colon.

**Interpretation**

The axial two-dimensional CT images and endoluminal three-dimensional reconstructions were reviewed by two experienced gastrointestinal radiologists who were unaware of the results of conventional colonoscopy and all previous evaluations, including flexible sigmoidoscopy. Axial CT images, obtained with the patient lying both supine and prone, were viewed at a window level of –1000 Hounsfield units and a window width of 500 Hounsfield units. The endoluminal images were reviewed on a 17-in. (43-cm) monitor (Voxel Q) at a rate of 5 to 30 frames per second. Final interpretations were based on a combined evaluation of the axial CT images and the endoluminal images. The radiologists reviewed the studies jointly and arrived at a consensus.

**Conventional Colonoscopy**

Conventional colonoscopy was performed by an experienced gastroenterologist immediately after virtual colonoscopy, with the use of a standard endoscope (model CFQ-140L, Olympus, Lake Success, N.Y.). The endoscopists were not aware of the results of virtual colonoscopy. In cases in which the conventional colonoscopic examination was incomplete, the endoscopist's best estimate of the depth of inspection was recorded. The location of each lesion was documented, and the size was measured by comparison with an open biopsy forceps.<sup>28</sup>

**Statistical Analysis**

We regarded the results of conventional colonoscopy as the gold standard against which the results of virtual colonoscopy were compared. The results of virtual colonoscopy were analyzed on a per-polyp basis. Analysis included an evaluation of the agreement between the two methods of colonoscopy with respect to both the size and the location of the polyp. For the purpose of

determining location, the colon was divided into six segments: rectum, sigmoid colon, descending colon, transverse colon, ascending colon, and cecum. For a true positive result, the lesion identified on virtual colonoscopy had to have been matched according to location, size, and morphologic features to a lesion found on conventional colonoscopy. In the per-patient evaluation, a result was considered to be truly positive only when at least one polyp identified on virtual colonoscopy was matched to a lesion seen on conventional colonoscopy. All other results were considered to be false positive. The chi-square test was used to determine significant differences.

**RESULTS**

**Conventional Colonoscopy**

Of the 100 patients, 51 had normal findings on conventional colonoscopy. A total of 115 polyps and 3 carcinomas were identified in 49 patients. Fifty-three of the 115 polyps (46 percent) were 1 to 5 mm in diameter, 40 (35 percent) were 6 to 9 mm, and 22 (19 percent) were 10 mm or larger. Of the 115 polyps identified, 101 (88 percent) were successfully removed and examined histologically; 69 were adenomatous and 32 were hyperplastic. Hyperplastic polyps (32 percent of the polyps retrieved) tended to be smaller than adenomatous polyps (P=0.001) and were predominantly on the left side of the colon, whereas adenomatous polyps were more evenly distributed (P=0.02) (Table 1). All three of the adenocarcinomas were sessile; one was located in the sigmoid colon (35 mm), one in the transverse colon (25 mm), and one in the cecum (25 mm).

Eighty-nine percent of the conventional colonoscopic examinations were complete, with visualization to the cecum. Reasons for incomplete colonoscopy included inadequate bowel preparation, tortuosity, and lack of cooperation on the part of the patient. The only documented complication of conventional colonoscopy was a perforation of the sigmoid colon

**TABLE 1. HISTOLOGIC CLASSIFICATION OF 101 RETRIEVED POLYPS ACCORDING TO SIZE AND LOCATION.**

VARIABLE	TOTAL (N=101)	ADENOMATOUS (N=69)	HYPERPLASTIC (N=32)
<b>Size</b>			
1–5 mm	43	18	25*
6–9 mm	36	29	7*
≥10 mm	22	22	0*
<b>Location</b>			
Rectum or sigmoid colon	44	25	19†
Descending colon	25	17	8†
Transverse colon	20	16	4†
Ascending colon or cecum	12	11	1†
Left side of colon	69	42	27‡
Right side of colon	32	27	5‡

\*P=0.001 for the comparison with adenomatous polyps.

†P=0.07 for the comparison with adenomatous polyps.

‡P=0.02 for the comparison with adenomatous polyps.

**TABLE 2. RESULTS OF VIRTUAL COLONOSCOPY AS COMPARED WITH CONVENTIONAL COLONOSCOPY, ACCORDING TO POLYP SIZE AND HISTOLOGIC TYPE.**

VARIABLE	TOTAL	TRUE	FALSE	FALSE	SENSITIVITY
		POSITIVE	NEGATIVE	POSITIVE	
		no. of polyps			%
Size					
All sizes	115	82	33	19	71
≥10 mm	22	20	2	2	91*
6–9 mm	40	33	7	8	82*
1–5 mm	53	29	24	9	55
Histologic type					
All specimens	101	75	26	0	74
Adenomatous					
≥10 mm	22	20	2	0	91
6–9 mm	29	26	3	0	90
1–5 mm	18	12	6	0	67
Hyperplastic					
6–9 mm	7	5	2	0	71†
1–5 mm	25	12	13	0	48†

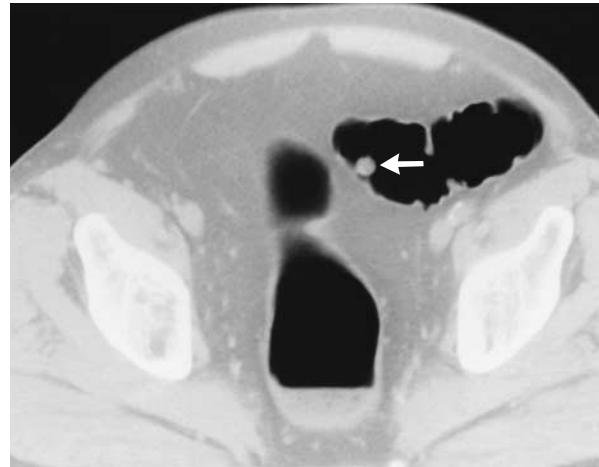
\*P=0.001 for the comparison with polyps of 1 to 5 mm.

†P=0.003 for the comparison with adenomatous polyps of similar size.

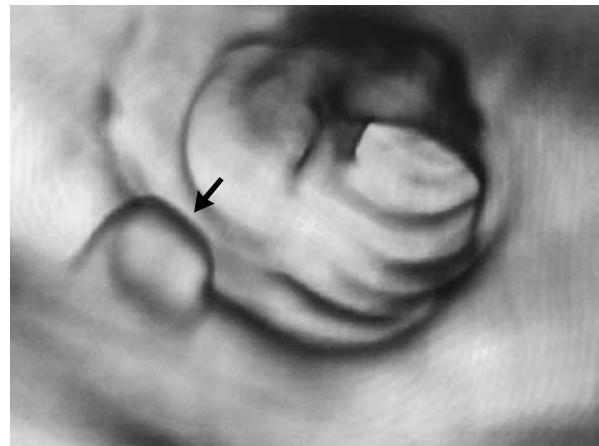in a patient with sigmoid diverticular disease. This patient was admitted to the hospital for observation but did not require surgery.

**Virtual Colonoscopy**

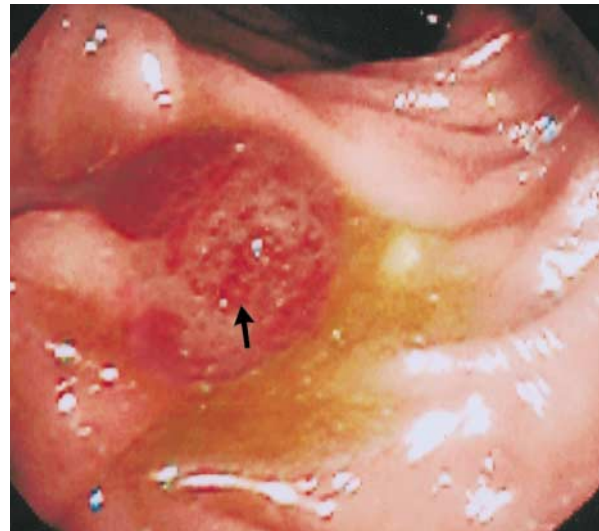
Table 2 shows the performance of virtual colonoscopy for the detection of polyps, according to size and histologic type. Eighty-two of the 115 polyps (71 percent) seen on conventional colonoscopy were correctly identified on the basis of location and size. An example is shown in Figure 1. The sensitivity of virtual colonoscopy was related to the size of the polyp. Only 29 of 53 polyps between 1 and 5 mm in diameter (55 percent) were correctly identified on virtual colonoscopy. The sensitivity for the detection of polyps that were 6 to 9 mm and those that were 10 mm or larger was significantly higher (82 percent and 91 percent, respectively; P=0.001). The performance of virtual colonoscopy was also related to histologic type. The sensitivity of virtual colonoscopy for the detection of hyperplastic polyps 1 to 5 mm in diameter was significantly lower than that for the detection of adenomatous polyps of the same size (48 percent vs. 67 percent, P=0.003). The sensitivity of virtual colonoscopy was 71 percent for the de-



A



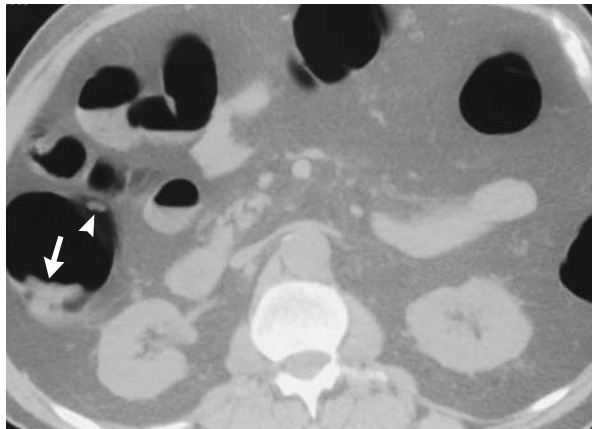
B



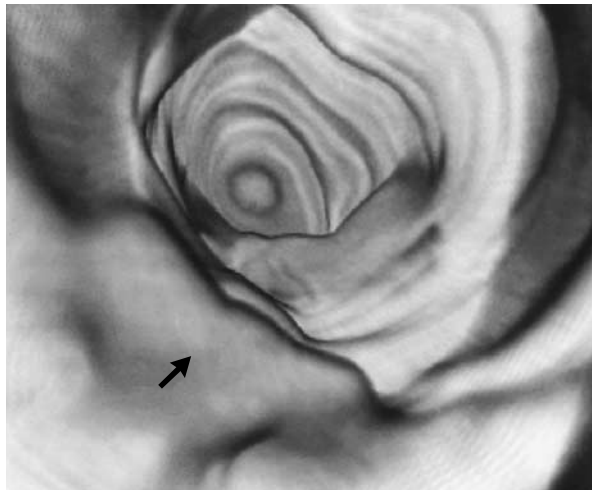
C

**Figure 1. Colorectal Polyp in the Sigmoid Colon.**

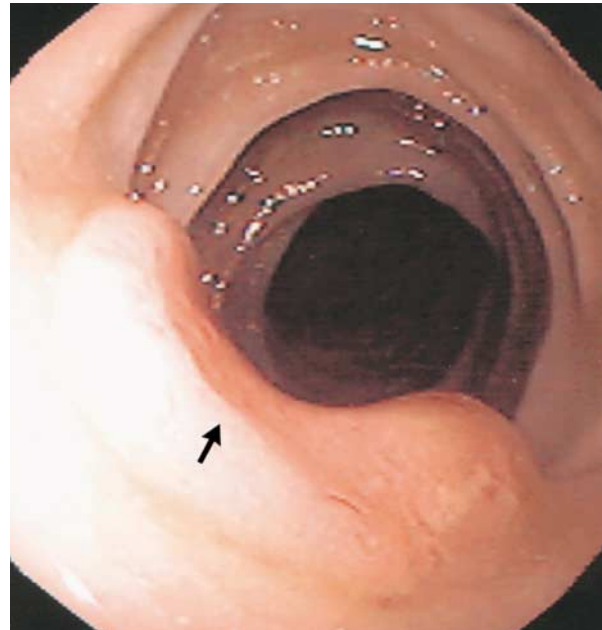
An 8-mm polyp was identified on an axial two-dimensional CT image of the colon (Panel A, arrow) and on an endoluminal three-dimensional reconstruction (Panel B, arrow). The polyp was confirmed on conventional colonoscopy performed the same day (Panel C, arrow). Histologic examination revealed an adenomatous polyp.



A



B



C

**Figure 2. Cecal Carcinoma and Polyp.**

A 25-mm sessile carcinoma was identified on an axial two-dimensional CT image of the cecum (Panel A, arrow). The same image shows a 6-mm polyp on the opposite wall of the cecum (arrowhead). The endoluminal three-dimensional image showed the carcinoma (Panel B, arrow), as well as the polyp (not shown). A normal ileocecal valve was also seen. Conventional colonoscopy performed on the same day confirmed the carcinoma (Panel C, arrow) and the polyp (not shown). Histologic examination of the polyp revealed that it was adenomatous and that the cancer was an adenocarcinoma.

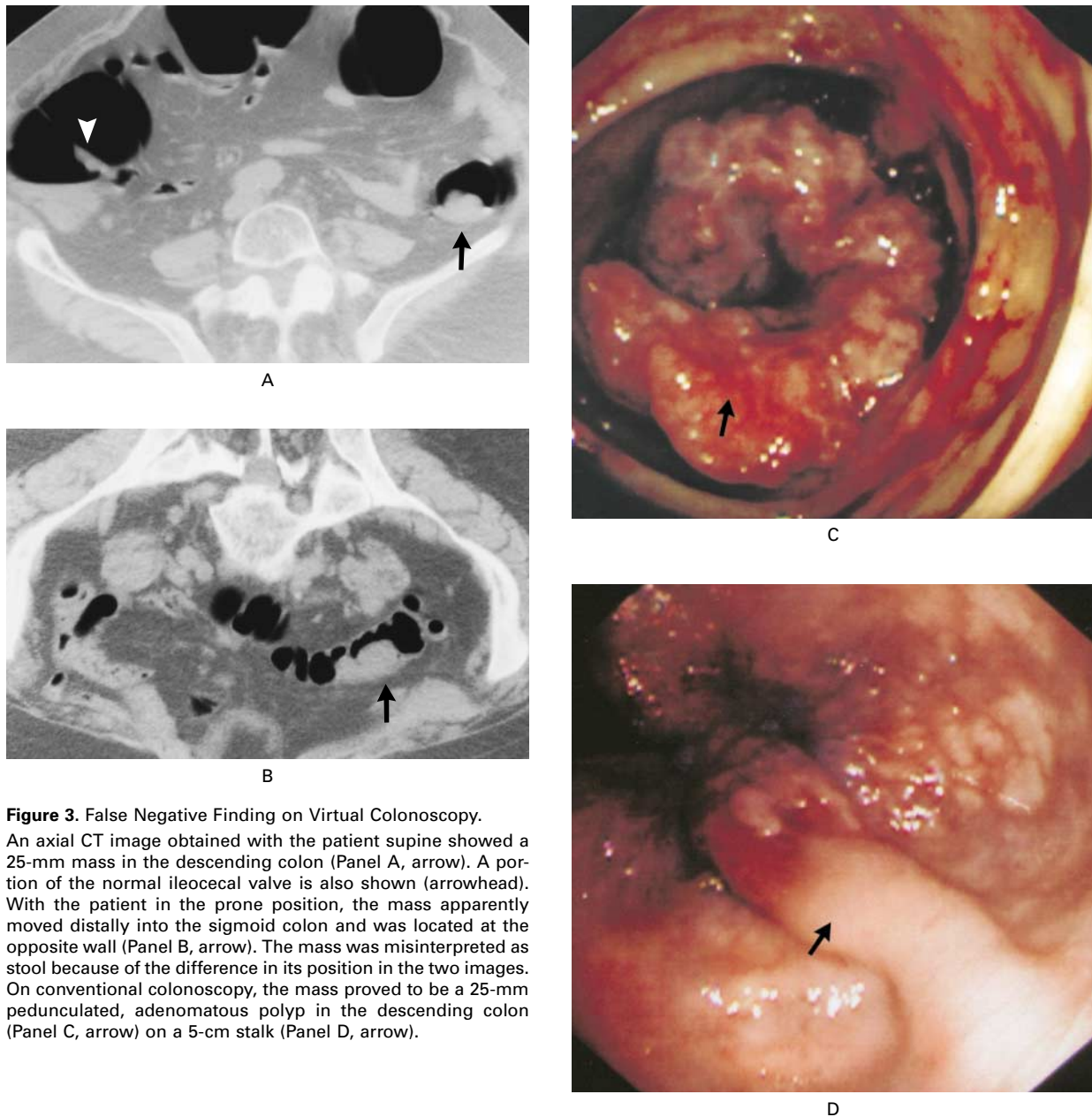
tection of hyperplastic polyps 6 to 9 mm in diameter and 90 percent for adenomatous polyps of the same size. All three cancers were identified on virtual colonoscopy; an example is shown in Figure 2.

There were 19 false positive findings of polyps on virtual colonoscopy; 9 were 1 to 5 mm in diameter, 8 were 6 to 9 mm, and 2 were 10 mm or more (Table 2). Nine of the false positive findings were in segments of colon containing residual solid stool, and eight were in segments of colon (particularly the sigmoid colon) with diverticular disease and poor distention, where thickened and complex haustral folds were misinterpreted as polyps; the other two were in clean, well-distended areas of colon. There were no false positive reports of cancer on virtual colonoscopy.

Of the 33 polyps that were not detected on virtual colonoscopy, 24 (73 percent) were between 1 and 5 mm in diameter. Retrospective analysis of the images did not result in the identification of many of these polyps, despite adequate distention and prep-

aration of the colon. Limited image resolution probably accounts for most of these false negative results. False negative results for the seven polyps that were 6 to 9 mm in diameter and the two that were 10 mm or larger were due to the misinterpretation of polyps as stool (two polyps) or as folds (three) or to inadequate visualization because of retained intraluminal fluid and poor colonic distention (four). Of the two false negative results involving polyps that were 10 mm or more in diameter, one was due to inadequate distention of the sigmoid colon, and the other was due to an error in interpretation. The latter polyp, a 25-mm mass located in the proximal sigmoid colon, was the largest polyp missed (Fig. 3). Although the mass was identified on virtual colonoscopy, the dramatic difference in its position on the two films obtained with the patient in the prone and supine positions was interpreted as indicating the presence of stool rather than a polyp on a very long stalk.

When the results of virtual colonoscopy were an-



**Figure 3.** False Negative Finding on Virtual Colonoscopy.

An axial CT image obtained with the patient supine showed a 25-mm mass in the descending colon (Panel A, arrow). A portion of the normal ileocecal valve is also shown (arrowhead). With the patient in the prone position, the mass apparently moved distally into the sigmoid colon and was located at the opposite wall (Panel B, arrow). The mass was misinterpreted as stool because of the difference in its position in the two images. On conventional colonoscopy, the mass proved to be a 25-mm pedunculated, adenomatous polyp in the descending colon (Panel C, arrow) on a 5-cm stalk (Panel D, arrow).

alyzed on a per-patient basis, the performance was improved. If the detection of polyps of all sizes was regarded as important, the results of 42 virtual colonoscopic examinations would have been classified as true positive results, 41 as true negative results, 8 as false positive results, and 9 as false negative results. Therefore, when polyps of all sizes were included, the per-patient sensitivity of virtual colonoscopy was 82 percent, and the specificity was 84 percent. The positive and negative predictive values were 82 and 84 percent, respectively. The per-patient performance improved as the size of the polyps increased; virtual

colonoscopy had a sensitivity of 94 percent and a specificity of 92 percent for the detection of polyps between 6 and 9 mm in diameter, with positive and negative predictive values of 92 and 94 percent, respectively. At 10 mm, the sensitivity, specificity, and positive and negative predictive values for virtual colonoscopy were each 96 percent. It should be noted that in the per-patient analysis, only lesions that had been matched with polyps seen on conventional colonoscopy were regarded as true positive findings.

The entire colon was clearly seen on virtual colonoscopy in 87 of the 100 patients, as compared with 89

on conventional colonoscopy. In 13 patients, virtual colonoscopic evaluation was incomplete because of a combination of inadequate distention of the colon and retained intraluminal fluid or stool. On average, the time required for virtual colonoscopy was just under 20 minutes for CT scanning, 30 minutes for image manipulation, and 10 minutes for interpretation.

Air insufflation was performed to the maximal level tolerated by the patient. Although discomfort was not specifically recorded, none of the patients requested that the procedure be stopped because of discomfort or pain. The patients who reported discomfort described it as mild bloating or cramping. After the injection of intravenous glucagon, several patients reported nausea.

### DISCUSSION

Since its description in 1994,<sup>7</sup> virtual colonoscopy has emerged as a promising method of colorectal evaluation. Although investigators have used a variety of terms and scanning techniques,<sup>7-12,16-18,22-26</sup> the same basic imaging principles apply: thin-section, helical CT of the air-distended, clean colon, with interpretation of data based on both axial two-dimensional images of the colonic mucosa and computer-generated, three-dimensional, reconstructed images. This technique has been evaluated in *in vitro* studies,<sup>10,11,16,17</sup> in studies of patients with proven carcinoma of the colon,<sup>21,24,25</sup> and in studies of small numbers of patients with colorectal polyps.<sup>8,16</sup> Data from these preliminary studies suggested a sensitivity of more than 75 percent and a specificity of more than 90 percent for large colorectal polyps (those more than 10 mm in diameter) and cancers. These studies also demonstrated several technical advantages of virtual colonoscopy over conventional colonoscopy, including visualization of the colon next to an obstructing lesion<sup>24</sup> and ease of inspection of both antegrade and retrograde sides of haustral folds, resulting in the identification of large lesions missed on endoscopy.<sup>25</sup>

As expected, the performance of virtual colonoscopy was highly dependent on the size of the lesion. As demonstrated in the *in vitro* models, the threshold for the reliable detection of small lesions was approximately 5 mm.<sup>15,17</sup> However, the rate of detection of larger polyps, and adenomatous polyps in particular, was much better and approached the reported rate for the detection of adenomatous polyps 6 mm or larger by conventional colonoscopy.<sup>29</sup> The lower sensitivity for the detection of hyperplastic polyps may reflect the tendency of these polyps to be effaced when the colon is distended with air.<sup>30</sup>

Care must be taken in reporting false positive results with virtual colonoscopy. Although conventional colonoscopy was used as the gold standard in this study, between 10 and 20 percent of colonic polyps and up to 5 percent of colorectal cancers may be missed on conventional colonoscopy.<sup>29,31-33</sup> We have

found that virtual colonoscopy can identify large colonic polyps (adenomas of 5 mm or larger) not seen on initial conventional colonoscopy. Consequently, it is possible that the true specificity and positive predictive value of virtual colonoscopy are higher than those reported here.

As a means of detecting colonic polyps and as a potential screening tool, virtual colonoscopy must be measured against other diagnostic approaches, including fecal occult-blood testing, sigmoidoscopy, and double-contrast barium enema. Because it allows for direct visualization of the entire colon, virtual colonoscopy has advantages over both fecal occult-blood testing<sup>2-4,34-37</sup> and sigmoidoscopy.<sup>38,39</sup> In the only direct comparison to date, virtual colonoscopy was more sensitive than single-contrast barium enema for the detection of polyps.<sup>11</sup> Our data also suggest that virtual colonoscopy is superior to double-contrast barium enema, which has a reported sensitivity of 65 to 75 percent for the detection of polyps larger than 7 mm in patients undergoing surveillance examinations because of a history of colorectal adenomas.<sup>40,41</sup> Furthermore, the results of double-contrast barium enema are highly dependent on the skill of the operator.<sup>42,43</sup> Improvements in the means of acquisition of CT data (multidetector systems) and in software are likely to improve the results of virtual colonoscopy and their reproducibility, in terms of both the quality of the images and the interpretation of the data. Together, these improvements may reduce the cost of the procedure by decreasing the amount of time required for both scanning and three-dimensional reconstruction.

Virtual colonoscopy is relatively simple and is less invasive than conventional colonoscopy. Although full preparation of the colon is required, the procedure takes considerably less time than conventional colonoscopy and does not require sedation. Most patients experience some abdominal discomfort as a result of air insufflation, but the examination may be more acceptable to patients than conventional colonoscopy.<sup>13,44</sup>

An important question is whether the low rate of sensitivity for the detection of polyps between 1 and 5 mm in diameter is acceptable. There is controversy about what constitutes a clinically significant polyp with regard to size.<sup>45-47</sup> Although many would argue for the removal of all adenomatous polyps, whatever their size, the prevalence of polyps less than 10 mm in diameter in people over 50 years of age is high (30 to 50 percent).<sup>3,48</sup> Removal of all such polyps for the prevention of colorectal carcinoma would be a formidable challenge. Moreover, in the subgroup of patients with adenomatous polyps that are 10 mm or smaller, the probability of cancer is low, and the likelihood of any single lesion progressing to cancer is also small.<sup>49</sup> On the basis of these data, Glick et al.<sup>50</sup> have suggested that a policy of identifying and removing only polyps above a specific threshold for size,

as opposed to a policy of universal polypectomy, could result in a similar reduction in mortality but at lower risk and lower cost.

Our study has several limitations. First, the diagnostic accuracy of virtual colonoscopy in this study of high-risk patients may be an overestimation of its performance in persons with average risk. Hence the validity of this technique as a screening test needs to be confirmed. Second, our highly selective patient-recruitment scheme precluded a meaningful assessment of whether patients will find virtual colonoscopy acceptable. Similarly, our study design did not allow us to compare virtual colonoscopy and conventional colonoscopy with respect to tolerance of the procedure, side effects, patients' preference, or cost. Furthermore, we did not address the reproducibility of our results in terms of variability between observers and between centers. Further studies are needed to address each of these limitations before widespread use of virtual colonoscopy can be recommended.

Supported in part by a grant from the Research and Education Fund of the Radiological Society of North America.

## REFERENCES

1. Cancer facts & figures — 1999. Atlanta: American Cancer Society, 1999.
2. Mandel JS, Bond JH, Church TR, et al. Reducing mortality from colorectal cancer by screening for fecal occult blood. *N Engl J Med* 1993; 328:1365-71. [Erratum, *N Engl J Med* 1993;329:672.]
3. Hardcastle JD, Chamberlain JO, Robinson MH, et al. Randomised controlled trial of faecal-occult-blood screening for colorectal cancer. *Lancet* 1996;348:1472-7.
4. Kronborg O, Fenger C, Olsen J, Jorgensen OD, Sondergaard O. Randomised study of screening for colorectal cancer with faecal-occult-blood test. *Lancet* 1996;348:1467-71.
5. Selby JV, Friedman GD, Quesenberry CP Jr, Weiss NS. A case-control study of screening sigmoidoscopy and mortality from colorectal cancer. *N Engl J Med* 1992;326:653-7.
6. Newcomb PA, Norfleet RG, Storer BE, Surawicz TS, Marcus PM. Screening sigmoidoscopy and colorectal cancer mortality. *J Natl Cancer Inst* 1992;84:1572-5.
7. Vining DJ, Gelfand DW, Bechtold RE, Scharling ES, Grishaw EK, Shifrin RY. Technical feasibility of colon imaging with helical CT and virtual reality. *AJR Am J Roentgenol* 1994;162:Suppl:104. abstract.
8. Hara AK, Johnson CD, Reed JE, et al. Detection of colorectal polyps with CT colography: initial assessment of sensitivity and specificity. *Radiology* 1997;205:59-65.
9. Hara AK, Johnson CD, Reed JE, et al. Detection of colorectal polyps by computed tomographic colography: feasibility of a novel technique. *Gastroenterology* 1996;110:284-90.
10. Hara AK, Johnson CD, Reed JE, Ehman RL, Ilstrup DM. Colorectal polyp detection with CT colography: two- versus three-dimensional techniques: work in progress. *Radiology* 1996;200:49-54.
11. Hara AK, Johnson CD, Reed JE, Ahlquist DA, Nelson H, Harmsen WS. Computed tomographic colography (virtual colonoscopy) for polyp detection: early comparison against barium enema. *Gastroenterology* 1997;112:Suppl:A575. abstract.
12. Hara AK, Johnson CD, Reed JE, et al. Reducing data size and radiation dose for CT colography. *AJR Am J Roentgenol* 1997;168:1181-4.
13. Johnson CD, Ahlquist DA. Computed tomography colonography (virtual colonoscopy): a new method for colorectal screening. *Gut* 1999;44: 301-5.
14. Ahlquist DA, Hara AK, Johnson CD. Computed tomographic colography and virtual colonoscopy. *Gastrointest Endosc Clin North Am* 1997; 7:439-52.
15. Dachman AH, Lieberman J, Osnis RB, et al. Small simulated polyps in pig colon: sensitivity of CT virtual colography. *Radiology* 1997;203: 427-30.
16. Dachman AH, Kuniyoshi JK, Boyle CM, et al. CT colonography with three-dimensional problem solving for detection of colonic polyps. *AJR Am J Roentgenol* 1998;171:989-95.
17. Beaulieu CF, Napel S, Daniel BL, et al. Detection of colonic polyps in a phantom model: implications for virtual colonoscopy data acquisition. *J Comput Assist Tomogr* 1998;22:656-63.
18. Rubin GD, Beaulieu CF, Argiro V, et al. Perspective volume rendering of CT and MR images: applications for endoscopic imaging. *Radiology* 1996;199:321-30.
19. Vining DJ. Virtual endoscopy: is it reality? *Radiology* 1996;200:30-1.
20. Fenlon HM, Ferrucci JT. Virtual colonoscopy: what will the issues be? *AJR Am J Roentgenol* 1997;169:453-8.
21. Royster AP, Fenlon HM, Clarke PD, Nunes DP, Ferrucci JT. CT colonoscopy of colorectal neoplasms: two-dimensional and three-dimensional virtual-reality techniques with colonoscopic correlation. *AJR Am J Roentgenol* 1997;169:1237-42.
22. Fenlon HM, Clarke PD, Ferrucci JT. Virtual colonoscopy: imaging features with colonoscopic correlation. *AJR Am J Roentgenol* 1998;170: 1303-9.
23. Royster AP, Gupta AK, Fenlon HM, Ferrucci JT. Virtual colonoscopy: current status and future implications. *Acad Radiol* 1998;5:282-8.
24. Fenlon HM, McAneny DB, Nunes DP, Clarke PD, Ferrucci JT. Occlusive colon carcinoma: virtual colonoscopy in the preoperative evaluation of the proximal colon. *Radiology* 1999;210:423-8.
25. Fenlon HM, Nunes DP, Clarke PD, Ferrucci JT. Colorectal neoplasm detection using virtual colonoscopy: a feasibility study. *Gut* 1998;43:806-11.
26. Vining DJ. Virtual colonoscopy. *Gastrointest Endosc Clin North Am* 1997;7:285-91.
27. Johnson CD, Hara AK, Reed JE. Computed tomographic colonography (virtual colonoscopy): a new method for detecting colorectal neoplasms. *Endoscopy* 1997;29:454-61.
28. Morales TG, Sampliner RE, Garewal HS, Fennerty MB, Aickin M. The difference in colon polyp size before and after removal. *Gastrointest Endosc* 1996;43:25-8.
29. Rex DK, Cutler CS, Lemmel GT, et al. Colonoscopic miss rates of adenomas determined by back-to-back colonoscopies. *Gastroenterology* 1997;112:24-8.
30. Bertoni G, Sassatelli R, Conigliaro R, et al. Visual "disappearing phenomenon" can reliably predict the nonadenomatous nature of rectal and rectosigmoid diminutive polyps at endoscopy. *Gastrointest Endosc* 1994; 40:588-91.
31. Winawer SJ, Zauber AG, Ho MN, et al. Prevention of colorectal cancer by colonoscopic polypectomy. *N Engl J Med* 1993;329:1977-81.
32. Hixson LJ, Fennerty MB, Sampliner RE, McGee D, Garewal H. Prospective study of the frequency and size distribution of polyps missed by colonoscopy. *J Natl Cancer Inst* 1990;82:1769-72.
33. Hixson LJ, Fennerty MB, Sampliner RE, Garewal HS. Prospective blinded trial of the colonoscopic miss-rate of large colorectal polyps. *Gastrointest Endosc* 1991;37:125-7.
34. Williams CB, Hunt RH, Loose H, Riddell RH, Sakai Y, Swarbrick ET. Colonoscopy in the management of colon polyps. *Br J Surg* 1974;61:673-82.
35. Steine S, Stordahl A, Lunde OC, Loken K, Laerum E. Double-contrast barium enema versus colonoscopy in the diagnosis of neoplastic disorders: aspects of decision-making in general practice. *Fam Pract* 1993;10: 288-91.
36. Fork FT. Reliability of routine double contrast examination of the large bowel: a prospective study of 2590 patients. *Gut* 1983;24:672-7.
37. Brady AP, Stevenson GW, Stevenson I. Colorectal cancer overlooked at barium enema examination and colonoscopy: a continuing perceptual problem. *Radiology* 1994;192:373-8.
38. Winawer SJ, Flehinger BJ, Schottenfeld D, Miller DG. Screening for colorectal cancer with fecal occult blood testing and sigmoidoscopy. *J Natl Cancer Inst* 1993;85:1311-8.
39. Lang CA, Ransohoff DE. Fecal occult blood screening for colorectal cancer: is mortality reduced by chance selection for screening colonoscopy? *JAMA* 1994;271:1011-3.
40. Reilly JM, Ballantyne GH, Fleming FX, Zucker KA, Modlin IM. Evaluation of the occult blood test in screening for colorectal neoplasms: a prospective study using flexible endoscopy. *Am Surg* 1990;56:119-23.
41. Ahlquist DA, McGill DB, Fleming JL, et al. Patterns of occult bleeding in asymptomatic colorectal cancer. *Cancer* 1989;63:1826-30.
42. Granqvist S. Distribution of polyps in the large bowel in relation to age: a colonoscopic study. *Scand J Gastroenterol* 1981;16:1025-31.
43. Appel MF. Distribution of malignant polyps in the colon. *Dis Colon Rectum* 1982;25:427-8.
44. Hara A, Johnson CD, Reed JE, et al. Colorectal polyp detection using CT colography: initial assessment of sensitivity and specificity. Presented at the 82nd Scientific Assembly and Annual Meeting of the Radiological Society of North America, Chicago, December 1-6, 1996. abstract.

- 45.** Stryker SJ, Wolff BG, Culp CE, Libbe SD, Ilstrup DM, MacCarty RL. Natural history of untreated colonic polyps. *Gastroenterology* 1987;93:1009-13.
- 46.** Waye JD, Lewis BS, Frankel A, Geller SA. Small colon polyps. *Am J Gastroenterol* 1988;83:120-2.
- 47.** Nusko G, Mansmann U, Partzsch U, et al. Invasive carcinoma in colorectal adenomas: multivariate analysis of patient and adenoma characteristics. *Endoscopy* 1997;29:626-31.
- 48.** Rex DK. Colonoscopy: a review of its yield for cancers and adenomas by indication. *Am J Gastroenterol* 1995;90:353-65.
- 49.** Winawer SJ, Fletcher RH, Miller L, et al. Colorectal cancer screening: clinical guidelines and rationale. *Gastroenterology* 1997;112:594-642. [Errata, *Gastroenterology* 1997;112:1060, 1998;114:625.]
- 50.** Glick S, Wagner JL, Johnson CD. Cost-effectiveness of double-contrast barium enema in screening for colorectal cancer. *AJR Am J Roentgenol* 1998;170:629-36.

**CORRECTION**

**A Comparison of Virtual and Conventional  
Colonoscopy for the Detection of Colorectal Polyps**

A Comparison of Virtual and Conventional Colonoscopy for the Detection of Colorectal Polyps . On page 1500, the sentence that begins four lines from the bottom of the left-hand column should have read, "The positive and negative predictive values were 84 and 82 percent, respectively," not "82 and 84 percent, respectively," as printed.