

## ENTERITIS NECROTICANS (PIGBEL) IN A DIABETIC CHILD

TONI M. PETRILLO, M.D., CONSUELO M. BECK-SAGUÉ, M.D., J. GLENN SONGER, PH.D., CARLOS ABRAMOWSKY, M.D., JAMES D. FORTENBERRY, M.D., LILLIAN MEACHAM, M.D., ANDREW G. DEAN, M.D., M.P.H., HANMIN LEE, M.D., DAWN M. BUESCHEL, B.S., AND STEVEN R. NESHEIM, M.D.

## ABSTRACT

**Background** Enteritis necroticans (pigbel), an often fatal illness characterized by hemorrhagic, inflammatory, or ischemic necrosis of the jejunum, occurs in developing countries but is rare in developed countries, where its occurrence is confined to adults with chronic illnesses. The causative organism of enteritis necroticans is *Clostridium perfringens* type C, an anaerobic gram-positive bacillus.

**Methods** In December 1998, enteritis necroticans developed in a 12-year-old boy with poorly controlled diabetes mellitus after he consumed pig intestines (chitterlings). He presented with hematemesis, abdominal distention, and severe diabetic ketoacidosis with hypotension. At laparotomy, extensive jejunal necrosis required bowel resection, jejunostomy, and ileostomy. Samples were obtained for histopathological examination. Polymerase-chain-reaction (PCR) assay was performed on paraffin-embedded bowel tissue with primers specific for the *cpa* and *cpb* genes, which code for the  $\alpha$  and  $\beta$  toxins produced by *C. perfringens*.

**Results** Histologic examination of resected bowel tissue showed extensive mucosal necrosis, the formation of pseudomembrane, pneumatosis, and areas of epithelial regeneration that alternated with necrotic segments — findings consistent with a diagnosis of enteritis necroticans. Gram's staining showed large gram-positive bacilli whose features were consistent with those of clostridium species. Through PCR amplification, we detected products of the *cpa* and *cpb* genes, which indicated the presence of *C. perfringens* type C. Assay of ileal tissue obtained during surgery to restore the continuity of the patient's bowel was negative for *C. perfringens*.

**Conclusions** The preparation or consumption of chitterlings by diabetic patients and other chronically ill persons can result in potentially life-threatening infectious complications. (N Engl J Med 2000;342:1250-3.)

©2000, Massachusetts Medical Society.

**E**NTERITIS necroticans, an often fatal illness characterized by hemorrhagic, inflammatory, or ischemic necrosis of the jejunum, was first described in northern Germany and Denmark after World War II.<sup>1,2</sup> Most patients had been starved for long periods and then had eaten a voluminous meal. Enteritis necroticans was subsequently recognized in 1961 among children in Papua New Guinea, in whom it often followed a large feast of pork.<sup>3</sup> There it was termed "pigbel," in the dialect of Papua New Guinea, and has been a major public

health problem.<sup>4</sup> The clinical features of enteritis necroticans include abdominal distention and pain and hypotension. At laparotomy, dilated, thickened loops of bowel are found, with segments of necrosis often separated by normal segments of bowel. On histologic examination, necrotic villi and numerous bacteria are seen on the mucosal surface of affected tissue.<sup>5</sup>

The causative organism of enteritis necroticans is *Clostridium perfringens*, an anaerobic gram-positive bacillus. This species is divided into toxicogenic types A, B, C, D, and E on the basis of the production of four major toxins.<sup>6,7</sup> All five types produce  $\alpha$  toxin, which is a hemolytic, necrotizing, lethal phospholipase C. In addition, type B produces  $\beta$  and  $\epsilon$  toxins, type C produces  $\beta$  toxin, type D produces  $\epsilon$  toxin, and type E produces  $\iota$  toxin. Enteritis necroticans is caused by the  $\beta$  toxin produced by type C,<sup>5-8</sup> and immunization against this toxin has resulted in a decline in the incidence of the condition.<sup>4</sup>

Enteritis necroticans is recognized in other developing countries<sup>9-12</sup> and, in rare instances, in developed countries, where its occurrence is confined to adults with chronic illnesses.<sup>13-15</sup> We report here a case of enteritis necroticans in a boy with diabetes after he consumed pig intestines (chitterlings) in the United States.

## CASE REPORT

A 12-year-old boy who had been hospitalized frequently for poorly controlled type 1 diabetes mellitus during the previous two years was transferred to the emergency department of Children's Healthcare of Atlanta at Egleston because of diabetic ketoacidosis with altered mental status. Forty-eight to 72 hours before admission, he had consumed large quantities of food, including chitterlings, in three separate Christmas dinners. He had not traveled outside Atlanta and had had no contact with farm animals.

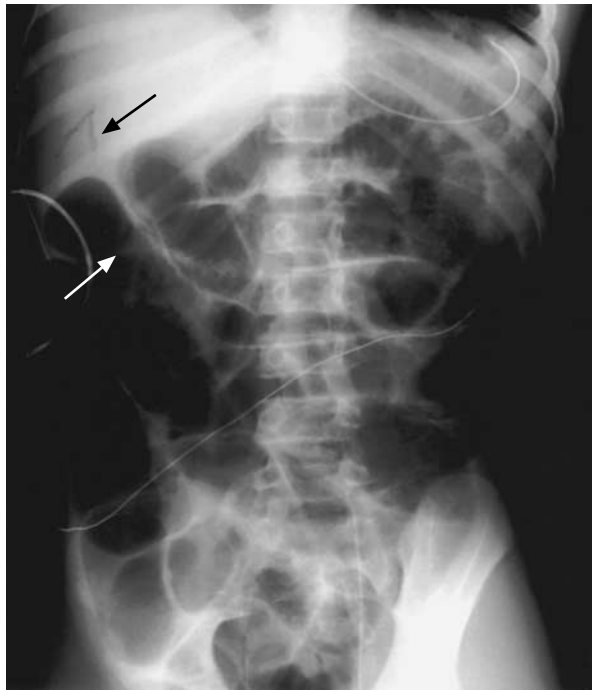
On the day of admission, his mother brought him to another emergency department because of somnolence and hematemesis. His blood glucose concentration was 1500 mg per deciliter (83.3 mmol per liter), the serum sodium concentration was 105 mmol per liter, the serum potassium concentration was 7.9 mmol per liter, the serum bicarbonate concentration was 6 mmol per liter, and the serum creatinine concentration was 5.8 mg per deciliter (513  $\mu$ mol per liter). Arterial-blood gas values were as follows:

From the Divisions of Critical Care Medicine (T.M.P., J.D.E.) and Endocrinology (L.M.), Children's Healthcare of Atlanta at Egleston, Atlanta; the National Center for Infectious Diseases (C.M.B.-S.) and the Epidemiology Program Office (A.G.D.), Centers for Disease Control and Prevention, Atlanta; the Department of Veterinary Science and Microbiology, University of Arizona, Tucson (J.G.S., D.M.B.); and the Divisions of Pediatric Pathology (C.A.), Surgery (H.L.), and Infectious Diseases, Epidemiology, and Immunology (C.M.B.-S., C.A., S.R.N.), Emory University, Atlanta. Address reprint requests to Dr. Petrillo at the Division of Critical Care Medicine, Children's Healthcare of Atlanta at Egleston, 1405 Clifton Rd. NE, 3rd Fl. Annex, Atlanta, GA 30322, or at toni\_petrillo@oz.pcd.emory.edu.

pH, 7.08; partial pressure of carbon dioxide, 19 mm Hg; and partial pressure of oxygen, 175 mm Hg, with a base deficit of 22.7 mmol per liter. The initial white-cell count was 11,300 per cubic millimeter, with 55 percent segmented neutrophils and 24 percent band forms; the hemoglobin concentration was 9.9 g per deciliter, and the platelet count was 242,000 per cubic millimeter. Treatment with intravenous saline and insulin was initiated, and the patient was transferred to Children's Healthcare of Atlanta at Egleston. On arrival, he was confused and combative. His temperature was 34.1°C, the heart rate 118 beats per minute, the respiratory rate 22 breaths per minute, and the blood pressure 66/33 mm Hg. The physical examination revealed dry mucous membranes, an odor of acetone to the breath, and a tender, distended, soft abdomen. His height and weight were 156 cm (approximately the 75th percentile for age) and 39 kg (approximately the 50th percentile for age), respectively. The glycosylated hemoglobin value was 14.1 percent (normal range, 3.0 to 6.2), and the serum transthyretin (prealbumin) concentration was less than 7 mg per deciliter (normal range, 18 to 45).

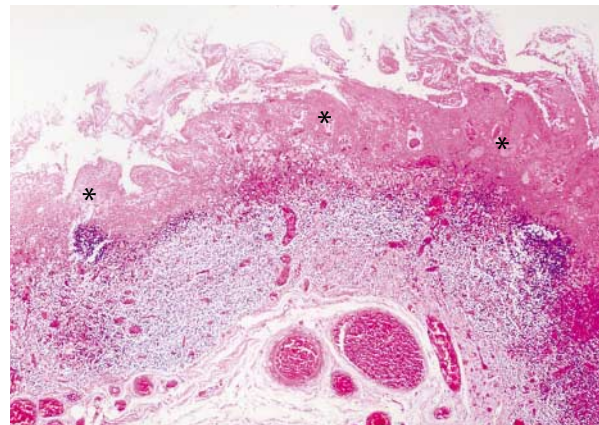
The patient continued to have hematemesis, and his abdominal tenderness increased. In addition to intravenous fluids and insulin, he received cefotaxime, ticarcillin-clavulanate, and clindamycin. Hypotension persisted despite aggressive volume resuscitation; dopamine, norepinephrine, and epinephrine were given to maintain blood pressure. He was intubated for airway protection because of increasing respiratory effort and declining mental status. An abdominal radiograph showed dilated loops of small bowel, with gas in the bowel wall and in the intrahepatic branches of the portal vein (Fig. 1). Exploratory laparotomy revealed bloody ascites and necrotic bowel from the proximal jejunum to the mid-ileum. The necrotic bowel was resected, leaving approximately 2 cm of jejunum and 36 cm of distal ileum. A jejunostomy and an ileostomy were created.

Histologic examination of the resected bowel showed extensive inflammation and necrosis of the mucosa, with areas of pseudomembrane formation and pneumatosis (Fig. 2A). Areas of epithe-

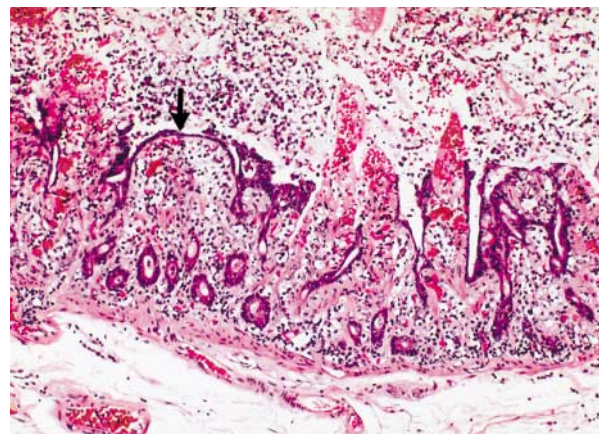


**Figure 1.** Abdominal Radiograph Showing Dilated Loops of Small Bowel.

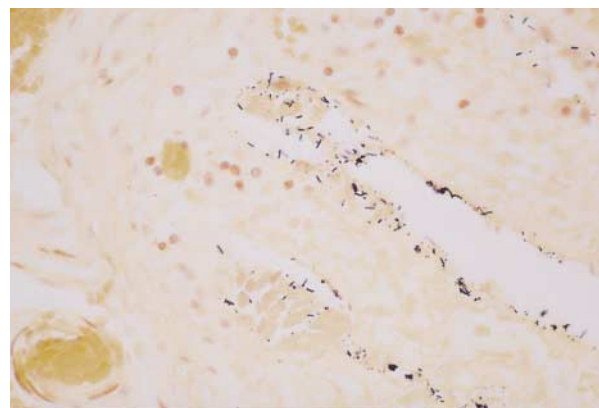
There is gas in the bowel wall (white arrow) and in the intrahepatic branches of the portal vein (black arrow).



A



B



C

**Figure 2.** Photomicrographs of Resected Ileum from the Patient with Enteritis Necroticans.

Panel A shows extensive coagulation necrosis of the intestinal mucosa (asterisks) (hematoxylin and eosin,  $\times 40$ ). Panel B shows more intense inflammation in a pseudomembranous pattern, with evidence of regenerating epithelium (arrow) (hematoxylin and eosin,  $\times 100$ ). Panel C shows many gram-positive bacilli with features consistent with those of clostridium species (Gram's stain,  $\times 400$ ).

lial regeneration alternated with necrotic segments (Fig. 2B). Gram's staining revealed gram-positive bacteria, including large gram-positive bacilli whose features were consistent with those of clostridium species (Fig. 2C); spores were seen at a magnification of 1000. Yeast forms consistent with the presence of candida species were also present. Bowel tissue was not cultured, and cultures of ascitic fluid (aerobic and anaerobic) yielded no growth. Polymerase-chain-reaction (PCR) assay was used to detect *C. perfringens* in paraffin-embedded bowel tissue.<sup>16,17</sup> Primers specific for the *cpa* and *cpb* genes, which code for  $\alpha$  and  $\beta$  toxins, respectively, were used for the detection of these genes; *cpa* is chromosomal and *cpb* is found on a plasmid. Although the  $\beta$  toxin (encoded by the *cpb* gene) is the primary virulent factor associated with enteritis necroticans, a primer pair for the *cpa* gene was included because all isolates of *C. perfringens* produce  $\alpha$  toxin. The amplified products were then separated by electrophoresis in a 1.5 percent agarose gel and stained with ethidium bromide. The assay therefore detected amplification products of *cpa* and *cpb*, indicating the presence of *C. perfringens* type C (Fig. 3).

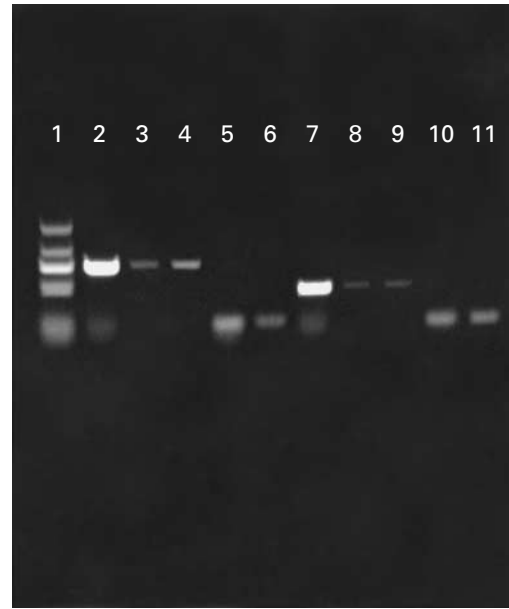The patient had an extended hospital stay, with prolonged parenteral hyperalimentation before he was able to tolerate enteral nutrition. Six weeks after the laparotomy, he underwent surgery to reestablish the continuity of the intestinal tract. PCR assay of tissue obtained from the ileal fistula during the second operation did not show *C. perfringens* (Fig. 3). PCR assay performed on paraffin-embedded bowel tissue that had been resected for another indication from another child was also negative for *C. perfringens* (data not shown).

## DISCUSSION

Cleaned and boiled pig intestines (chitterlings) are part of traditional holiday meals, particularly in the southern United States.<sup>18</sup> During the preparation of chitterlings, the cook and the other foods prepared at the same time may be exposed to the contents of pig bowels. We speculate that this patient ingested *C. perfringens* that produces  $\beta$  toxin, either in the chitterlings or in other foods contaminated during or after preparation of the chitterlings. Chitterlings have also been implicated in enteritis due to *Yersinia enterocolitica*<sup>18</sup> and in salmonella infections.<sup>19</sup>

That the epithelium was regenerating indicated that mucosal injury probably started about 48 to 72 hours before the laparotomy. The finding in the intestinal wall of numerous large gram-positive rods with spores consistent with the presence of clostridium and candida-like organisms on the necrotic mucosal surface suggested a dramatic alteration of the child's intestinal microflora.

The development of enteritis necroticans requires the action of the  $\beta$  toxin of *C. perfringens*. Antibody to the  $\beta$  toxin of *C. perfringens* type C is uncommon among persons from developed countries (less than 15 percent of the population), but high or rising titers are detected in most persons recovering from enteritis necroticans (56 percent to more than 80 percent).<sup>3,5,12,20</sup> However, factors other than this toxin have an important role in the pathogenesis of enteritis necroticans. Among these factors are trypsin inhibitors, which prevent intestinal degradation of the toxin, and reduced intestinal motility, which favors the local accumulation of toxin.<sup>3,5,6</sup> Protein mal-



**Figure 3.** Electrophoresis of DNA Fragments Produced by Polymerase Chain Reaction with the Use of Primers for the *cpa* and *cpb* Genes, Which Encode the  $\alpha$  and  $\beta$  Toxins of *Clostridium perfringens* Type C.

Lane 1 shows standards (from the top, 655, 446, 324, 233, and 196 bp); lane 2 shows amplification of *cpa* in positive control strain 885; lanes 3 and 4 show amplification of *cpa* in a specimen of bowel removed during the patient's first operation; lane 5 shows no amplification of *cpa* in a specimen of bowel removed during surgery six weeks later; lane 6 has no template; lane 7 shows amplification of *cpb* in positive control strain 885; lanes 8 and 9 show amplification of *cpb* in a specimen of bowel removed during the patient's first operation; lane 10 shows no amplification of *cpb* in a specimen of bowel removed at the time of reanastomosis surgery; and lane 11 has no template. The bands at the bottom of lanes 2, 5, 6, 7, 10, and 11 are unused primers.

nutrition, which is associated with decreased activity of trypsin, and the ingestion of sweet potatoes, which contain trypsin inhibitors, have been associated with enteritis necroticans.<sup>3-6</sup>

Factors associated with enteritis necroticans in developed countries include the reduced gastric acidity and gastrointestinal motility associated with some chronic diseases and the frequent consumption of sweet potatoes or other foods that contain trypsin inhibitors<sup>13-15</sup>; one report described a diabetic patient who consumed pork before the onset of hypotension, hematemesis, and abdominal distention.<sup>14</sup>

Our patient was not obviously malnourished, but his glycosylated hemoglobin value indicated that his diabetes had recently been poorly controlled. Poor diabetic control is associated with protein malnutrition,<sup>21</sup> and the patient had a low serum transthyretin concentration, a finding compatible with protein malnutrition. Diabetic patients may have delayed gastric

emptying<sup>22</sup> and reduced intestinal motility,<sup>23,24</sup> which may contribute to the accumulation of toxins and the overgrowth of bacteria.

Cases of acute ischemic intestinal necrosis in patients with diabetic ketoacidosis in the United States have been attributed to mesenteric and portal venous thrombosis or nonocclusive bowel ischemia due to ketoacidosis and hypotension<sup>25,26</sup>; evidence of *C. perfringens* infection was not reported in these cases. This patient's hypotension and hyperosmolar state could have compromised blood flow to the small bowel but are unlikely to have initiated this process. Rather, the history and pathological findings implicate a state of intense infectious injury that lasted about two to three days. The diagnosis of enteritis necroticans was based on the clinical presentation, gross and microscopic lesions, and the presence of *C. perfringens* type C in the bowel. Chronically ill persons, as well as parents of infants, should be informed of the risks of infection related to the preparation and consumption of chitterlings and of the failure of heating to destroy some potential pathogens.<sup>27,28</sup>

*We are indebted to Robert Pettignano, M.D., for his thoughtful review of the manuscript.*

## REFERENCES

- Fick KA, Wolken AP. Necrotic jejunitis. *Lancet* 1949;1:519-21.
- Zeissler J, Rassfeld-Sternberg L. Enteritis necroticans due to *Clostridium welchii* type F. *BMJ* 1949;1:267-9.
- Murrell TGC, Roth L, Egerton J, Samels J, Walker PD. Pig-bel: enteritis necroticans: a study in diagnosis and management. *Lancet* 1966;1:217-22.
- Lawrence GW, Lehmann D, Anian G, et al. Impact of active immunisation against enteritis necroticans in Papua New Guinea. *Lancet* 1990;336:1165-7.
- Cooke RA. Pig Bel. In: Rosenberg HS, Bolande RP, eds. *Perspectives in pediatric pathology*. Vol. 5. New York: Masson Publishing, 1979:137-52.
- Songer JG. Clostridial enteric diseases of domestic animals. *Clin Microbiol Rev* 1996;9:216-34.
- Sterne M, Warrack GH. The types of *Clostridium perfringens*. *J Pathol Bacteriol* 1964;88:279-83.
- Allen SD. Pig-bel and other necrotizing disorders of the gut involving *Clostridium perfringens*. In: Connor DH, Chandler FW, Schwartz DA, Manz HJ, Lack EE, eds. *Pathology of infectious diseases*. Vol. 1. Stamford, Conn.: Appleton & Lange, 1997:717-24.
- Murrell TGC. Enteritis necroticans in Nepal. *Lancet* 1979;1:279.
- Wright DH, Stanfield JP. Enteritis necroticans in Uganda. *J Pediatr* 1967;71:264-8.
- Shann F, Lawrence G, Jun-Di P. Enteritis necroticans in China. *Lancet* 1979;1:1083-4.
- Johnson S, Echeverria P, Taylor DN, et al. Enteritis necroticans among Khmer children at an evacuation site in Thailand. *Lancet* 1987;2:496-500.
- Williams MR, Pullan JM. Necrotizing enteritis following gastric surgery. *Lancet* 1953;2:1013-8.
- Severin WPJ, de la Fuente AA, Stringer ME. *Clostridium perfringens* type C causing necrotizing enteritis. *J Clin Pathol* 1984;37:942-4.
- Farrant JM, Traill Z, Conlon C, et al. Pigbel-like syndrome in a vegetarian in Oxford. *Gut* 1996;39:336-7.
- Songer JG, Meer RR. Genotyping of *Clostridium perfringens* by polymerase chain reaction is a useful adjunct to diagnosis of clostridial enteric disease in animals. *Anaerobe* 1996;2:197-203.
- Meer RR, Songer JG. Multiplex polymerase chain reaction assay for genotyping *Clostridium perfringens*. *Am J Vet Res* 1997;58:702-5.
- Lee LA, Gerber AR, Lonsway DR, et al. *Yersinia enterocolitica* O:3 infections in infants and children, associated with the household preparation of chitterlings. *N Engl J Med* 1990;322:984-7.
- Cornell J, Neal KR. Protracted outbreak of *Salmonella typhimurium* definitive phage type 170 food poisoning related to tripe, 'pig bag,' and chitterlings. *Commun Dis Public Health* 1998;1:28-30.
- Johnson S. Antibody responses to clostridial infections in humans. *Clin Infect Dis* 1997;25:Suppl 2:S173-S177.
- Arbona C, Ascaso JF, Martínez-Valls J, Pérez-Lazaro A, Sanchez C, Carmena R. Malnutrición proteica en la diabetes mellitus insulinodependiente o tipo I: relación con el grado de control metabólico. *Med Clin (Barc)* 1990;95:572-5.
- Cucchiara S, Franzese A, Salvia G, et al. Gastric emptying delay and gastric electrical derangement in IDDM. *Diabetes Care* 1998;21:438-43.
- Camilleri M, Malagelada JR. Abnormal intestinal motility in diabetics with the gastroparesis syndrome. *Eur J Clin Invest* 1984;14:420-7.
- Spengler U, Stellaard F, Ruckdeschel G, Scheurle C, Kruijs W. Small intestinal transit, bacterial growth, and bowel habits in diabetes mellitus. *Pancreas* 1989;4:65-70.
- Chan-Cua S, Jones KL, Lynch FP, Freidenberg GR. Necrosis of the ileum in a diabetic adolescent. *J Pediatr Surg* 1992;27:1236-8.
- Nicol KK, Davis GJ. An unusual complication of diabetes mellitus: the zebra that became a horse. *South Med J* 1997;90:83-5.
- Yersinia enterocolitica* infections during the holidays in black families—Georgia. *MMWR Morb Mortal Wkly Rep* 1990;39:819-21.
- Bien JP. Anticipatory guidance and chitterlings. *J Pediatr* 1998;133:712.