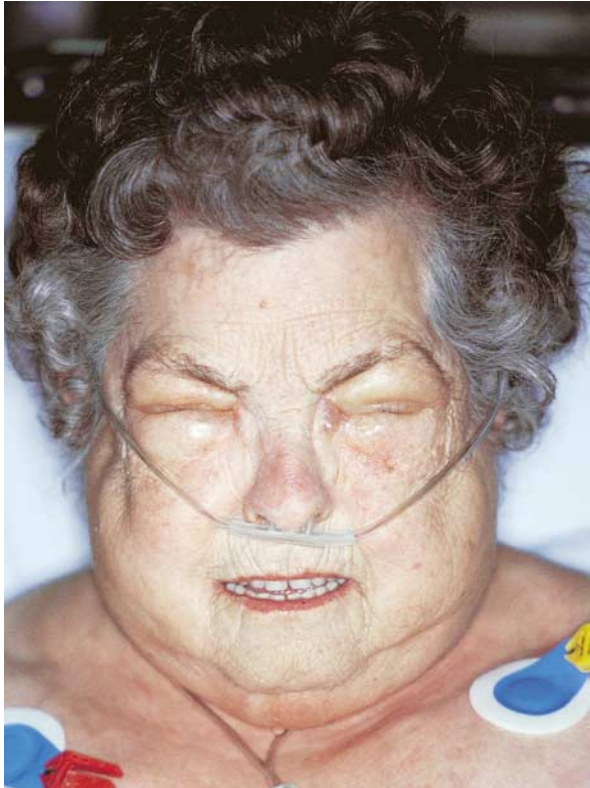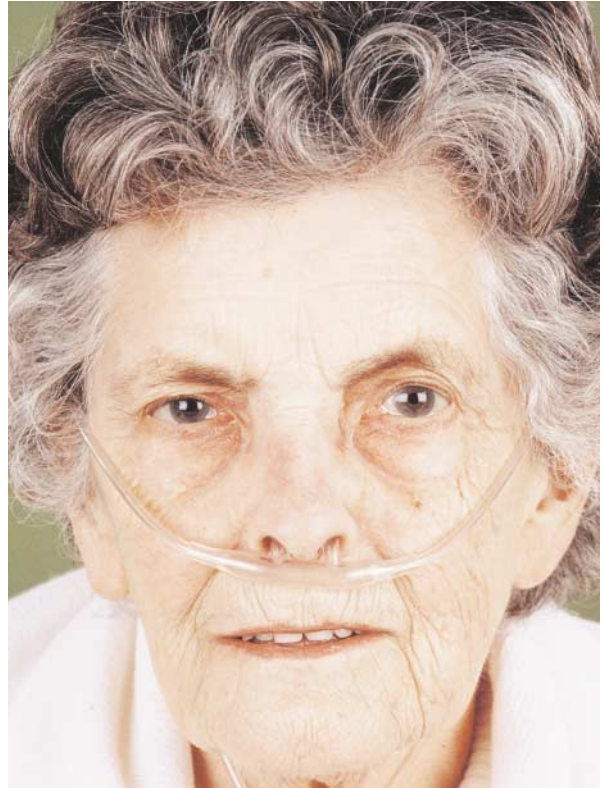




Images in Clinical Medicine



A



B

A Medical Mystery

A 79-year-old woman presented to the emergency department with a several-hour history of facial swelling (Panel A). The photograph shown in Panel B was taken seven days later. What is the diagnosis?

MICHIEL G.H. BETJES, M.D., PH.D.

*Academic Medical Center
1105 AZ Amsterdam, the Netherlands*

©2000, Massachusetts Medical Society.

Editor's note: We invite our readers to offer their opinions by e-mail (mystery@nejm.org) or fax (617-739-9864). We will not be able to acknowledge the receipt of responses. We will publish the diagnosis in the Correspondence section of the March 9 issue. All replies must be received by February 3.