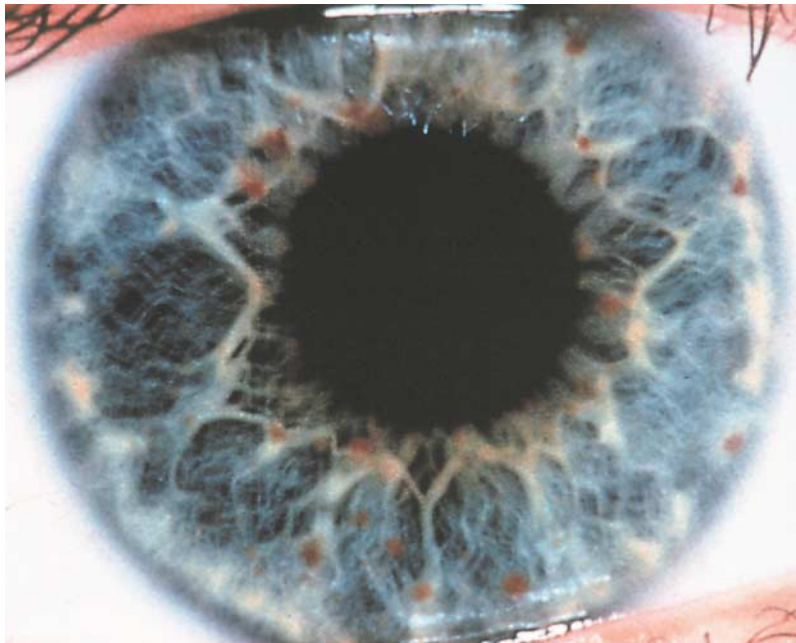
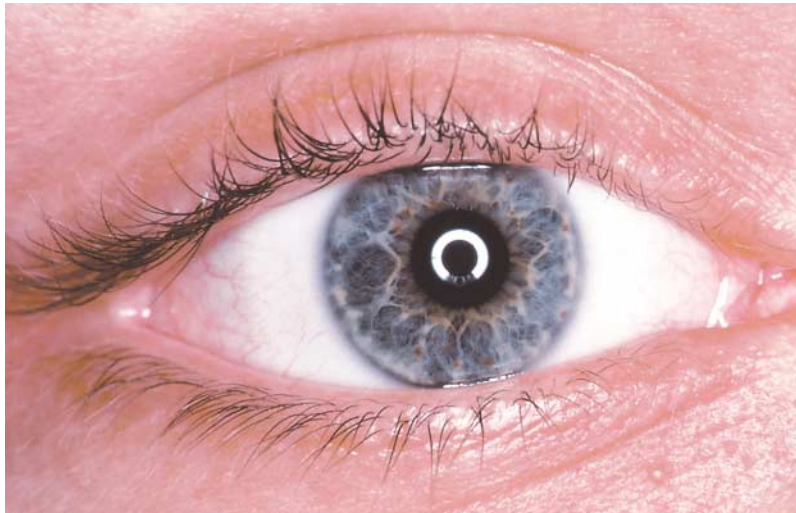




Images in Clinical Medicine



A Medical Mystery

What do these photographs of the eye of a 19-year-old man show, and what systemic disorder does the man have?

GERHARD KURLEMANN, M.D.

OTFRIED DEBUS, M.D.

University of Münster

D-48129 Münster, Germany

©2000, Massachusetts Medical Society.

Editor's note: We invite our readers to offer their opinions by e-mail (mystery@nejm.org) or fax (617-739-9864). We will not be able to acknowledge the receipt of responses. We will publish the diagnosis in the Correspondence section of the November 23, 2000, issue. All replies must be received by October 19, 2000.