

BONE MARROW FAILURE ASSOCIATED WITH HUMAN HERPESVIRUS 8 INFECTION AFTER TRANSPLANTATION

MARIO LUPPI, M.D., PH.D., PATRIZIA BAROZZI, B.Sc., THOMAS F. SCHULZ, M.D., GISELLA SETTI, M.D., KATHERINE STASKUS, PH.D., RAFFAELLA TROVATO, B.Sc., FRANCO NARNI, M.D., AMEDEA DONELLI, M.D., ANTONIO MAIORANA, M.D., ROBERTO MARASCA, M.D., SILVIO SANDRINI, M.D., AND GIUSEPPE TORELLI, M.D.

ABSTRACT

Background Human herpesvirus 8 (HHV-8) infection has been linked to the development of Kaposi's sarcoma and to rare lymphoproliferative disorders.

Methods We used molecular methods, serologic methods, in situ hybridization, and immunohistochemical analyses to study HHV-8 infection in association with nonmalignant illnesses in three patients after transplantation.

Results Primary HHV-8 infections developed in two patients four months after each received a kidney from the same HHV-8-seropositive cadaveric donor. Seropositivity and viremia occurred coincidentally with disseminated Kaposi's sarcoma in one patient and with an acute syndrome of fever, splenomegaly, cytopenia, and marrow failure with plasmacytosis in the other patient. HHV-8 latent nuclear antigen was present in immature progenitor cells from the aplastic marrow of the latter patient. Identification of the highly variable *K1* gene sequence of the HHV-8 genome in both the donor's peripheral-blood cells and the recipients' serum confirmed that transmission had occurred. HHV-8 viremia also occurred after autologous peripheral-blood stem-cell transplantation in an HHV-8-seropositive patient with non-Hodgkin's lymphoma. Reactivation of the infection was associated with the development of fever and marrow aplasia with plasmacytosis; there was no evidence of other infections. HHV-8 transcripts and latent nuclear antigen were expressed in the aplastic marrow but not in two normal marrow samples obtained before transplantation.

Conclusions Primary HHV-8 infection and reactivation of infection may be associated with nonneoplastic complications in immunosuppressed patients. (N Engl J Med 2000;343:1378-85.)

©2000, Massachusetts Medical Society.

INFECTION with human herpesvirus 8 (HHV-8) has been implicated in the development of Kaposi's sarcoma, primary effusion lymphoma, and multicentric Castleman's disease of the plasma-cell type.¹⁻⁴ These conditions have been described most frequently in patients infected with the human immunodeficiency virus (HIV), but they have also been reported in transplant recipients, and immunosuppression is thought to be an important cofactor in their pathogenesis.⁵⁻¹³ Whether primary HHV-8 infection, reactivation of infection, or both lead to a

nonneoplastic illness has yet to be determined.¹⁴ We evaluated the course of illness in two patients in whom a primary HHV-8 infection developed after kidney transplantation and one patient who had reactivation of HHV-8 infection after peripheral-blood stem-cell transplantation.

CASE REPORTS

Patient 1

Patient 1 was a 61-year-old Italian man with end-stage renal disease of unknown cause who had been receiving hemodialysis since April 1988. He received a renal allograft from a cadaveric donor in December 1998. The donor was a 67-year-old Italian man who had died of a cerebrovascular accident. Serologic tests for HIV, hepatitis B virus, hepatitis C virus, and cytomegalovirus were negative. The donor's HLA haplotype was A2, A11, B35, B51, DR5, DR6.

Serologic tests showed that Patient 1 was negative for HIV and hepatitis B virus but positive for hepatitis C virus. His HLA haplotype was A1, A2, B35, B51, DR5, DR6. Before transplantation his immunosuppressive regimen consisted of cyclosporine and methylprednisolone, and in March 1999, after transplantation, he received pulsed doses of methylprednisolone because of one episode of rejection. In April 1999 a diagnosis of Kaposi's sarcoma involving the cervical lymph nodes, the tracheobronchial tract, and the gastrointestinal tract was made.

Patient 2

Patient 2 was a 44-year-old Italian man with membranoproliferative glomerulonephritis who received a renal allograft in December 1998 from the same cadaveric donor as Patient 1. Serologic tests were negative for HIV, hepatitis B virus, and hepatitis C virus. His HLA haplotype was A2, A11, B18, B35, DR5, DR6. He received an immunosuppressive regimen that included cyclosporine and methylprednisolone. The graft began to function immediately after transplantation, and serum creatinine levels were normal within two weeks after transplantation. In March 1999 an episode of acute rejection was successfully treated with pulsed doses of methylprednisolone, with partial improvement of renal function (serum creatinine, 2.0 mg per deciliter [177 μ mol per liter]).

On April 20, 1999, the patient presented with a temperature of more than 38°C and splenomegaly. The hemoglobin value was 6.8 g per deciliter, with a reticulocyte count of less than 1 percent; the white-cell count was 3600 per cubic millimeter; and the plate-

From the Department of Medical Sciences, Section of Hematology (M.L., P.B., R.T., F.N., A.D., R.M., G.T.), and the Department of Pathology (A.M.), University of Modena and Reggio Emilia, Modena, Italy; the Department of Medical Microbiology and Genitourinary Medicine, University of Liverpool, Liverpool, United Kingdom (T.F.S.); the Division of Nephrology, University of Brescia, Brescia, Italy (G.S., S.S.); and the Department of Microbiology, University of Minnesota, Minneapolis (K.S.). Address reprint requests to Dr. Torelli at the Department of Medical Sciences, Section of Hematology, Policlinico, Via del Pozzo, 71-41100 Modena, Italy, or at gtorelli@unimo.it.

Another author was Julie Sheldon, B.Sc., Department of Medical Microbiology and Genitourinary Medicine, University of Liverpool, Liverpool, United Kingdom.

let count was 84,000 per cubic millimeter (Fig. 1). The protein level was 5.8 g per deciliter (albumin, 2.2 g per deciliter; gamma globulin, 2.26 g per deciliter), and the serum creatinine level was 1.9 mg per deciliter (168 μ mol per liter). Serum aminotransferase and lactate dehydrogenase levels were normal. Over the next 13 days, the white-cell count declined to 1800 per cubic millimeter and the platelet count declined to 7000 per cubic millimeter (Fig. 1). A core biopsy of bone marrow showed hypocellular bone marrow (cellularity, about 20 percent), with reduced leukopoiesis and erythropoiesis, but with adequate megakaryocytes. Scattered pronormoblasts and dysplastic maturing erythroid precursors with nuclear irregularities were observed. Moderate interstitial plasmacytosis was also present.

There was neither Kaposi's sarcoma nor lymphomatous infiltration of the bone marrow. No signs of disseminated intravascular coagulation or hemolysis were detected. Routine cultures of blood, urine, and bronchoalveolar-lavage fluid and serologic tests for common bacterial, fungal, and viral pathogens were negative. No evidence of herpesviruses (types 1 and 2, varicella-zoster virus, Epstein-Barr virus, HHV-6, HHV-7, and cytomegalovirus), parvovirus B19, or hepatitis A, B, C, or G virus DNA or RNA was detected either in the serum or in the bone marrow. A computed tomographic scan of the chest and abdomen revealed only enlargement of the spleen (length, 16 cm).

Broad-spectrum antibiotics, antiviral agents (acyclovir and ganciclovir), granulocyte colony-stimulating factor, epoetin, and transfusions of platelets and red cells were administered (Fig. 1). Intermittent fever (temperature, 38° to 39°C), anemia, and thrombocytopenia persisted, despite therapy, while the white-cell count improved. Renal function progressively deteriorated (serum creatinine, 3.6 mg per deciliter [318 μ mol per liter]) until the patient died of cardiac and renal failure approximately one month later. Histologic examination at autopsy revealed neither Kaposi's sarcoma nor lymphomatous infiltration of any organs.

Patient 3

Patient 3 was a 63-year-old man in whom non-Hodgkin's lymphoma (the peripheral T-cell type) developed in September 1997 that involved bilateral laterocervical, supraclavicular, axillary, and inguinal lymph nodes and parotid glands. The results of bone marrow biopsies, performed in December 1997 and February 1998, were normal. Lymphoma progressed despite chemotherapy with cyclophosphamide, doxorubicin, vincristine, and prednisone. The patient then received high-dose sequential therapy with cyclophosphamide, methotrexate, etoposide, mitoxantrone, and melphalan, followed by autologous peripheral-blood stem-cell transplantation in May 1998. A dose of 11.8×10^6 unmanipulated CD34+ cells per kilogram of body weight was reinfused; the neutrophil count exceeded 500 per cubic millimeter within 13 days, and the platelet count exceeded 20,000 per cubic millimeter within 15 days. Prophylactic treatment with ciprofloxacin, itraconazole, acyclovir, and immune globulin was administered.

Two days after transplantation, the patient presented with an intermittent fever (temperature, >38°C), which lasted six days, and diarrhea, which lasted four days. A core biopsy of bone marrow was performed 62 days after transplantation to evaluate the cytopenia that had developed during the preceding 3 to 4 weeks and had become increasingly severe. The platelet count had declined from 130,000 per cubic millimeter on day 35 to 26,000 per cubic millimeter on day 62, the hemoglobin level had decreased from 10.0 g per deciliter on day 35 to 7.9 g per deciliter on day 62, and the white-cell count had declined from 12,000 per cubic millimeter on day 42 to 3300 per cubic millimeter on day 62 (Fig. 2).

The biopsy showed a severely hypocellular bone marrow (cellularity, about 10 percent), with markedly reduced leukopoiesis, no megakaryocytes, foci of megaloblastoid erythropoiesis, and small clusters of lymphocytes. Moderate interstitial plasmacytosis was also present. There was no lymphomatous infiltration of the bone marrow. There were no signs of disseminated intravascular coagulation or hemolysis. Antiplatelet antibodies were not detected.

On day 77 the platelet count reached a nadir of 8000 per cubic millimeter and the white-cell count dropped to 2000 per cubic millimeter, with an absolute neutrophil count of less than 500 per cubic millimeter. At this time the patient was not receiving myelosuppressive drugs. Serologic tests for herpesvirus (herpes simplex virus types 1 and 2, varicella-zoster virus, Epstein-Barr virus, HHV-6, HHV-7, and cytomegalovirus), parvovirus B19, and hepatitis A, B, C, and G virus DNA or RNA were negative. Treatment with intravenous immune globulin, corticosteroids, and granulocyte colony-stimulating factor was ineffective, and the patient received supportive therapy in the form of platelet and red-cell transfusions.

On day 115, despite persistent peripheral cytopenia, radiotherapy was initiated because of the progression of lymphoma. On day 143, progressive enlargement of multiple lymph nodes, pleural effusion, and lymphomatous ascites developed. The patient died of cardiac failure 151 days after transplantation.

METHODS

Serologic Studies

Serum samples from Patients 2 and 3 were collected several times, before and after transplantation, as indicated in Figures 1 and 2. Serum samples from Patient 1 were collected at the same times as those from Patient 2 (data not shown). The serologic assays have been described elsewhere.¹⁵⁻¹⁷

Histopathological, Immunohistochemical, and in Situ Hybridization Studies

Formalin-fixed and paraffin-embedded bone marrow specimens were obtained from core biopsies in Patient 2 as well as five controls: four patients with hematologic diseases (one with chronic myelogenous leukemia, two with myelodysplastic syndrome, and one with aplastic anemia) and one healthy subject. A nested polymerase-chain-reaction (PCR) assay showed that all biopsy specimens from the controls were negative for HHV-8 DNA. Bone marrow specimens were obtained from core biopsies in Patient 3, fixed with B-5, and embedded in paraffin.

Immunohistochemical analysis with a polyclonal rabbit antibody against recombinant latent nuclear antigen 1 (latency-associated nuclear antigen 1, or LANA) of HHV-8 encoded by open-reading-frame 73 (ORF 73)^{18,19} was performed at a dilution of 1:500 in phosphate-buffered saline in the biopsy specimens as well as in a primary-effusion lymphoma cell line (BCBL-1), according to an alkaline phosphatase-anti-alkaline phosphatase technique.

Serial biopsy specimens also underwent hybridization with a riboprobe labeled with sulfur-35 (specific activity approximately 2×10^9 dpm per microgram), generated from an HHV-8-specific T0.7 complementary DNA clone, as described previously.²⁰

Molecular Studies

Nucleic acids were extracted from the same cell-free serum samples²¹ as well as from Ficoll-separated and unseparated peripheral-blood cells and bone marrow.^{22,23} PCR assays for viral sequences have been described elsewhere.²¹⁻³⁰

RESULTS

Donor

Serum obtained from the donor one day before the kidneys were removed was positive for HHV-8 in five serologic assays. Antibodies against latent and lytic HHV-8 antigens were detectable on immunofluorescence assays, and antibodies against three different recombinant proteins, derived from ORF 65, K8.1, and 73, were detectable on enzyme-linked immuno-

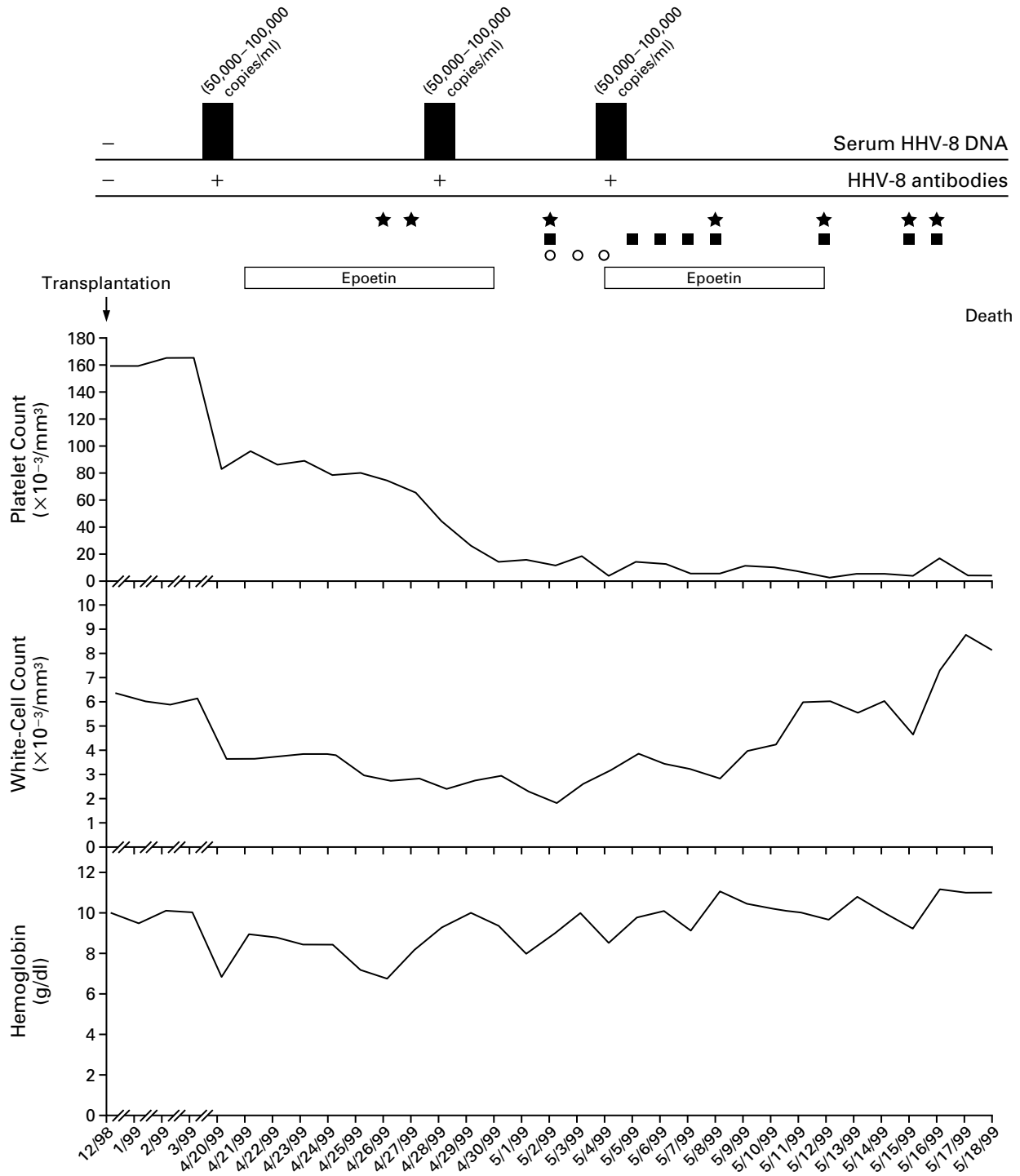


Figure 1. Changes in the Platelet Count, White-Cell Count, Hemoglobin Level, Serum Level of Human Herpesvirus 8 (HHV-8) DNA, and Results of Tests for Antibodies against HHV-8 Antigen in Patient 2 from the Time of Renal Transplantation to Death. Therapy consisted of epoetin, granulocyte colony-stimulating factor (circles), and transfusions of platelets (squares) and red cells (stars).

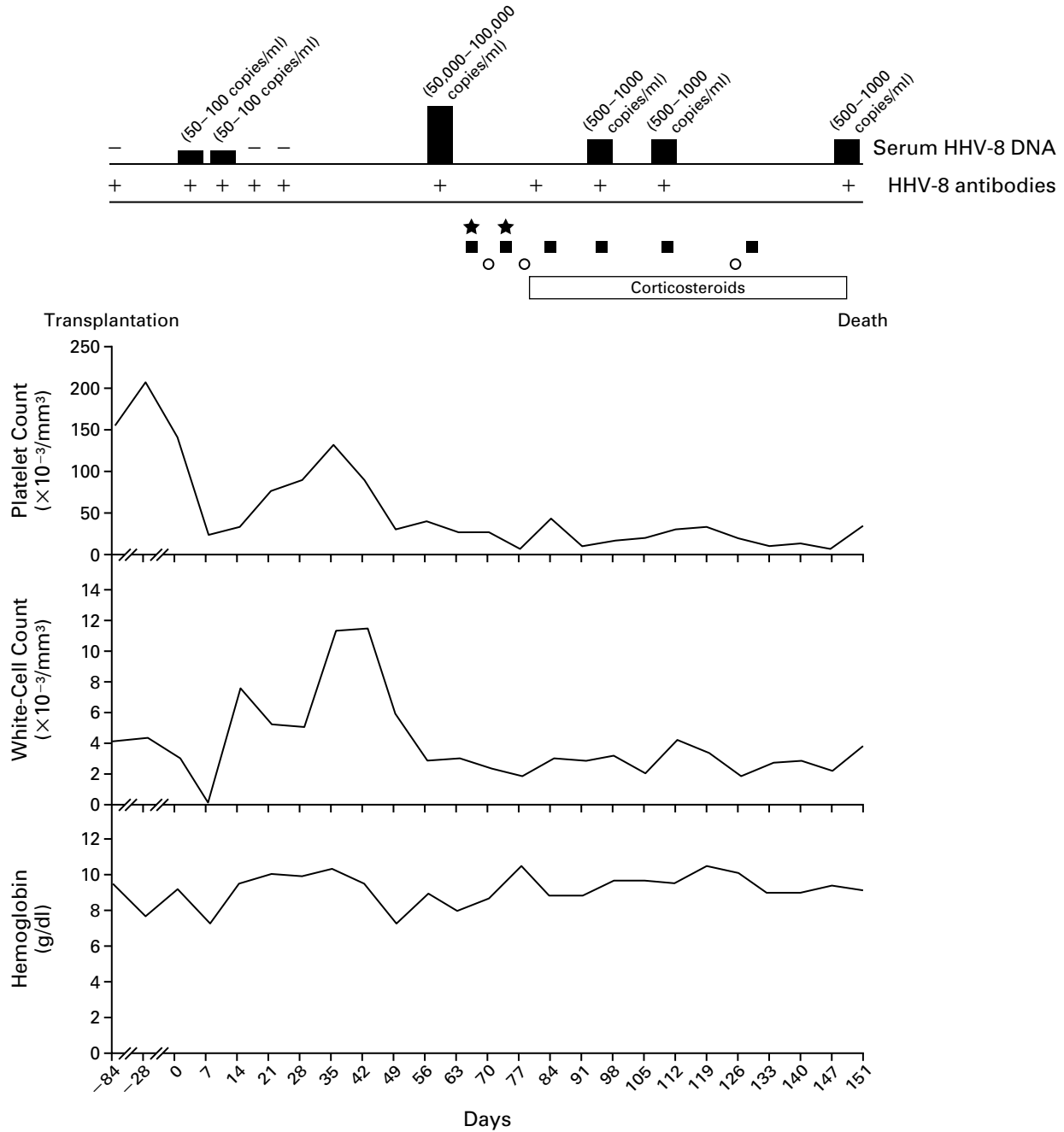


Figure 2. Changes in the Platelet Count, White-Cell Count, Hemoglobin Level, Serum Level of Human Herpesvirus 8 (HHV-8) DNA, and Results of Tests for Antibodies against HHV-8 Antigen in Patient 3 from the Time of the Autologous Peripheral-Blood Stem-Cell Transplantation on Day 0 to Death.

Therapy consisted of corticosteroids, granulocyte colony-stimulating factor (circles), and transfusions of platelets (squares) and red cells (stars). A lytic immunofluorescence assay was used to detect HHV-8 antibodies.

sorbent assay and Western blotting. HHV-8 sequences (ORF 26 and K1) were also detected by a nested PCR assay in the DNA extracted from unseparated peripheral-blood mononuclear cells.

Renal-Transplant Recipients

Serum samples obtained from Patients 1 and 2 at the time of transplantation were negative for HHV-8 in five serologic assays, as were serum samples obtained three months before transplantation in the case of Patient 1 and one month beforehand in the case of Patient 2. The analysis of the first available post-transplantation serum sample, obtained four months after transplantation from Patient 1, at the onset of Kaposi's sarcoma, and from Patient 2 at the onset of symptoms, showed seroconversion. Two subsequent serum samples, obtained one week apart from both patients, were also positive for HHV-8 on all serologic assays used.

HHV-8 DNA (ORF 26 and K1 sequences) was not detectable in serum samples from the two patients at the time of transplantation or before the procedure, but it was detected by PCR assay in the three available serum samples collected after transplantation, both from Patient 1 (50 to 100 copies of HHV-8 DNA per milliliter, as determined semiquantitatively by serial dilutions of DNA from the patient) (data not shown) and from Patient 2 (50,000 to 100,000 copies of HHV-8 DNA per milliliter) (Fig. 1). Sequence analysis of the two highly variable regions of the *K1* gene from these two patients and the donor showed that both the nucleotide and the amino acid sequences were identical, and phylogenetic analysis showed that the infecting strain belonged to clade C, which is rather common in Italy.²⁸ (Additional information is available on our Web site at <http://www.unimo.it/gisl/luppi/nobacknejm.htm>).

HHV-8 LANA was expressed in the nuclei of about 3 percent of the bone marrow cells from Patient 2 (Fig. 3A and 3B). Cells expressing LANA appeared morphologically to be immature bone marrow cells. LANA was present in distinct subnuclear domains in a pattern similar to that seen in cultured primary-effusion lymphoma cell lines (Fig. 3D).¹⁸ No staining with this antibody was seen in bone marrow specimens obtained from core biopsies in the five controls (data not shown).

Recipient of Autologous Peripheral-Blood Stem Cells

HHV-8 DNA (ORF 26 and K1) was transiently detected by a nested PCR assay (50 to 100 copies of HHV-8 DNA per milliliter) in the serum obtained from Patient 3 two days and eight days after transplantation, the period during which he had an intermittent fever, but the levels became undetectable immediately thereafter (Fig. 2). HHV-8 DNA was also undetectable in the serum collected 84 days before transplantation. A PCR assay with degenerate (nonspecific) primers for the DNA polymerase gene of herpesvi-

ruses confirmed the presence of HHV-8 sequences in the patient's serum. HHV-8 DNA (ORF 26 and K1) again became detectable in the serum obtained 62 days after transplantation, and the viral load was high enough (50,000 to 100,000 copies per milliliter) to be detectable even by a one-step PCR assay (Fig. 2). On the basis of the sequencing of the *K1* gene, the HHV-8 variant in this patient was classified as clade A.²⁸

HHV-8 DNA (500 to 1000 copies per milliliter), detected by a nested PCR assay in serial serum samples, persisted concomitantly with the bone marrow aplasia and peripheral cytopenia until the patient died (Fig. 2). HHV-8 DNA sequences were also detected by a nested PCR assay in the DNA extracted from the Ficoll-separated peripheral-blood stem cells collected on day 62 after transplantation. *In situ* hybridization studies also revealed a few HHV-8-infected cells that expressed the latent T0.7 transcript in the aplastic bone marrow obtained on day 62 (Fig. 4). No hybridization signal was detectable in the two histologically normal bone marrow specimens obtained in December 1997 and February 1998 after the diagnosis of non-Hodgkin's lymphoma (Fig. 4). Immunohistochemical analysis also revealed HHV-8 LANA only in the aplastic bone marrow (Fig. 3C). On morphologic examination, HHV-8-positive cells appeared to be immature bone marrow cells. The presence of antibodies against HHV-8 lytic antigens was documented by immunofluorescence assay in the serum obtained 84 days before transplantation and after transplantation, but no antibodies against the latent nuclear antigen or recombinant capsid (ORF 65) or membrane (ORF K8.1) proteins were found.

DISCUSSION

The findings in our three patients show that primary infection with HHV-8 or reactivation of infection may be associated with nonmalignant disease after transplantation. In one renal-transplant recipient, the sudden onset of persistent fever, splenomegaly, and marked cytopenia suggested the presence of an acute infectious disease. Extensive microbiologic testing before the patient's death failed to identify any other agents. Subsequent studies showed seroconversion and high levels of viremia, indicative of a recent primary infection with HHV-8. Our finding of HHV-8 LANA, which is expressed in persistently (latently) infected cells,¹⁸⁻³¹ within immature bone marrow cells strengthens the causal relation between primary HHV-8 infection and the bone marrow failure in this patient.

We also documented the transmission of HHV-8 from a kidney donor to two transplant recipients by showing that seroconversion occurred almost simultaneously in the two transplant recipients and that the *K1* sequences of the HHV-8 DNA were the same in the donor and the two recipients. The *K1* gene of HHV-8 is highly variable and has been used to iden-

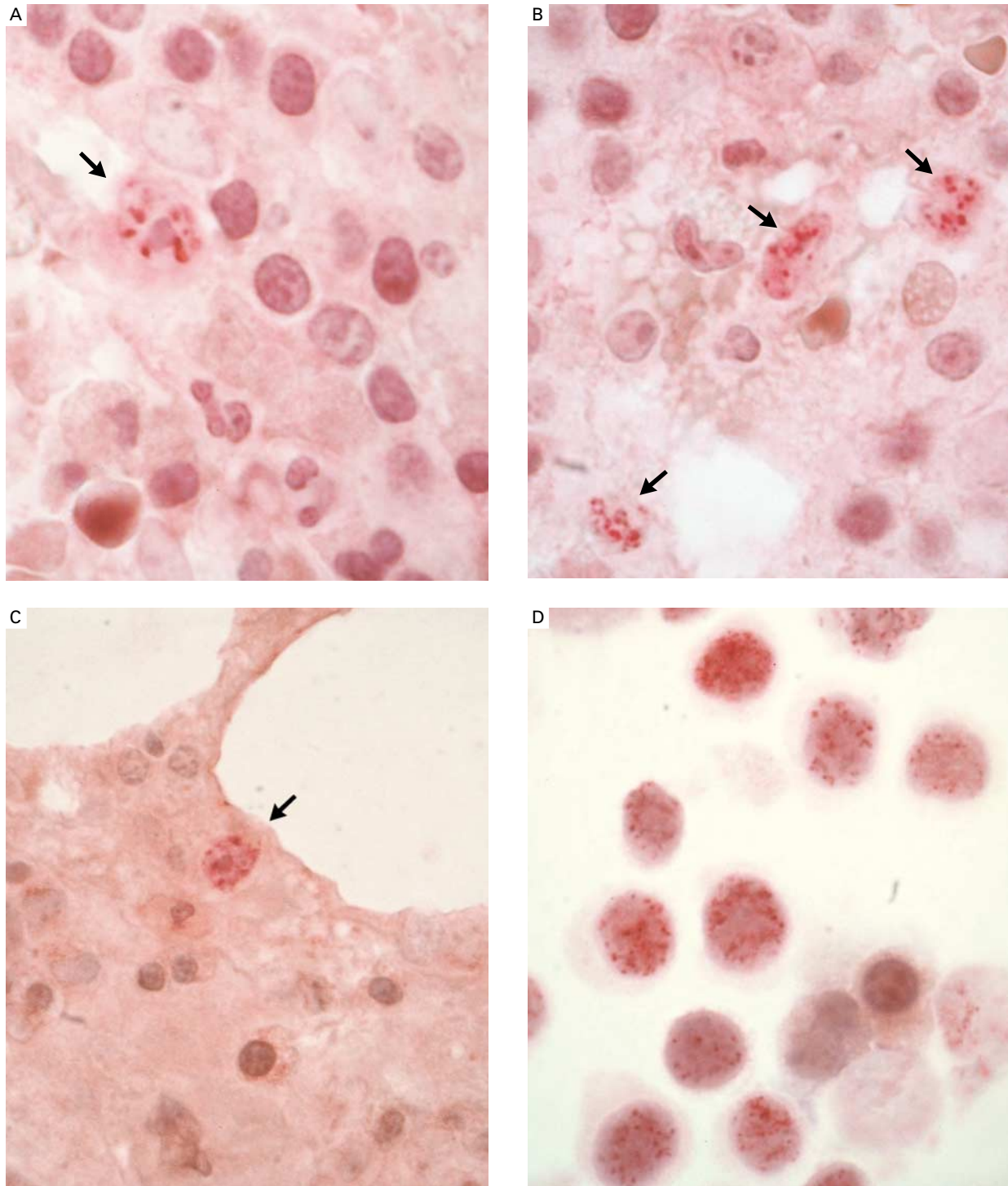


Figure 3. Expression of Human Herpesvirus 8 (HHV-8) Latent Nuclear Antigen in Bone Marrow Cells from Patient 2 (Panels A and B, $\times 450$) and Patient 3 (Panel C, $\times 400$) and an HHV-8–Infected Primary-Effusion Lymphoma Cell Line (Panel D, $\times 500$).

Immunohistochemical analysis was performed with a polyclonal rabbit antibody against recombinant latent nuclear antigen 1 (LANA) of HHV-8 encoded by open-reading-frame 73 (*ORF 73*). Specimens were counterstained with hematoxylin. LANA was detected in the nuclei of immature bone marrow cells (arrows) from Patient 2 four months after kidney transplantation (Panels A and B) and Patient 3 two months after the transplantation of peripheral-blood stem cells (Panel C). The pattern of expression of LANA was similar in the nuclei of the HHV-8–infected BCBL-1 cells (Panel D). There was no staining of bone marrow specimens obtained from core biopsies in five controls or of normocellular bone marrow specimens obtained from core biopsies in Patient 3 in December 1997 and February 1998, before transplantation (not shown).

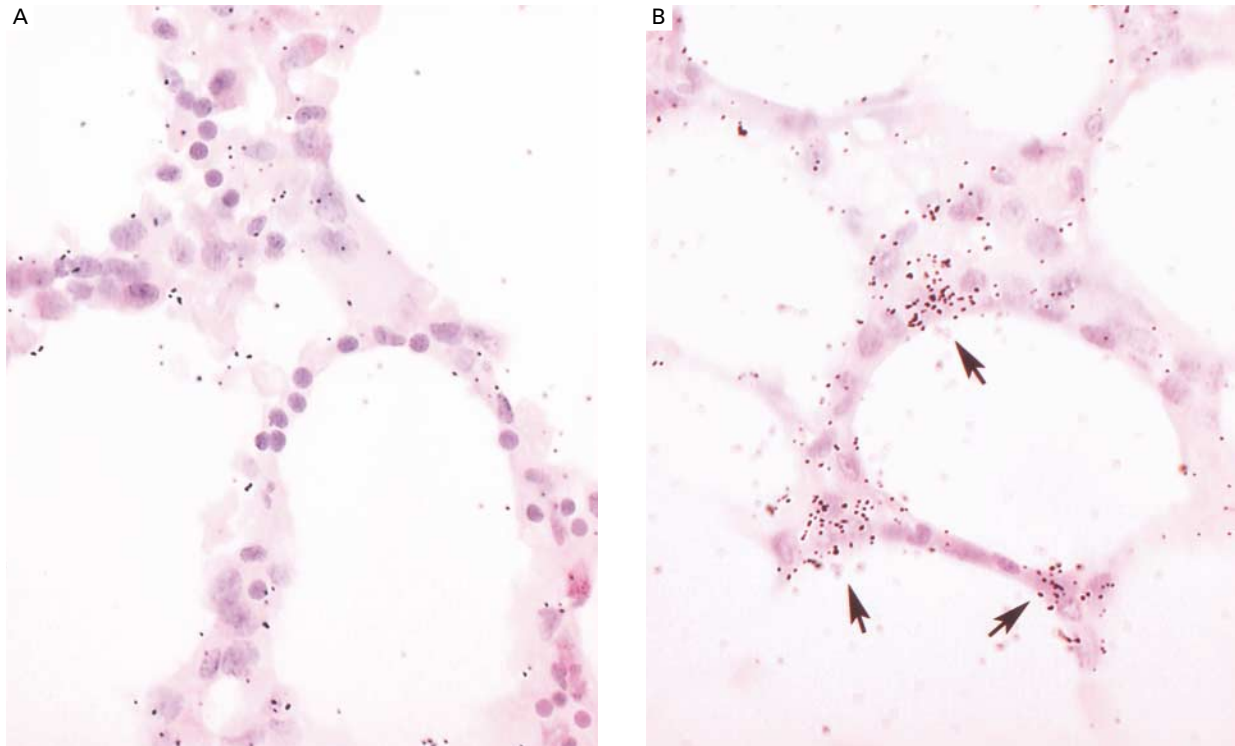


Figure 4. Expression of a Human Herpesvirus 8 (HHV-8) T0.7 RNA Transcript in Serial Core-Biopsy Specimens of Bone Marrow from Patient 3 ($\times 340$).

Specimens were counterstained with hematoxylin and eosin. The results of hybridization with an ^{35}S -labeled riboprobe (specific activity, approximately 2×10^9 dpm per microgram), generated from a T0.7 complementary DNA clone,²⁰ were negative in the normocellular bone marrow specimens obtained from core biopsies in December 1997 (Panel A) and in February 1998 (not shown), before transplantation, whereas a few HHV-8 T0.7 RNA transcripts (arrows in Panel B) are evident in the aplastic bone marrow specimen obtained from a core biopsy in July 1998 (day 62), two months after transplantation.

tify HHV-8 isolates.^{27,28} The simultaneous occurrence of disseminated Kaposi's sarcoma in one renal-transplant recipient and bone marrow failure in the other suggests that the same virus may have a different pathogenic potential in different, although HLA-related, human hosts.

In Patient 3, the detection of antibodies against HHV-8 lytic antigen before transplantation suggests that the viremia was likely to be due to reactivation of the infection rather than to a primary infection with HHV-8. The detection of HHV-8-infected cells by in situ hybridization and immunohistochemical analysis in the aplastic bone marrow, in which plasmacytosis was evident, but not in two previous normal bone marrow specimens from the same patient, suggests that infection of bone marrow cells occurred as a result of viral reactivation and that the virus is myelosuppressive.

Among herpesviruses, Epstein-Barr virus has been implicated in aplastic anemia,³² and cytomegalovirus and HHV-6 have been reported to exert a myelo-

suppressive effect in vitro and to be largely responsible for delayed platelet engraftment in transplant recipients.^{22,33,34} Our findings suggest that HHV-8 can also cause bone marrow failure, at least in immunosuppressed patients after transplantation. The severity of the illness in our patients was most likely related to the immunosuppression and is not typical of a primary infection or a reactivation of infection in immunocompetent subjects. The plasma-cell infiltration in the aplastic bone marrow of these transplant patients may be associated with the HHV-8 infection.^{5,7,8,35}

Kaposi's sarcoma is very rare after the transplantation of allogeneic or autologous bone marrow or peripheral-blood stem cells.³⁶ However, we found that other complications associated with HHV-8 infection may occur occasionally in such patients, at least in our geographic area (the lower Po valley of northern Italy), where the seroprevalence of HHV-8 infection among blood donors is about 13 percent.^{37,38} The identification of a serologic response to HHV-8 in Patient 3 by the lytic immunofluorescence assay but not by the

three other assays illustrates the drawbacks of relying on a single antibody assay to identify HHV-8 infection in HIV-negative patients without Kaposi's sarcoma.^{16,39}

Supported by a grant from the Associazione Italiana per la Ricerca sul Cancro, Milan, Italy (to Dr. Luppi); funds from the Associazione Angela Serra, Modena, Italy (to Dr. Luppi); funds from the European Concerted Action on HHV-8/KSHV (to Dr. Luppi); a grant (RDO/22/09) from the National Health Service Biomedical Research and Development Fund (to Dr. Schulz); and a grant from the Ministero dell'Università e della Ricerca Scientifica e Tecnologica (to Dr. Torelli).

We are indebted to Prof. Girolamo Sirchia, Transplantation Immunology and Blood Transfusion, Ospedale Maggiore Policlinico, Milan, Italy, for providing serum and peripheral-blood cells from the donor; and to Dr. Giuseppe Longo and Prof. Giovanni Emilia, Department of Medical Sciences, Section of Internal Medicine, Modena, Italy, for helpful discussions.

REFERENCES

- Schulz TF. Kaposi's sarcoma-associated herpesvirus (human herpesvirus-8). *J Gen Virol* 1998;79:1573-91.
- Moore PS, Chang Y. Kaposi's sarcoma (KS), KS-associated herpesvirus, and the criteria for causality in the age of molecular biology. *Am J Epidemiol* 1998;147:217-21.
- Neipel F, Albrecht J-C, Fleckenstein B. Cell-homologous genes in the Kaposi's sarcoma-associated rhadinovirus human herpesvirus 8: determinants of its pathogenicity? *J Virol* 1997;71:4187-92.
- Ganem D. KSHV and Kaposi's sarcoma: the end of the beginning? *Cell* 1997;91:157-60.
- Oksenhendler E, Cazals-Hatem D, Schulz TF, et al. Transient angio-lymphoid hyperplasia and Kaposi's sarcoma after primary infection with human herpesvirus 8 in a patient with human immunodeficiency virus infection. *N Engl J Med* 1998;338:1585-90.
- Parravicini C, Olsen SJ, Capra M, et al. Risk of Kaposi's sarcoma-associated herpes virus transmission from donor allografts among Italian post-transplant Kaposi's sarcoma patients. *Blood* 1997;90:2826-9.
- Matsushima AY, Strauchen JA, Lee G, et al. Posttransplantation plasmacytic proliferations related to Kaposi's sarcoma-associated herpesvirus. *Am J Surg Pathol* 1999;23:1393-400.
- Regamey N, Tamm M, Wernli M, et al. Transmission of human herpesvirus 8 infection from renal-transplant donors to recipients. *N Engl J Med* 1998;339:1358-63.
- Francès C, Mouquet C, Calvez V. Human herpesvirus 8 and renal transplantation. *N Engl J Med* 1999;340:1045.
- Rabkin CS, Shepherd FA. Human herpesvirus 8 and renal transplantation. *N Engl J Med* 1999;340:1045-6.
- Farge D, Lebbe C, Marjanovic Z, et al. Human herpes virus-8 and other risk factors for Kaposi's sarcoma in kidney transplant recipients. *Transplantation* 1999;67:1236-42.
- Jones D, Ballestas ME, Kaye KM, et al. Primary-effusion lymphoma and Kaposi's sarcoma in a cardiac-transplant recipient. *N Engl J Med* 1998;339:444-9.
- Dotti G, Fiocchi R, Motta T, et al. Primary effusion lymphoma after heart transplantation: a new entity associated with human herpesvirus-8. *Leukemia* 1999;13:664-70.
- Ho M. Human herpesvirus-8 — let the transplantation physician beware. *N Engl J Med* 1998;339:1391-2.
- Simpson GR, Schulz TF, Whitby D, et al. Prevalence of Kaposi's sarcoma associated herpesvirus infection measured by antibodies to recombinant capsid protein and latent immunofluorescence antigen. *Lancet* 1996;348:1133-8.
- Rabkin CS, Schulz TF, Whitby D, et al. Interassay correlation of human herpesvirus 8 serologic tests. *J Infect Dis* 1998;178:304-9.
- Raab MS, Albrecht JC, Birkmann A, et al. The immunogenic glycoprotein gp35-37 of human herpesvirus-8 is encoded by open reading frame K8.1. *J Virol* 1998;72:6725-31.
- Rainbow L, Platt GM, Simpson GR, et al. The 222 to 234-kilodalton latent nuclear protein (LNA) of Kaposi's sarcoma-associated herpesvirus (human herpesvirus-8) is encoded by orf73 and is a component of the latency-associated nuclear antigen. *J Virol* 1997;71:5915-21.
- Platt GM, Simpson GR, Mittnacht S, Schulz TF. Latent nuclear antigen of Kaposi's sarcoma-associated herpesvirus interacts with RING3, a homolog of the *Drosophila* female sterile homeotic (*fsb*) gene. *J Virol* 1999;73:9789-95.
- Staskus KA, Zhong W, Gebhard K, et al. Kaposi's sarcoma-associated herpesvirus gene expression in endothelial (spindle) tumor cells. *J Virol* 1997;71:715-9.
- Secchiero P, Carrigan DR, Asano Y, et al. Detection of human herpesvirus 6 in plasma of children with primary infection and immunosuppressed patients by polymerase chain reaction. *J Infect Dis* 1995;171:273-80.
- Wang F-Z, Dahl H, Linde A, Brytting M, Ehrnst A, Ljungman P. Lymphotropic herpesviruses in allogeneic bone marrow transplantation. *Blood* 1996;88:3615-20.
- Farci P, Alter HJ, Shimoda A, et al. Hepatitis C virus-associated fulminant hepatic failure. *N Engl J Med* 1996;335:631-4.
- Cinque P, Vago L, Dahl H, et al. Polymerase chain reaction on cerebrospinal fluid for diagnosis of virus-associated opportunistic diseases of the central nervous system in HIV-infected patients. *AIDS* 1996;10:951-8.
- Kurtzman GJ, Ozawa K, Cohen B, Hanson G, Oseas R, Young NS. Chronic bone marrow failure due to persistent B19 parvovirus infection. *N Engl J Med* 1987;317:287-94.
- Chang Y, Cesarman E, Pessin MS, et al. Identification of herpesvirus-like DNA sequences in AIDS-associated Kaposi's sarcoma. *Science* 1994;266:1865-9.
- Zong J-C, Ciuffo DM, Alcendor DJ, et al. High-level variability in the ORF-K1 membrane protein gene at the left end of the Kaposi's sarcoma-associated herpesvirus genome defines four major virus subtypes and multiple variants or clades in different human populations. *J Virol* 1999;73:4156-70.
- Cook PM, Whitby D, Calabro ML, et al. Variability and evolution of Kaposi's sarcoma-associated herpesvirus in Europe and Africa. *AIDS* 1999;13:1165-76.
- Rose TM, Strand KB, Schultz ER, et al. Identification of two homologs of the Kaposi's sarcoma-associated herpesvirus (human herpesvirus 8) in retroperitoneal fibromatosis of different macaque species. *J Virol* 1997;71:4138-44.
- Luppi M, Barozzi P, Maiorana A, et al. Human herpesvirus-8 DNA sequences in human immunodeficiency virus-negative angioimmunoblastic lymphadenopathy and benign lymphadenopathy with giant germinal center hyperplasia and increased vascularity. *Blood* 1996;87:3903-9.
- Dupin N, Fisher C, Kellam P, et al. Distribution of human herpesvirus-8 latently infected cells in Kaposi's sarcoma, multicentric Castleman's disease, and primary effusion lymphoma. *Proc Natl Acad Sci U S A* 1999;96:4546-51.
- Kurtzman G, Young N. Viruses and bone marrow failure. *Baillieres Clin Haematol* 1989;2:51-67.
- Verdonck LF, de Gast GC, van Heugten HG, Nieuwenhuis HK, Dekker AW. Cytomegalovirus infection causes delayed platelet recovery after bone marrow transplantation. *Blood* 1991;78:844-8.
- Singh N, Carrigan DR. Human herpesvirus-6 in transplantation: an emerging pathogen. *Ann Intern Med* 1996;124:1065-71.
- Abrams DI, Chinn EK, Lewis BJ, Volberding PA, Conant MA, Townsend RM. Hematologic manifestations in homosexual men with Kaposi's sarcoma. *Am J Clin Pathol* 1984;81:13-8.
- Penn I. Kaposi's sarcoma in transplant recipients. *Transplantation* 1997;64:669-73.
- Calabro ML, Sheldon J, Favero A, et al. Seroprevalence of Kaposi's sarcoma-associated herpesvirus/human herpesvirus 8 in several regions of Italy. *J Hum Virol* 1998;1:207-13.
- Whitby D, Luppi M, Barozzi P, Boshoff C, Weiss RA, Torelli G. Human herpesvirus 8 seroprevalence in blood donors and lymphoma patients from different regions of Italy. *J Natl Cancer Inst* 1998;90:395-7.
- Rosenzweig M, Fery N, Bons V, Damaj G, Gluckman E, Gluckman JC. Human herpesvirus 8 (HHV8) serology in allogeneic bone marrow transplant recipients. *Bone Marrow Transplant* 1999;24:351-4.