

## THE USE OF CONTRAST-ENHANCED MAGNETIC RESONANCE IMAGING TO IDENTIFY REVERSIBLE MYOCARDIAL DYSFUNCTION

RAYMOND J. KIM, M.D., EDWIN WU, M.D., ALLEN RAFAEL, M.D., ENN-LING CHEN, PH.D., MICHELE A. PARKER, M.S., ORLANDO SIMONETTI, PH.D., FRANCIS J. KLOCKE, M.D., ROBERT O. BONOW, M.D., AND ROBERT M. JUDD, PH.D.

### ABSTRACT

**Background** Recent studies indicate that magnetic resonance imaging (MRI) after the administration of contrast material can be used to distinguish between reversible and irreversible myocardial ischemic injury regardless of the extent of wall motion or the age of the infarct. We hypothesized that the results of contrast-enhanced MRI can be used to predict whether regions of abnormal ventricular contraction will improve after revascularization in patients with coronary artery disease.

**Methods** Gadolinium-enhanced MRI was performed in 50 patients with ventricular dysfunction before they underwent surgical or percutaneous revascularization. The transmural extent of hyperenhanced regions was postulated to represent the transmural extent of non-viable myocardium. The extent of regional contractility at the same locations was determined by cine MRI before and after revascularization in 41 patients.

**Results** Contrast-enhanced MRI showed hyperenhancement of myocardial tissue in 40 of 50 patients before revascularization. In all patients with hyperenhancement the difference in image intensity between hyperenhanced regions and regions without hyperenhancement was more than 6 SD. Before revascularization, 804 of the 2093 myocardial segments analyzed (38 percent) had abnormal contractility, and 694 segments (33 percent) had some areas of hyperenhancement. In an analysis of all 804 dysfunctional segments, the likelihood of improvement in regional contractility after revascularization decreased progressively as the transmural extent of hyperenhancement before revascularization increased ( $P < 0.001$ ). For instance, contractility increased in 256 of 329 segments (78 percent) with no hyperenhancement before revascularization, but in only 1 of 58 segments with hyperenhancement of more than 75 percent of tissue. The percentage of the left ventricle that was both dysfunctional and not hyperenhanced before revascularization was strongly related to the degree of improvement in the global mean wall-motion score ( $P < 0.001$ ) and the ejection fraction ( $P < 0.001$ ) after revascularization.

**Conclusions** Reversible myocardial dysfunction can be identified by contrast-enhanced MRI before coronary revascularization. (N Engl J Med 2000;343:1445-53.)

©2000, Massachusetts Medical Society.

IN patients with coronary artery disease and left ventricular dysfunction, the distinction between reversible and irreversible myocardial injury is important. The identification of viable myocardium is useful in predicting which patients will have increased left ventricular ejection fractions<sup>1-7</sup> and improved survival<sup>8-11</sup> after revascularization. Noninvasive methods for assessing myocardial viability include positron-emission tomography, single-photon-emission computed tomography, and dobutamine echocardiography. These techniques have proven clinical utility, but each has limitations that may reduce its diagnostic accuracy. For example, they interpret myocardial viability as an all-or-none phenomenon within a myocardial region, since none can assess the transmural extent of viability of the ventricular wall.

Magnetic resonance imaging (MRI) with a gadolinium-based contrast agent offers high spatial resolution and can identify acute myocardial infarction,<sup>12-16</sup> and this technique continues to be improved. In a canine model of myocardial infarction, the average image intensity of infarcted myocardium, evaluated with use of a novel MRI approach, was 1080 percent as high as that of normal regions, as compared with a difference of approximately 86 percent with the use of previously reported MRI techniques.<sup>17</sup> Another study in dogs demonstrated that this technique also delineates the transmural extent of infarction and distinguishes between reversible and irreversible myocardial injury regardless of the extent of wall motion at rest, the age of the infarct, or the reperfusion status.<sup>18</sup> In the current study, we tested the hypothesis that this new MRI technique can be used to predict whether or not regions of myocardial dysfunction will improve after revascularization.

### METHODS

#### Patients

Sixty-one patients were prospectively enrolled between January 7, 1998, and September 30, 1999. Patients were selected if they were scheduled to undergo revascularization; had abnormalities in regional wall motion on either contrast ventriculography or echocardiography; did not have unstable angina, New York Heart Association class IV heart failure, or contraindications to MRI (e.g.,

---

From the Feinberg Cardiovascular Research Institute (R.J.K., E.-L.C., M.A.P., F.J.K., R.O.B., R.M.J.) and the Departments of Medicine (R.J.K., E.W., A.R., M.A.P., F.J.K., R.O.B., R.M.J.) and Biomedical Engineering (R.M.J.), Northwestern University Medical School; and Siemens Medical Systems (O.S.) — both in Chicago. Address reprint requests to Dr. Kim at the Feinberg Cardiovascular Research Institute, Northwestern University Medical School, 303 E. Chicago Ave., Tarry 12-733, Chicago, IL 60611-3008 or at r-kim4@northwestern.edu.

a pacemaker); and gave written informed consent. The protocol was approved by the institutional review board of Northwestern University. The study group consisted of 50 consecutive patients (44 men and 6 women; mean [ $\pm$ SD] age,  $63\pm 11$  years) who underwent MRI before undergoing revascularization. In the case of the other 11 patients, 9 decided not to undergo revascularization and in 2, MRI could not be performed before revascularization. No patient was excluded from the study for technical reasons or reasons of image quality, and all 50 patients are included in the analysis.

Twenty-one patients (42 percent) had a documented history of myocardial infarction, and six were studied within two weeks after infarction. The mean interval between MRI and revascularization was  $18\pm 25$  days, and no patient had clinical evidence of infarction during this period. In 41 patients, MRI was repeated a mean of  $79\pm 36$  days after revascularization (27 patients underwent coronary-artery bypass surgery, and 14 percutaneous transluminal coronary angioplasty). Of the remaining nine patients, one had died, two were lost to follow-up, two had had a pacemaker implanted, and four declined to return. Two patients had biochemical evidence of infarction after coronary-artery bypass surgery and before the follow-up MRI.

## MRI

For MRI, each patient was placed supine in a 1.5-T clinical scanner (Siemens Symphony, Erlangen, Germany), and a phased-array receiver coil was placed on the chest for imaging. All images were acquired while the patient held his or her breath for approximately 8 seconds and were gated to the electrocardiogram. Cine images were acquired in six to eight short-axis views and two long-axis views. The acquisition of short-axis views began 1 cm below the level of the mitral-valve-insertion plane and continued in 1-cm increments through the left ventricle. A commercially available gadolinium-based contrast agent (gadopentetate dimeglumine or gadoteridol) was then administered intravenously at a dose of 0.2 mmol per kilogram of body weight, and contrast-enhanced images were acquired in the same views as those used for cine MRI. Contrast-enhanced images were acquired with the use of a segmented inversion-recovery sequence that has been described previously.<sup>17,18</sup> The typical voxel size was 1.9 by 1.4 by 6 mm.

## Analysis of Images

### Registration

The sets of cine and contrast-enhanced images acquired before revascularization had been obtained during the same MRI session (Fig. 1) and thus did not need to be aligned (registered). The registration of cine MRI views acquired before revascularization with those acquired afterward was agreed on by two observers, and the process was facilitated by the fact that double-oblique short-axis "scout" images were always obtained in the same manner and that images were acquired throughout the left ventricle.

### Definition of Segments

We analyzed cine images and contrast-enhanced images using a model in which the left ventricle was divided into 12 circumferential segments on up to six short-axis views (Fig. 1). For patients who were undergoing coronary-artery bypass surgery, all segments were considered to be undergoing revascularization (mean number of grafts,  $3.3\pm 0.7$ ). For patients who were undergoing percutaneous transluminal coronary angioplasty, segments were considered to be undergoing revascularization according to the following scheme: sectors 2 to 5 were considered to represent the territory of the left circumflex artery, sectors 6 to 9 the territory of the right coronary artery, and sectors 10 to 1 the territory of the left anterior descending coronary artery.

### Scoring

Cine images obtained before and after revascularization were placed in random order and analyzed by two observers who were unaware of the patient's identity and the findings on contrast-

enhanced MRI. Contrast-enhanced images were also placed in random order and analyzed by two observers who were unaware of the patient's identity and the findings on cine MRI after revascularization. To reduce the potential for observer bias, full sets of cine and contrast-enhanced images from 13 additional patients with coronary artery disease and ventricular dysfunction who did not undergo revascularization were also included in the randomization.

The extent of segmental wall thickening (i.e., the degree of wall motion or contractility) was agreed on by the two observers and graded on a five-point scale in which a score of 0 indicated normal findings, a score of 1 mild or moderate hypokinesia, a score of 2 severe hypokinesia, a score of 3 akinesia, and a score of 4 dyskinesia. Since after administration there is some uptake of contrast medium throughout the heart, we assessed areas with greatly increased uptake, or hyperenhancement. The extent of hyperenhanced tissue within each segment (referred to as the transmural extent of hyperenhancement) (Fig. 1) was agreed on by the two observers and graded on a 5-point scale in which a score of 0 indicated no hyperenhancement, a score of 1 hyperenhancement of 1 to 25 percent of the tissue in each segment, a score of 2 hyperenhancement of 26 to 50 percent of the tissue, a score of 3 hyperenhancement of 51 to 75 percent of the tissue, and a score of 4 hyperenhancement of 76 to 100 percent of the tissue. In order to assess variability between observers, one third of the images (1075 segments) were read by a third independent observer.

### Image Intensity

For each patient with findings of hyperenhancement, we used a single short-axis image with the largest region of hyperenhancement to compare the intensity of the hyperenhanced region with that of regions without hyperenhancement.

### Ejection Fraction

To determine the ejection fraction, an observer who was unaware of the results of contrast-enhanced MRI outlined the left ventricular borders on the short-axis cine images. The ejection fraction was calculated by subtracting the volume at end systole from the volume at end diastole and dividing the result by the volume at end diastole.


## Statistical Analysis

We used two-sample t-tests to compare continuous variables, which were expressed as means  $\pm$ SD. We used both the chi-square test for trend and a logistic-regression model with a repeated-measures variable for the patient, to adjust for the nonindependence of the data (S-Plus 2000 software for nonlinear mixed-effects models<sup>19</sup>), to assess the relation between the transmural extent of hyperenhancement and improvement in contractility. We used linear regression analysis to examine the relation between viability and changes in global ventricular function. We used kappa values<sup>20</sup> and the Spearman correlation coefficient to assess differences between observers in the scoring of wall-motion abnormalities and hyperenhancement, respectively. All statistical tests were two-tailed, and all P values of less than 0.05 were considered to indicate statistical significance.

## RESULTS

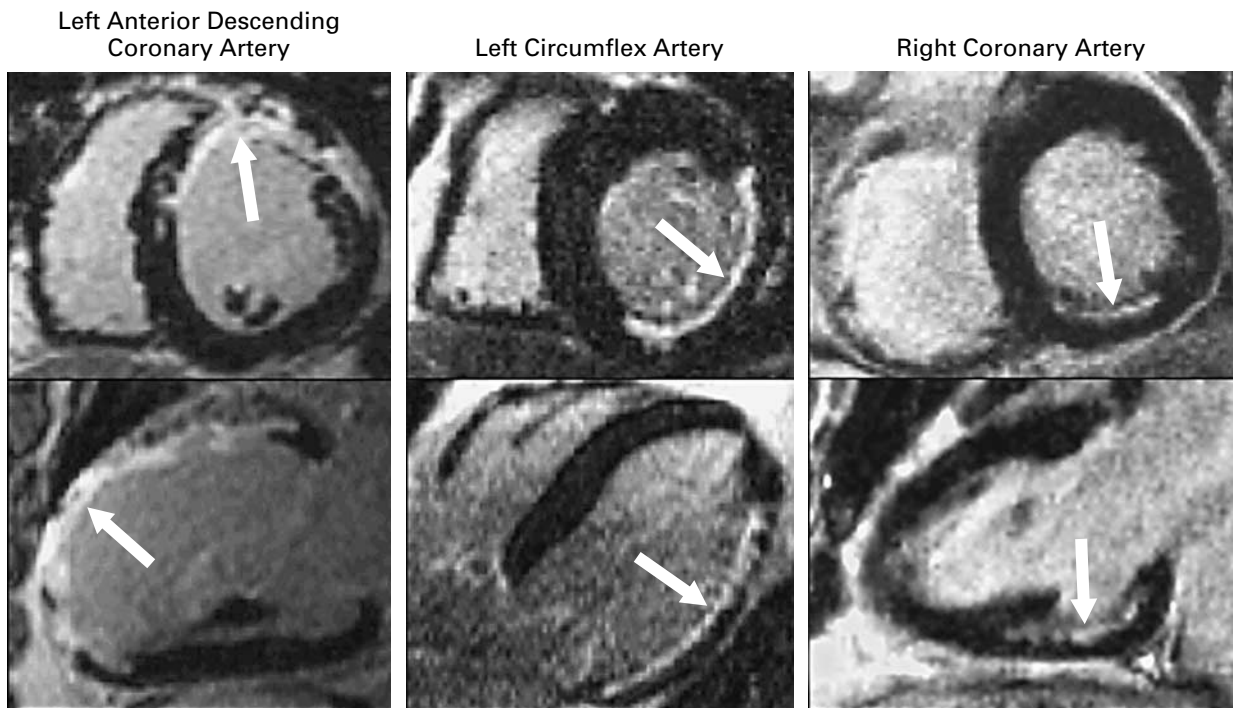
### MRI

Contrast-enhanced MRI demonstrated hyperenhancement in 40 of the 50 patients (80 percent) before revascularization. The mean intensity of hyperenhanced regions was  $530\pm 195$  percent of that of regions without hyperenhancement. In all patients with hyperenhancement, the difference in image intensity between these two regions was more than 6 SD. Figure 2 shows typical examples of hyperenhancement in various coronary-perfusion territories with a range of transmural involvement. Of the 19 patients who



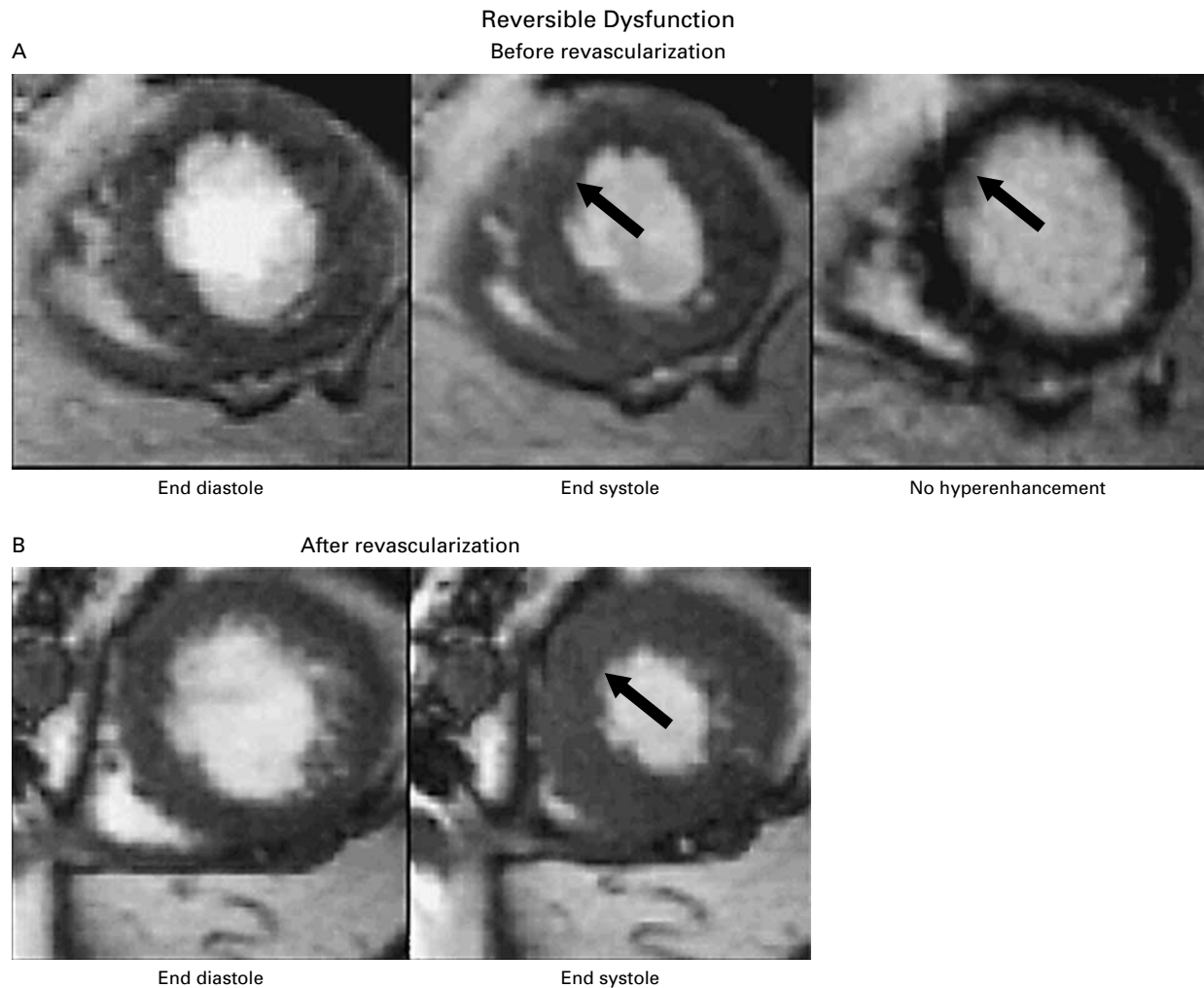
**Figure 1.** Typical Cine Image and Contrast-Enhanced Image Obtained by MRI before Revascularization.

Registration of the images was not required, because both types were acquired during the same MRI session. Twelve equal circumferential segments were analyzed in each short-axis view. For contrast-enhanced images, the transmural extent of hyperenhancement was determined for each segment with use of the following equation: percentage of area that was hyperenhanced =  $100 \times \text{area A} \div (\text{area A} + \text{area B})$ .



**Figure 2.** Typical Contrast-Enhanced Images Obtained by MRI in a Short-Axis View (Upper Panels) and a Long-Axis View (Lower Panels) in Three Patients.

Hyperenhancement is present (arrows) in various coronary-perfusion territories — the left anterior descending coronary artery, the left circumflex artery, and the right coronary artery — with a range of transmural involvement.



**Figure 3.** Representative Cine Images and Contrast-Enhanced Images Obtained by MRI in One Patient with Reversible Ventricular Dysfunction (Panels A and B) and One with Irreversible Ventricular Dysfunction (Panels C and D).

The patient with reversible dysfunction had severe hypokinesia of the anteroseptal wall (arrows), and this area was not hyperenhanced before revascularization. The contractility of the wall improved after revascularization. The patient with irreversible dysfunction had akinesia of the anterolateral wall (arrows), and this area was hyperenhanced before revascularization. The contractility of the wall did not improve after revascularization.

had Q waves on electrocardiograms, 18 had hyperenhancement. Only 2 of these 18 patients had fully transmural hyperenhancement.

For the 41 patients who underwent imaging after revascularization, the mean ejection fraction was  $43 \pm 13$  percent before revascularization and  $47 \pm 12$  percent after the procedure. Eighteen patients (44 percent) had an increase in the ejection fraction of at least 5 percentage points.

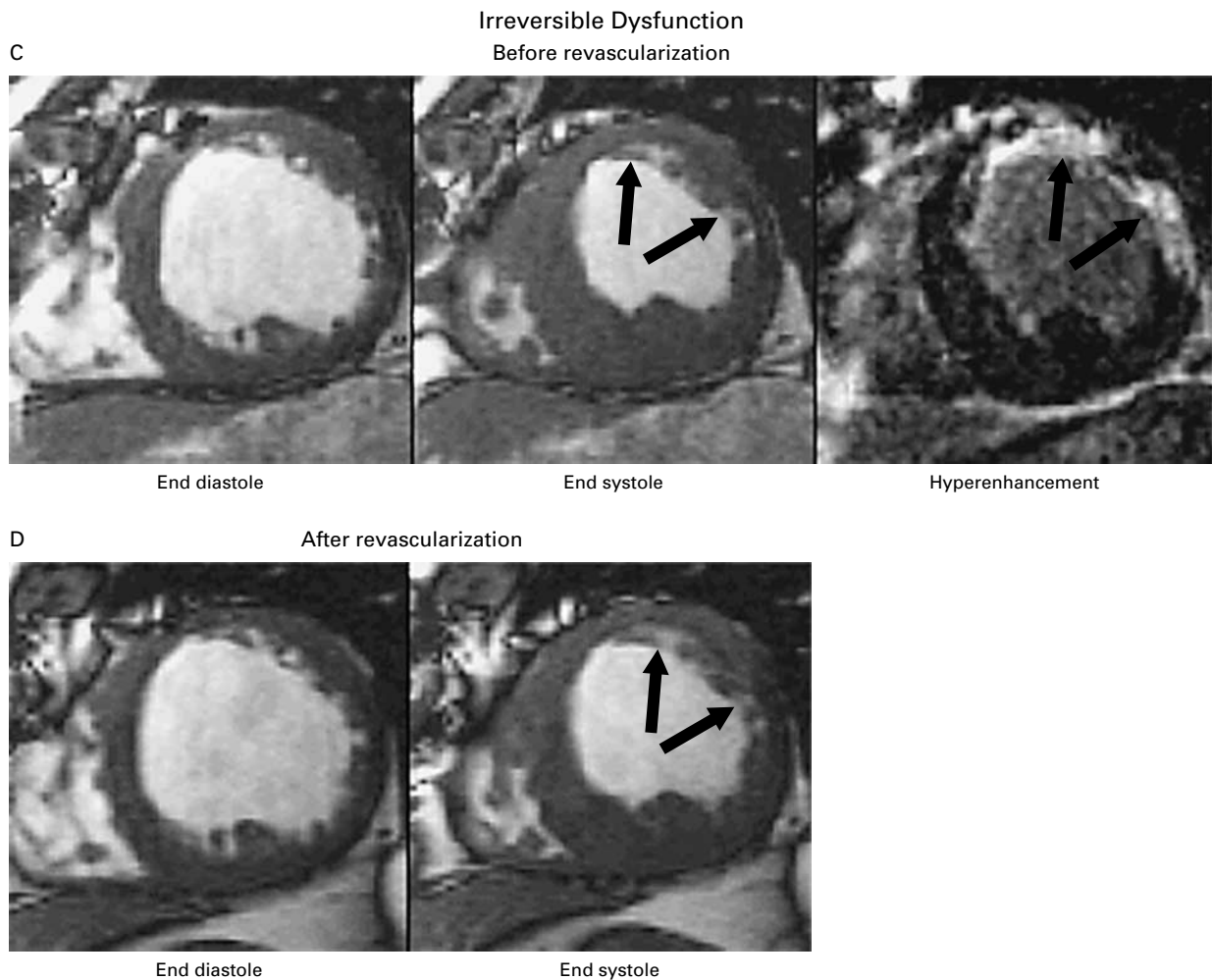
#### Distribution of Scores

In a total of 2093 matched segments, the degree of hyperenhancement was assessed before revascularization and the extent of wall motion was assessed

before and after revascularization. Before revascularization, 804 of the 2093 segments (38 percent) had abnormal contractility, whereas 694 segments (33 percent) had some areas of hyperenhancement. After revascularization, 425 of the 804 segments with abnormal contractility (53 percent) improved, including 59 percent of the segments with mild or moderate hypokinesia before revascularization, 58 percent of those with severe hypokinesia, and 30 percent of those with akinesia or dyskinesia.

#### Relation between Viability and Improved Contractility

Figure 3 shows representative cine images and contrast-enhanced images in two patients. Regional func-

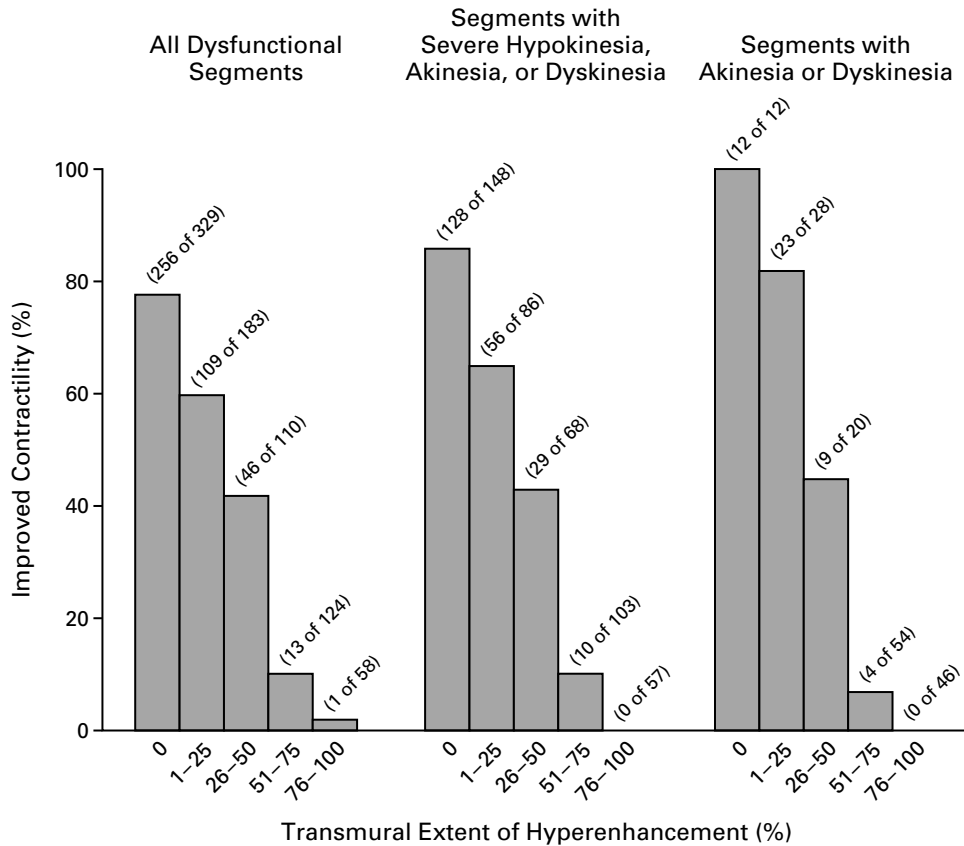


tion recovered in the patient who did not have hyperenhancement of the dysfunctional region on MRI before revascularization, but it did not recover in the patient who had extensive hyperenhancement of the dysfunctional region before revascularization.

The transmural extent of hyperenhancement was significantly related to the likelihood of improvement in contractility after revascularization (Fig. 4). When all segments that were dysfunctional before revascularization were analyzed, the proportion with improved contractility decreased progressively as the transmural extent of hyperenhancement increased ( $P < 0.001$ ). Thus, contractility increased in 256 of 329 segments (78 percent) with no hyperenhancement, but in only 1 of 58 segments with hyperenhancement of more than 75 percent of tissue. The same relation between the transmural extent of hyperenhancement and contractile improvement was found in segments with at least severe hypokinesia at base line ( $P < 0.001$ ) and in

segments with akinesia or dyskinesia at base line ( $P < 0.001$ ). When we reanalyzed the segmental data with a logistic-regression model that included a repeated-measures variable for the patient to adjust for the non-independence of the data, we found the same relation between hyperenhancement and contractile improvement ( $P < 0.001$ ). The mean transmural extent of hyperenhancement was  $10 \pm 7$  percent for the group of dysfunctional segments with improved contractility and  $41 \pm 14$  percent for the group with no improvement in contractility ( $P < 0.001$ ).

In the case of the 1075 segments that were assessed by a third independent observer, the kappa value for improvement in contractility was 0.59 (95 percent confidence interval, 0.53 to 0.64), indicating that the degree of agreement was moderate to good. For all five categories of hyperenhancement, there was a positive relation (Spearman  $r = 0.74$ ,  $P < 0.001$ ) between the scores determined by the first set of observers and



**Figure 4.** Relation between the Transmural Extent of Hyperenhancement before Revascularization and the Likelihood of Increased Contractility after Revascularization.

Data are shown for all 804 dysfunctional segments and separately for the 462 segments with at least severe hypokinesia and the 160 segments with akinesia or dyskinesia before revascularization. For all three analyses, there was an inverse relation between the transmural extent of hyperenhancement and the likelihood of improvement in contractility.

those determined by the third observer, and the concordance was 99 percent (defined as scores that were within 1 point of each other).

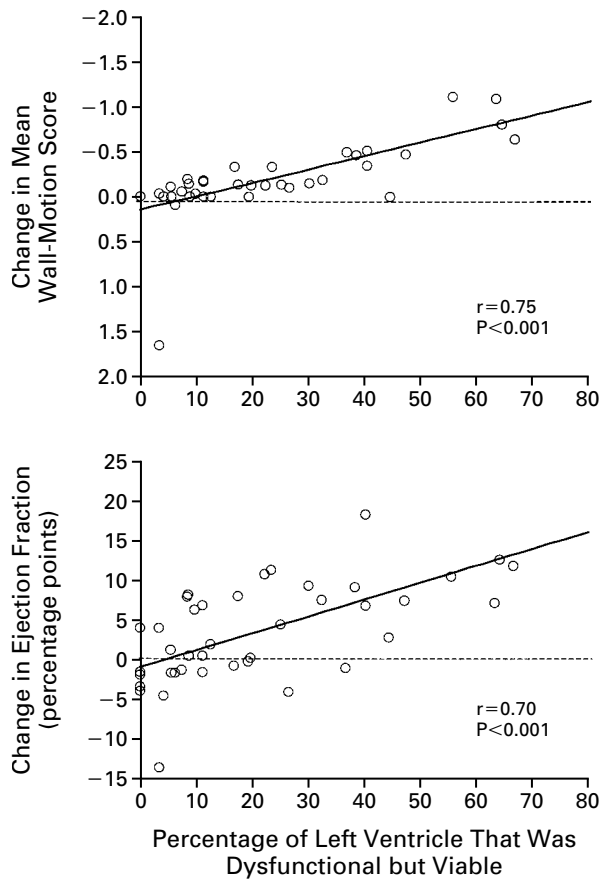
#### Relation between Viability and Improvement in Global Ventricular Function

For each patient, we estimated the percentage of the left ventricle that was dysfunctional but viable before revascularization. We calculated this percentage by adding the number of segments that were dysfunctional but predominantly viable (defined as hyperenhancement of no more than 25 percent of the tissue in each segment) and then dividing the total by the total number of segments in the left ventricle. An increasing extent of dysfunctional but viable myocardium before revascularization correlated with greater improvements in both the mean wall-motion score ( $P < 0.001$ ) and the ejection fraction after revascularization ( $P < 0.001$ ) (Fig. 5).

#### DISCUSSION

Contrast-enhanced MRI of the heart with gadolinium-based contrast agents has been performed since 1984.<sup>21</sup> However, because this method produces only moderate differences in intensity between hyperenhanced regions and regions without hyperenhancement, its use has primarily been limited to the study of large, transmural acute infarcts.<sup>12-14,16,22</sup> Recent technical refinements in contrast-enhanced MRI may improve the delineation of hyperenhanced regions 10-fold.<sup>17</sup> Using these new approaches, we found that the intensity of hyperenhanced regions was more than 500 percent of that of regions without hyperenhancement, and the difference in image intensity between these two regions was on average 14 SD.

An important advantage of contrast-enhanced MRI over other imaging methods that are used to assess myocardial viability is that it shows the transmural extent of viable myocardium. For example, the mid-



**Figure 5.** Relation between the Percentage of the Left Ventricle That Was Dysfunctional but Viable in 41 Patients before Revascularization and the Changes in the Mean Wall-Motion Score and Ejection Fraction after Revascularization.

Decreases in wall-motion scores indicate increases in contractility. The mean ejection fraction was  $43 \pm 13$  percent before revascularization and  $47 \pm 12$  percent after revascularization. One patient had significantly worse function after revascularization and required the insertion of an intraaortic balloon pump after bypass surgery because of a perioperative myocardial infarction.

dle panels of Figure 2 show a patient with hyperenhancement of the inferolateral wall of the left ventricle. With the use of contrast-enhancement criteria, the inferolateral wall would not be interpreted in a binary fashion as either viable or nonviable, but the endocardial portion, which is hyperenhanced, would be interpreted as nonviable, and the epicardial rim, which is not hyperenhanced, would be interpreted as viable. This ability to highlight nontransmural involvement is made possible by the high spatial resolution of contrast-enhanced MRI in addition to the large difference in intensity between hyperenhanced regions and regions without hyperenhancement. The ability of contrast-enhanced MRI to identify even small

regions of nonviable tissue may in part explain why we found that 80 percent of the patients had regional hyperenhancement even though only 42 percent had a documented history of myocardial infarction.

We found that 256 of 329 dysfunctional regions (78 percent) identified as completely viable (i.e., without hyperenhancement) by contrast-enhanced MRI had an improvement in contractility after revascularization. This finding is similar to the results of other investigators who used thallium scintigraphy<sup>4,5,23</sup> and <sup>18</sup>F-fluorodeoxyglucose positron-emission tomography,<sup>3,24</sup> and found that 62 to 88 percent of the myocardial regions with normal uptake of tracer had improved function after revascularization. Several other factors, in addition to limitations in the imaging techniques, may account for the lack of functional improvement in some regions deemed viable. First, the use of a single evaluation of ventricular function soon after revascularization may lead to an underestimation of the true rate of functional recovery.<sup>25,26</sup> Second, tethering of regions with extensive scarring to viable regions may inhibit the response of viable regions to revascularization.<sup>27,28</sup> Third, even if it is technically successful, coronary revascularization may be incomplete, particularly in patients with extensive atherosclerosis and diffuse disease.<sup>5</sup>

In our study, the likelihood of functional improvement in regions without hyperenhancement was 86 percent for segments with at least severe hypokinesia and 100 percent for segments with akinesia or dyskinesia. Thus, unlike nuclear scintigraphy and dobutamine echocardiography, which appear to have reduced predictive accuracy if more severe dysfunction is present,<sup>7</sup> contrast-enhanced MRI had greater accuracy in segments with the most severe dysfunction. This high level of accuracy, even in patients with severe ventricular dysfunction, may be related to the ability of contrast-enhanced MRI to delineate the transmural extent of viable and nonviable myocardium through the ventricular wall.

The relation between the transmural extent of viability and the likelihood of functional improvement after revascularization has not been assessed directly in previous studies. Maes et al.,<sup>29</sup> however, reported fibrosis of  $11 \pm 6$  percent of tissue in needle-biopsy specimens of regions with functional improvement after revascularization, and fibrosis of  $35 \pm 25$  percent of tissue in regions without improvement. More recently, Dakik et al.<sup>30</sup> reported similar findings. Although only a small number of biopsies were performed, these results are similar to ours, since we found that the mean transmural extent of hyperenhancement was  $10 \pm 7$  percent in regions with improved contractility after revascularization and  $41 \pm 14$  percent in regions with no improvement in contractility.

The relation that we found indicates that the use of a single cutoff value for hyperenhancement on which

to base predictions of functional improvement would not have a physiologic basis and therefore would be suboptimal. If a cutoff value of 25 percent were chosen, the positive and negative predictive values would be 71 and 79 percent, respectively, for regions with any degree of dysfunction and 88 and 89 percent, respectively, for regions with akinesia or dyskinesia. Although these values are similar to those reported previously,<sup>31</sup> such an approach does not take advantage of the large amount of diagnostic information provided by contrast-enhanced MRI. For example, if a cutoff value of 75 percent were chosen, none of the 57 segments with at least severe hypokinesia at base line would be considered to have increased contractility after revascularization, yielding a negative predictive accuracy of 100 percent.

Knowledge of the transmural extent of viability may have diagnostic importance apart from its use in the prediction of functional recovery. In our study, 90 percent of the regions with hyperenhancement of 51 to 75 percent of tissue before revascularization did not improve after revascularization. These regions would be considered nonviable according to the wall-motion-improvement criteria, even though a sizable epicardial rim of viable tissue is present. Samady et al.<sup>32</sup> demonstrated that the survival rate after coronary-artery bypass surgery was similar among patients with preoperative ventricular dysfunction whether or not function improved after surgical revascularization. Their hypothesis that there may be an intermediate degree of viability that increases the likelihood of a good outcome after revascularization but does not improve resting contractile function is consistent with our findings. The detection of an epicardial rim of viable tissue by enhanced MRI represents diagnostic information that is not available with the use of other noninvasive imaging techniques.

Supported in part by an American Heart Association Scientist Development Grant (0030280N, to Dr. Kim) and by grants from the National Heart, Lung, and Blood Institute of the National Institutes of Health (R29-HL53411 and R01-HL63268, to Dr. Judd).

*We are indebted to Rainer Ott, M.D., for serving as the third independent observer.*

## REFERENCES

- Rahimtoola SH. A perspective on the three large multicenter randomized clinical trials of coronary bypass surgery for chronic stable angina. *Circulation* 1985;72:Suppl V:V-123-V-135.
- Braunwald E, Rutherford JD. Reversible ischemic left ventricular dysfunction: evidence for the "hibernating myocardium." *J Am Coll Cardiol* 1986;8:1467-70.
- Tillisch J, Brunken R, Marshall R, et al. Reversibility of cardiac wall-motion abnormalities predicted by positron tomography. *N Engl J Med* 1986;314:884-8.
- Dilsizian V, Rocco TP, Freedman NMT, Leon MB, Bonow RO. Enhanced detection of ischemic but viable myocardium by the reinjection of thallium after stress-redistribution imaging. *N Engl J Med* 1990;323:141-6.
- Ragosta M, Beller GA, Watson DD, Kaul S, Gimple LW. Quantitative planar rest-redistribution 201Tl imaging in detection of myocardial viability and prediction of improvement in left ventricular function after coronary bypass surgery in patients with severely depressed left ventricular function. *Circulation* 1993;87:1630-41.
- Arnese M, Cornel JH, Salustri A, et al. Prediction of improvement of regional left ventricular function after surgical revascularization: a comparison of low-dose dobutamine echocardiography with 201Tl single-photon emission computed tomography. *Circulation* 1995;91:2748-52.
- Perrone-Filardi P, Pace L, Prastaro M, et al. Assessment of myocardial viability in patients with chronic coronary artery disease: rest-4-hour-24-hour 201Tl tomography versus dobutamine echocardiography. *Circulation* 1996;94:2712-9.
- Pagley PR, Beller GA, Watson DD, Gimple LW, Ragosta M. Improved outcome after coronary bypass surgery in patients with ischemic cardiomyopathy and residual myocardial viability. *Circulation* 1997;96:793-800.
- Haas F, Hachnel CJ, Picker W, et al. Preoperative positron emission tomographic viability assessment and perioperative and postoperative risk in patients with advanced ischemic heart disease. *J Am Coll Cardiol* 1997;30:1693-700.
- Di Carli MF, Maddahi J, Rokhsar S, et al. Long-term survival of patients with coronary artery disease and left ventricular dysfunction: implications for the role of myocardial viability assessment in management decisions. *J Thorac Cardiovasc Surg* 1998;116:997-1004.
- Chaudhry FA, Tauke JT, Alessandrini RS, Vardi G, Parker MA, Bonow RO. Prognostic implications of myocardial contractile reserve in patients with coronary artery disease and left ventricular dysfunction. *J Am Coll Cardiol* 1999;34:730-8.
- Eichstaedt HW, Felix R, Danne O, Dougherty FC, Schmutzler H. Imaging of acute myocardial infarction by magnetic resonance tomography (MRT) using the paramagnetic relaxation substance gadolinium-DTPA. *Cardiovasc Drugs Ther* 1989;3:779-88.
- de Roos A, van Rossum AC, van der Wall E, et al. Reperfused and nonperfused myocardial infarction: diagnostic potential of Gd-DTPA-enhanced MR imaging. *Radiology* 1989;172:717-20.
- Van Rossum AC, Visser FC, Van Eenige MJ, et al. Value of gadolinium-diethylene-triamine pentaacetic acid dynamics in magnetic resonance imaging of acute myocardial infarction with occluded and reperfused coronary arteries after thrombolysis. *Am J Cardiol* 1990;65:845-51.
- Holman ER, van Jonbergen HP, van Dijkman PR, van der Laarse A, de Roos A, van der Wall EE. Comparison of magnetic resonance imaging studies with enzymatic indexes of myocardial necrosis for quantification of myocardial infarct size. *Am J Cardiol* 1993;71:1036-40.
- Lima JA, Judd RM, Bazille A, Schulman SP, Atalar E, Zerhouni EA. Regional heterogeneity of human myocardial infarcts demonstrated by contrast-enhanced MRI: potential mechanisms. *Circulation* 1995;92:1117-25.
- Simonetti O, Kim RJ, Fieno DS, et al. An improved MRI technique for the visualization of myocardial infarction. *Radiology* (in press).
- Kim RJ, Fieno DS, Parrish TB, et al. Relationship of MRI delayed contrast enhancement to irreversible injury, infarct age, and contractile function. *Circulation* 1999;100:1992-2002.
- S-PLUS 2000 guide to statistics. Vol. 1. Seattle: Mathsoft, 1999.
- Altman DG. *Practical statistics for medical research*. London: Chapman & Hall, 1991.
- Wesbey GE, Higgins CB, McNamara MT, et al. Effect of gadolinium-DTPA on the magnetic relaxation times of normal and infarcted myocardium. *Radiology* 1984;153:165-9.
- van der Wall EE, van Dijkman PR, de Roos A, et al. Diagnostic significance of gadolinium-DTPA (diethylenetriamine penta-acetic acid) enhanced magnetic resonance imaging in thrombolytic treatment for acute myocardial infarction: its potential in assessing reperfusion. *Br Heart J* 1990;63:12-7.
- Perrone-Filardi P, Pace L, Prastaro M, et al. Dobutamine echocardiography predicts improvement of hypoperfused dysfunctional myocardium after revascularization in patients with coronary artery disease. *Circulation* 1995;91:2556-65.
- Tamaki N, Kawamoto M, Tadamura E, et al. Prediction of reversible ischemia after revascularization: perfusion and metabolic studies with positron emission tomography. *Circulation* 1995;91:1697-705.
- Galli M, Marcassa C, Bolli R, et al. Spontaneous delayed recovery of perfusion and contraction after the first 5 weeks after anterior infarction: evidence for the presence of hibernating myocardium in the infarcted area. *Circulation* 1994;90:1386-97.
- Marwick TH, MacIntyre WJ, Lafont A, Nemecek JJ, Salcedo EE. Metabolic responses of hibernating and infarcted myocardium to revascularization: a follow-up study of regional perfusion, function, and metabolism. *Circulation* 1992;85:1347-53.
- Beller GA. Comparison of 201Tl scintigraphy and low-dose dobutamine echocardiography for the noninvasive assessment of myocardial viability. *Circulation* 1996;94:2681-4.
- Force T, Kemper A, Perkins L, Gilfoil M, Cohen C, Parisi AF. Over-

estimation of infarct size by quantitative two-dimensional echocardiography: the role of tethering and of analytic procedures. *Circulation* 1986;73:1360-8.

**29.** Maes A, Flameng W, Nuyts J, et al. Histological alterations in chronically hypoperfused myocardium: correlation with PET findings. *Circulation* 1994;90:735-45.

**30.** Dakik HA, Howell JF, Lawrie GM, et al. Assessment of myocardial viability with <sup>99m</sup>Tc-sestamibi tomography before coronary bypass graft sur-

gery: correlation with histopathology and postoperative improvement in cardiac function. *Circulation* 1997;96:2892-8.

**31.** Bonow RO. Identification of viable myocardium. *Circulation* 1996;94:2674-80.

**32.** Samady H, Elefteriades JA, Abbott BG, Mattera JA, McPherson A, Wackers FJ. Failure to improve left ventricular function after coronary revascularization for ischemic cardiomyopathy is not associated with worse outcome. *Circulation* 1999;100:1298-304.