

Correspondence



Coronary-Artery Bypass Surgery versus Stenting for Multivessel Disease

To the Editor: In a trial comparing coronary-artery bypass surgery with stenting for the treatment of multivessel coronary disease, Serruys et al. (April 12 issue)¹ conclude that both treatments offer protection against death, stroke, and myocardial infarction. We disagree. Whether there is “protection” can be determined only through comparison with a group of patients who are assigned to medical therapy alone.

To date, no clinical trial comparing angioplasty with medical therapy for angina has demonstrated a protective effect of angioplasty in multivessel disease.^{2,3} Indeed, in the second Randomised Intervention Treatment of Angina (RITA-2) trial,³ patients who underwent angioplasty had a significant 91 percent increase (a 3 percent absolute difference) in the rate of death or myocardial infarction during a median of 2.7 years of follow-up. The early randomized, controlled trials comparing coronary surgery with medical treatment also failed to show an improvement in prognosis among patients without stenosis of the left main coronary artery and with good left ventricular function.⁴ Neither of these treatment options has been shown to offer protection against myocardial infarction or stroke. These results can be explained by the fact that risk of plaque rupture is determined not by the patency of the vessel but by the stability of the atheromatous plaque: most episodes of acute coronary occlusion occur in vessels with stenoses that are not flow-limiting (those resulting in a reduction of less than 70 percent in the luminal diameter).⁵ These

two treatments are palliative, and to portray them as protective is misleading.

PETER J. PUGH, M.B., B.S.
LAWRENCE O'TOOLE, M.D.
KEVIN S. CHANNER, M.D.

Royal Hallamshire Hospital
Sheffield S10 2JF, United Kingdom
kevin.channer@csuh.nhs.uk

1. Serruys PW, Unger F, Sousa JE, et al. Comparison of coronary-artery bypass surgery and stenting for the treatment of multivessel disease. *N Engl J Med* 2001;344:1117-24.
2. Folland ED, Hartigan PM, Parisi AF. Percutaneous transluminal coronary angioplasty versus medical therapy for stable angina pectoris: outcomes for patients with double-vessel versus single-vessel coronary artery disease in a Veterans Affairs Cooperative randomized trial. *J Am Coll Cardiol* 1997;29:1505-11.
3. Coronary angioplasty versus medical therapy for angina: the second Randomised Intervention Treatment of Angina (RITA-2) trial. *Lancet* 1997;350:461-8.
4. Yusuf S, Zucker D, Peduzzi P, et al. Effect of coronary artery bypass graft surgery on survival: overview of 10-year results from randomised trials by the Coronary Artery Bypass Graft Surgery Trialists Collaboration. *Lancet* 1994;344:563-70. [Erratum, *Lancet* 1994;344:1446.]
5. Falk E, Shah PK, Fuster V. Coronary plaque disruption. *Circulation* 1995;92:657-71.

To the Editor: Two important methodologic flaws in the trial by Serruys et al. weaken the conclusion that “coronary stenting for multivessel disease is less expensive than bypass surgery and offers the same degree of protection against death, stroke, and myocardial infarction.”

First, the majority of patients who currently undergo surgery have three-vessel disease and impaired ventricular function. In contrast, two thirds of the patients in the trial had two-vessel disease, and the mean left ventricular function for the entire group was normal (ejection fraction, 61 percent). Yusuf and colleagues¹ have emphasized that, unless they have severe disease of the proximal left anterior descending coronary artery, such patients do not receive a survival benefit from surgery as compared with optimal medical therapy. Consequently, although the trial population seems to be highly selected, we are not told what proportion of all pa-

INSTRUCTIONS FOR LETTERS TO THE EDITOR

Letters to the Editor are considered for publication (subject to editing and abridgment) provided they do not contain material that has been submitted or published elsewhere. Please note the following: •Your letter must be typewritten and triple-spaced. •Its text, not including references, must not exceed 250 words if it is in reference to a recent *Journal* article, or 400 words in all other cases (please provide a word count). •It must have no more than five references and one figure or table. •It must not be signed by any more than three authors. •Letters referring to a recent *Journal* article must be received within four weeks of its publication. •Please include your full address, telephone number, fax number, and e-mail address. •You may send us your letter by standard mail, fax, or e-mail.

Our address: Letters to the Editor • *New England Journal of Medicine* • 10 Shattuck St. • Boston, MA 02115

Our fax numbers: 617-739-9864 and 617-734-4457

Our e-mail address: letters@nejm.org

We cannot acknowledge receipt of your letter, but we will notify you when we have made a decision about publication. We are unable to provide prepublication proofs. Financial associations or other possible conflicts of interest must be disclosed. Submission of a letter constitutes permission for the Massachusetts Medical Society, its licensees, and its assignees to use it in the *Journal's* various print and electronic publications and in collections, revisions, and any other form or medium.

tients with multivessel disease, all of whom would be treatable by surgery, were enrolled in the trial (we would hazard a guess of around 10 percent).

Second, transient elevations of creatine kinase MB to more than five times its basal level within 18 hours after surgery is a well-recognized feature of cardiopulmonary bypass, particularly after the harvesting of one or both internal thoracic arteries.² Such an elevation does not reflect perioperative myocardial infarction unless it continues for 24 to 48 hours.²

Most clinicians understand that, in practice, surgery and angioplasty are used to deal with different spectrums of severity of ischemic heart disease. Suggesting that both techniques are equally efficacious, on the basis of results in a highly selected population of patients with "multivessel" disease (i.e., primarily two-vessel disease and normal ventricular function), serves only to confuse the issue, the general physician, and the patient.

DAVID P. TAGGART, M.D., PH.D.
ADRIAN BANNING, M.D.
KEITH CHANNON, M.D.
John Radcliffe Hospital
Oxford OX3 9DU, United Kingdom
david.taggart@orh.nhs.uk

1. Yusuf S, Zucker D, Peduzzi P, et al. Effect of coronary artery bypass graft surgery on survival: overview of 10-year results from randomised trials by the Coronary Artery Bypass Graft Surgery Trialists Collaboration. *Lancet* 1994;344:563-70. [Erratum, *Lancet* 1994;344:1446.]

2. Taggart DP. Biochemical assessment of myocardial injury after cardiac surgery: effects of a platelet activating factor antagonist, bilateral internal thoracic artery grafts, and coronary endarterectomy. *J Thorac Cardiovasc Surg* 2000;120:651-9.

To the Editor: There is cause for concern about the generalizability of the conclusions drawn by Serruys and his coauthors.¹ Indeed, according to a presentation of the results of the Arterial Revascularization Therapies Study that was given in August 2000,² only 5 percent of the patients who were screened were actually enrolled in the study. One should carefully examine the criteria for exclusion from this study, which were the presence of disease in the left main coronary artery, previous percutaneous transluminal coronary angioplasty (PTCA) or coronary-artery bypass grafting (CABG), poor left ventricular function, congestive heart failure, previous stroke, recent myocardial infarction, hepatic or renal disease, chronic total occlusions, or any lesion not "potentially amenable to stent" — presumably, any long lesion in a calcified, tortuous, or small vessel. In other words, most patients who are candidates for intervention were excluded from the trial. The danger is that the conclusions of a study involving such a small, select group of patients cannot be generalized to the population at large.

MICHAEL J. MACK, M.D.
7777 Forest Ln., Suite A323
Dallas, TX 75230
mjmack@earthlink.net

1. Pocock SJ, Elbourne DR. Randomized trials or observational tribulations? *N Engl J Med* 2000;342:1907-9.

2. Moses J. Results of the ARTS trial. Presented at Coronary Interventions for the New Millennium, Linköping, Sweden, August 24, 2000. abstract.

To the Editor: In the study by Serruys et al., one group of patients deserves special consideration. There was a sizable number of patients with diabetes in both groups — 16 percent in the surgery group and 19 percent in the stenting group. It has been shown that patients with diabetes do much better with surgery than with percutaneous coronary intervention for multivessel disease.^{1,2} Other studies have shown that patients with diabetes have a higher incidence of restenosis and target-vessel revascularization after coronary stenting than do patients without diabetes.^{3,4}

It is important to know the rates of clinical events, including the rates of revascularization, in the patients with diabetes in both groups. The difference in the rates of revascularization among these patients might have affected the overall results of the study, and stenting may be a better procedure for patients without diabetes who have multivessel disease. Similarly, the rates of individual clinical events (i.e., stroke, myocardial infarction, or death) might have been different in the stenting group if the patients with diabetes had not been included in the analysis.

MOHAMMED MURTAZA, M.D.
MANOJ SINGH, M.D.
LEKSHMI DHARMARAJAN, M.D.
Lincoln Medical and Mental Health Center
Bronx, NY 10451
mohammedmurtaza@hotmail.com

1. Influence of diabetes on 5-year mortality and morbidity in a randomized trial comparing CABG and PTCA in patients with multivessel disease: the Bypass Angioplasty Revascularization Investigation (BARI). *Circulation* 1997;96:1761-9.

2. Niles NW, McGrath PD, Malenka D, et al. Survival of patients with diabetes and multivessel coronary artery disease after surgical or percutaneous coronary revascularization: results of a large regional prospective study. *J Am Coll Cardiol* 2001;37:1008-15.

3. Elezi S, Kastrati A, Pache J, et al. Diabetes mellitus and the clinical and angiographic outcome after coronary stent placement. *J Am Coll Cardiol* 1998;32:1866-73.

4. Abizaid A, Kornowski R, Mintz GS, et al. The influence of diabetes mellitus on acute and late clinical outcomes following coronary stent implantation. *J Am Coll Cardiol* 1998;32:584-9.

Dr. Serruys replies:

To the Editor: A key criticism of our trial and others that have compared surgery with percutaneous treatment is that they enrolled a highly selected population. The letters question the generalizability of our results, as well as our conclusion that both treatments offer "protection against death, stroke, and myocardial infarction" — a conclusion that Pugh et al. believe can only be drawn on the basis of a comparison with a group of patients assigned to medical therapy alone.

In response to this criticism, I should emphasize that a prospective analysis of the total number of patients with multivessel disease that was diagnosed and treated in the course of one week in each participating center revealed that a leading institution with an annual volume of 1000 bypass operations enrolled up to 33 percent of the patients who were screened during the week of the survey. In addition, in a subgroup of 402 patients with three-vessel disease, 75.0 percent of those who were treated with multivessel stenting remained free of events, whereas 86.5 percent of those with three-vessel disease in the surgery group remained free of events — an absolute difference of 11.5 percent. Moreover, a sizable

cohort of 477 patients who had a lesion in the proximal segment of the left anterior descending artery (segment 6 according to the American Heart Association classification) were enrolled in this trial; in this subgroup, the event-free survival in the stenting group was 77.8 percent — 12.3 percentage points lower than that in the corresponding subgroup of the surgery group (90.1 percent).

A subanalysis revealed that in patients with diabetes mellitus and multivessel coronary artery disease, surgical revascularization with routine use of an arterial conduit for bypass in the left anterior descending artery provides a better clinical outcome at one year (84.4 percent of patients event-free) than percutaneous intervention, even when a strategy of angioplasty plus stenting is used. One-year mortality among the patients with diabetes who were assigned to undergo PTCA plus stenting was twice as high as among those assigned to undergo CABG (6.3 percent vs. 3.1 percent, although the difference was not significant). However, surgery carried a substantial risk of cerebrovascular accident in the patients with diabetes (an incidence of 4.2 percent up to the time of discharge, as compared with 0 percent in the stenting group). Furthermore, the difference in favor of CABG in terms of the rate of revascularization at one year was almost twice as great as it was among the patients without diabetes (21.6 percent vs. 12.4 percent), and our multivariable analysis indicates that diabetes was an independent risk factor for major adverse cardiac or cerebrovascular events within one year in the stenting group but not in the surgery group of our study.

PATRICK W. SERRUYS, M.D.

Erasmus University Rotterdam
3015 GD Rotterdam, the Netherlands
serruys@card.azr.nl

Pseudomonas Hot-Foot Syndrome

To the Editor: We are surprised by the certainty with which Fiorillo et al. (Aug. 2 issue)¹ conclude that the so-called pseudomonas hot-foot syndrome accounts for the unprecedented cluster of cases they describe. All 40 cases occurred 10 to 40 hours after the children had been in a wading pool, but *Pseudomonas aeruginosa* was found in only one child. Water samples from the pool yielded the same microorganism. Invariably, the lesions resolved with the treatment of symptoms. Effective disinfection of the water did not end the outbreak. It ceased only after the floor of the pool had been sanded, although cultures of swabs from the inlets and floor still yielded *P. aeruginosa*.

These findings do not prove that there was a causal relation between *P. aeruginosa* and the skin lesions. Since the presence of *P. aeruginosa* is common in warm and humid environments,² its detection in a single patient suggests an incidental infection.

The entity that the authors describe is consistent with idiopathic palmoplantar hidradenitis.^{3,4} Despite the authors' claim, the inflammatory infiltrate in this disorder is not "confined to the eccrine apparatus" but may extend to the subcutaneous fat and perivascular space and may even cause abscess formation.^{4,5} Friction and a damp environment appear to contribute to the pathogenesis of idiopathic palmoplantar hidradenitis.³ The report by Fiorillo et al. supports this no-

tion, suggests an experimental model for the disorder, and may lead to an understanding of its pathogenesis.

ALEX ZVULUNOV, M.D.

Joseftal Hospital
Eilat 88000, Israel
azvulun@bgumail.bgu.ac.il

AKIVA TRATTNER, M.D.

Rabin Medical Center
Petah Tiqva 49100, Israel

SODY NAIMER, M.D.

Ben Gurion University
Beer Sheva 84101, Israel

1. Fiorillo L, Zucker M, Sawyer D, Lin AN. The pseudomonas hot-foot syndrome. *N Engl J Med* 2001;345:335-8.
2. Ratnam S, Hogan K, March SB, Butler RW. Whirlpool-associated folliculitis caused by *Pseudomonas aeruginosa*: report of an outbreak and review. *J Clin Microbiol* 1986;23:655-9.
3. Naimer SA, Zvulunov A, Ben-Amitai D, Landau M. Plantar hidradenitis in children induced by exposure to wet footwear. *Pediatr Emerg Care* 2000;16:182-3.
4. Rabinowitz LG, Cintra ML, Hood AF, Esterly NB. Recurrent palmoplantar hidradenitis in children. *Arch Dermatol* 1995;131:817-20.
5. Landau M, Metzker A, Gat A, Ben-Amitai D, Brenner S. Palmoplantar eccrine hidradenitis: three new cases and review. *Pediatr Dermatol* 1998; 15:97-102.

The authors reply:

To the Editor: Of the 40 children we described, only 1 child (and the child's family) consented to the incision of a pustule for culture. As we reported, the culture yielded a strain of *P. aeruginosa* with a DNA pattern (identified by pulsed-field gel electrophoresis) that was identical to that of the *P. aeruginosa* isolated from the pool water, a finding strongly suggesting that *P. aeruginosa* in the water was the cause of the lesions. Because all 40 children had virtually identical lesions within 40 hours after using the same pool, and all the lesions had a similar clinical course, it is most likely that this disorder was caused by the same agent. The statement by Zvulunov et al. that the outbreak "ceased only after the floor of the pool had been sanded" is incorrect. New cases occurred even after the floor had been sanded, as we reported. In fact, we noted the persistence of *P. aeruginosa* in the inlets, floor, and drain after the floor had been sanded. The outbreak ended only after these areas were further disinfected with a quaternium ammonium compound and ozone treatment.

As we pointed out, the clinical findings in our patients were similar to those in patients with idiopathic palmoplantar hidradenitis. In a series of 22 patients with idiopathic palmoplantar hidradenitis, the inflammatory infiltrate was "very similar" in all the patients and was "localized to the eccrine apparatus, particularly to the coils."¹ In two other patients, the infiltrate showed "slight extension to the neighboring periglandular connective tissue and subcutis,"² but this observation is uncommonly reported. It is possible that the biopsies in both our patients were performed at the height of the inflammatory response, accounting for the marked inflammation in the subcutis. Our data suggest that *P. aeruginosa* may be the cause in a subgroup of patients with idiopathic palmoplantar hidradenitis, especially those with

deep extension of the inflammatory infiltrate and those in whom the condition occurs as part of an outbreak. We believe the data in our report support the role of *P. aeruginosa* as the etiologic agent in the lesions in our patients.

LORETTA FIORILLO, M.D.
DOUGLAS SAWYER, M.D.
ANDREW N. LIN, M.D.

University of Alberta
Edmonton, AB T6G 2G3, Canada

1. Simon M Jr, Cremer H, von den Driesch P. Idiopathic recurrent palmpoplantar hidradenitis in children: report of 22 cases. *Arch Dermatol* 1998;134:76-9.
2. Rabinowitz LG, Cintra ML, Hood AF, Esterly NB. Recurrent palmpoplantar hidradenitis in children. *Arch Dermatol* 1995;131:817-20.

Glanders in a Military Research Microbiologist

To the Editor: The case report by Srinivasan et al. (July 26 issue)¹ makes one wonder when glanders was first suspected as this patient's illness. The patient's work history included potential exposure to *Burkholderia mallei* without personal protective equipment (gloves). Yet the patient was treated twice with agents not indicated for *B. mallei* infection. Once the organism was isolated, appropriate therapy was administered. When did the patient describe his occupational exposure?

For researchers with occupational infections, the taking of a relevant occupational history that leads to prompt, appropriate therapy can be lifesaving.² A delay in history taking and delayed specific therapy can result in prolonged illness or death.³

Greater attention to safety precautions by researchers and vigilance by research managers will prevent many of these types of exposure. The importance of the occupational history is well documented.⁴ Could a support system be available that would rapidly provide information regarding occupational exposure to clinicians caring for ill researchers? Some research institutions actively encourage patients to volunteer occupational information to the physician,⁵ but this will not help if the patient does not know about the exposure or is incapacitated. We need to find or develop systems to ensure that physicians receive the necessary information during the initial evaluation.

SCOTT DEITCHMAN, M.D., M.P.H.
ROSEMARY SOKAS, M.D., M.O.H.

National Institute for Occupational Safety and Health
Atlanta, GA 30333
sed2@cdc.gov

1. Srinivasan A, Kraus CN, DeShazer D, et al. Glanders in a military research microbiologist. *N Engl J Med* 2001;345:256-8.
2. Arenavirus infection — Connecticut, 1994. *MMWR Morb Mortal Wkly Rep* 1994;43:635-6. [Erratum, *MMWR Morb Mortal Wkly Rep* 1994;43:659.]
3. Fatal Cercopithecine herpesvirus 1 (B virus) infection following a mucocutaneous exposure and interim recommendations for worker protection. *MMWR Morb Mortal Wkly Rep* 1998;47:1073-6, 1083.
4. Milton DK, Solomon GM, Rosiello RA, Herrick RF. Risk and incidence of asthma attributable to occupational exposure among HMO members. *Am J Ind Med* 1998;33:1-10.
5. Laboratory Animal Resource Center. Occupational health and safety information for staff with substantial contact with non-human primates (other than old world primates). San Francisco: University of California, San Francisco, May 2000. (Accessed November 6, 2001, at <http://www.larc.ucsf.edu/docs/private/ohs/nhp.cfm>.)

The authors reply:

To the Editor: The cornerstone of any diagnosis is an accurate, complete medical history. In the case of our patient with glanders, it is interesting to note that all the health care providers involved were aware of the occupational exposure to *B. mallei*, and yet the connection between the patient's job and his illness was not made until he became critically ill. This case underscores the importance of coupling information about exposure with knowledge of the clinical expression of disease. Before this report, glanders had not been reported for more than 50 years, making a low index of suspicion and even a lack of familiarity among primary care physicians completely understandable. We hope that our report will serve as a useful reminder of the manifestations of this unusual disease.

What other lessons can be learned? We agree that researchers should pay close attention to biosafety precautions and that their managers must oversee their adherence to protocols. Researchers should also be aware of the signs and symptoms of the diseases that they study and take responsibility for notifying their health care providers about their exposure. When patients are too ill to do so, this information could come from medical alert tags (like those worn by some patients with diabetes mellitus) or from patients' supervisors or next of kin. In the case we reported, the patient's supervisor provided us with information about exposure and even detailed antimicrobial-sensitivity data at the time of hospital admission.

A final lesson from this case is the importance of reliable clinical information regarding the unfamiliar infections that may arise from biologic warfare. Access to information on the organisms most likely to be used, their transmissibility, the range of potential clinical manifestations, and the most effective treatments is essential to ensure that the medical response is commensurate with the threat to the patient, health care workers, and the community. As concern about bioterrorism grows, we endorse strongly the ongoing efforts to educate physicians about these infections and to formulate plans for responding to such attacks.

ARJUN SRINIVASAN, M.D.
DAVID THOMAS, M.D.
Johns Hopkins Hospital
Baltimore, MD 21287

DAVID DESHAZER, PH.D.
U.S. Army Research Institute for Infectious Diseases
Fort Detrick, MD 21702

Sepsis in a Newborn Due to *Pseudomonas aeruginosa* from a Contaminated Tub Bath

To the Editor: Vochem et al. (Aug. 2 issue)¹ describe a neonate with disseminated *Pseudomonas aeruginosa* infection that was associated with a contaminated tub bath. Of concern is the description of ampicillin, cefotaxime, and gentamicin as "antipseudomonal chemotherapy" and their use after the isolation of *P. aeruginosa* from the patient's blood and cerebrospinal fluid.

Although this regimen may not have influenced the outcome in this case, neither ampicillin nor cefotaxime has substantial activity against *P. aeruginosa*. Gentamicin is char-

acterized by enhanced penetration across the blood–brain barrier in neonates, but it also may not reach bactericidal levels in the cerebrospinal fluid. Effective treatment of *P. aeruginosa* meningitis requires high doses of a third-generation cephalosporin with adequate penetration of the cerebrospinal fluid, such as ceftazidime.² Aminoglycosides may be used as adjunctive treatment in severe cases or if the initial therapy fails or there is a relapse. Other agents that have good in vitro activity and adequate penetration and for which there are reports of clinical success include meropenem,³ ciprofloxacin,⁴ and aztreonam.⁵

DAVID W. WAREHAM, M.B., B.S.

Barts and the London National Health Service Trust
London E1 1BB, United Kingdom
dwareham@msn.com

1. Vochem M, Vogt M, Döring G. Sepsis in a newborn due to *Pseudomonas aeruginosa* from a contaminated tub bath. *N Engl J Med* 2001;345:378-9.
2. Norrby SR. Role of cephalosporins in the treatment of bacterial meningitis in adults: overview with special emphasis on ceftazidime. *Am J Med* 1985;79:56-61.
3. Klugman KP, Dagan R. Carbapenem treatment of meningitis. *Scand J Infect Dis Suppl* 1995;96:45-8.
4. Lipman J, Allworth A, Wallis SC. Cerebrospinal fluid penetration of high doses of intravenous ciprofloxacin in meningitis. *Clin Infect Dis* 2000;31:1131-3.
5. Kilpatrick M, Girgis N, Farid Z, Bishay E. Aztreonam for treating meningitis caused by gram-negative rods. *Scand J Dis* 1991;23:125-6.

The authors reply:

To the Editor: We agree that the combination of ampicillin, gentamicin, and cefotaxime should not be promoted as therapy for established *P. aeruginosa* meningitis. Indeed, we used this combination of antibiotics in our patient only when meningitis was clinically evident, there were findings suggestive of sepsis, and the causative organism had not yet been identified. Our treatment is in complete accordance with general recommendations for the antibiotic treatment of neonates at risk for sepsis.¹

Immediately after the identification of *P. aeruginosa* in the specimens, the antibiotic regimen was altered, and ampicillin was replaced by piperacillin. A further change was initiated when information on the pattern of antibiotic sensitivity was available; treatment was continued with the use of ceftazidime and piperacillin; cefotaxime and gentamicin were withdrawn. Nevertheless, the infecting *P. aeruginosa* strain was still sensitive to cefotaxime and gentamicin, though we agree that the two drugs may not have substantial activity against *P. aeruginosa* in the cerebrospinal fluid. Two days after the initiation of the empirical antimicrobial treatment, a cerebrospinal fluid specimen was sterile.

GERD DÖRING, PH.D.

University of Tübingen
D-72074 Tübingen, Germany
gerd.doering@uni-tuebingen.de

MATTHIAS VOCHER, M.D.

Olgaspital
70176 Stuttgart, Germany

1. Klaus MH, Fanaroff AA, eds. *Care of the high-risk neonate*. 5th ed. Philadelphia: W.B. Saunders, 2001.

Pituitary Carcinoma as a Cause of Acromegaly

To the Editor: Only nine cases of acromegaly caused by pituitary carcinoma have been reported.¹ We describe a 47-year-old woman who presented in July 1996 with the features of acromegaly and an elevated mean serum growth hormone level of 58.4 mU per liter. Magnetic resonance imaging demonstrated an extensive homogeneous pituitary mass compressing the optic chiasm, with extension to the suprasellar region and the right middle cranial fossa. Debulking was attempted transcranially, and histologic examination confirmed a pituitary adenoma that stained for growth hormone. The serum insulin-like growth factor I (IGF-I) level remained elevated at 158 nmol per liter (age- and sex-specific reference range, 13 to 64), but the mean serum growth hormone level decreased (29.7 mU per liter). The serum growth hormone level was not suppressed during an oral glucose-tolerance test, and administration of subcutaneous octreotide was begun at 100 μ g three times a day and increased to 200 μ g three times a day. In March 1997, the patient received 50 Gy of conventional three-field radiotherapy. Six months later, the IGF-I level decreased to 89.5 nmol per liter.

In September 1998, the pituitary lesion remained stable on consecutive magnetic resonance imaging scans, but the IGF-I level had increased (to 111.5 nmol per liter), resulting in a change in therapy to 30 mg of intramuscular lanreotide every 14 days. The patient noticed a lump on the right side of her neck, and a lymph node removed for histologic examination in February 1999 revealed a metastasis that was cytologically identical to the pituitary adenoma and also immunostained for growth hormone (Fig. 1). A dram-

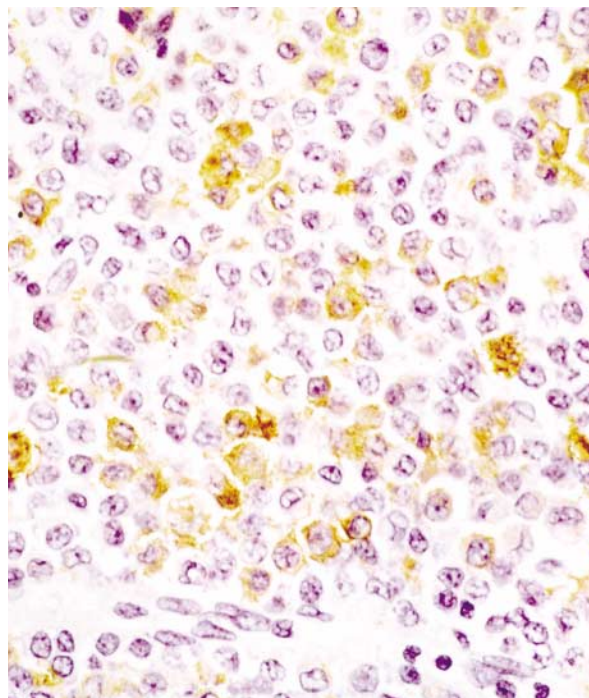


Figure 1. Positive Immunostaining for Growth Hormone in the Lymph-Node Mass from the Right Side of the Patient's Neck.

ic decrease in the IGF-I level (60 nmol per liter) and the mean serum growth hormone level (6.7 mU per liter) followed. Lanreotide was discontinued for six weeks, and both octreotide and metaiodobenzylguanidine scans were negative. We therefore conducted follow-up using clinical examination and biochemical markers. In February 2000, the IGF-I level (122 nmol per liter) and the serum growth hormone level (20.3 mU per liter) increased, so lanreotide therapy was recommenced.

The patient experienced increased sweating. Magnetic resonance imaging of the neck confirmed that the lymph nodes were increasing in size (Fig. 2). A neck dissection was performed in June 2000, and histologic examination showed that 10 of 21 lymph nodes contained metastatic pituitary carcinoma, with positive immunostaining for growth hormone. Cell cultures confirmed production of growth hormone. Six months after surgery, the serum growth hormone level decreased to 3.1 mU per liter and the IGF-I level decreased to 62.7 nmol per liter, with an improvement in symptoms.

One other case of acromegaly caused by pituitary carcinoma metastasizing outside the central nervous system has been reported.² Both patients had nodal metastases in the neck after cranial radiation, which raises the issue of malignant transformation of a benign pituitary adenoma. In contrast to the first patient, our patient had a negative octreotide scan. Surgery was the only option, but because of the insidious nature of the tumor, which behaves similarly to other neuroendocrine tumors, the prognosis remains indeterminate and future treatment options are limited. Pituitary carcinoma should be considered when a pituitary mass re-

mains stable but biochemical markers remain abnormal. A careful physical examination and octreotide scintigraphy should be the first steps before histologic confirmation is sought.

CAREL W. LE ROUX, M.R.C.P.

ABEDA MULLA, B.Sc.

KARIM MEERAN, F.R.C.P.

Imperial College School of Medicine
London W6 8RF, United Kingdom
c.leroux@ic.ac.uk

1. Dayan C, Guilding T, Hearing S, et al. Biochemical cure of recurrent acromegaly by resection of cervical spine canal metastases. *Clin Endocrinol (Oxf)* 1996;44:597-602.

2. Greenman Y, Woolf P, Coniglio J, et al. Remission of acromegaly caused by pituitary carcinoma after surgical excision of growth hormone-secreting metastasis detected by 111-indium pentetreotide scan. *J Clin Endocrinol Metab* 1996;81:1628-33.

Cutaneous *Bacillus anthracis* Infection

To the Editor: We report the case of an otherwise healthy 34-year-old man, employed in the mailroom of a New York City daily newspaper, who presented with a rapidly growing nodule over the flexor surface of his left forearm (Fig. 1). He stated that the lesion had begun as a "pimple" six days earlier. Initially, the lesion was pruritic and erythematous. Within 24 hours, the pruritis resolved and the nodule developed a central black eschar. The patient said that he had no fever, chills, or respiratory or gastrointestinal symptoms. Because of both the characteristics of the lesion and the diagnosis of cutaneous anthrax in one of the patient's coworkers, a referring physician had prescribed ciprofloxacin (500 mg two times daily), which the patient had taken for the three days preceding his presentation.

On physical examination, there was a 1.5-cm nontender, erythematous nodule with a central, 0.4-cm black eschar

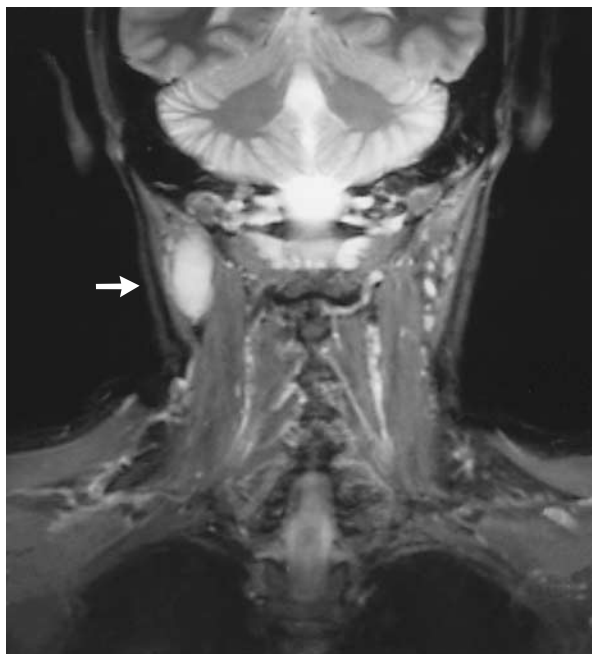

Figure 2. Magnetic Resonance Imaging of the Lymph-Node Mass in the Right Side of the Patient's Neck.

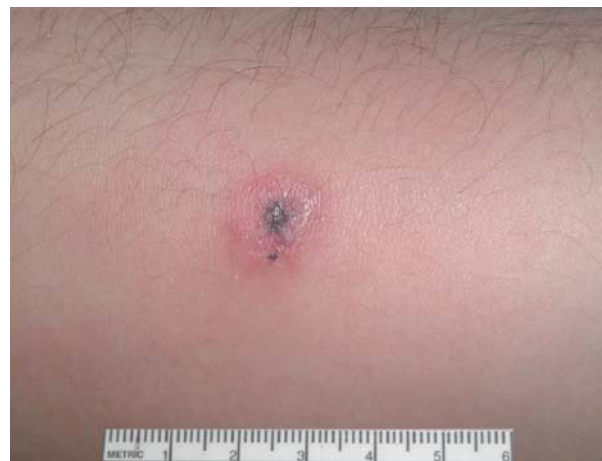

Figure 1. *Bacillus anthracis* Lesion on the Forearm of the Patient.

Because of current health concern, this letter was published at www.nejm.org on November 8, 2001.

on the left forearm. There were three intact vesicles, 0.1 to 0.2 cm in diameter, on the surface of the nodule. Surrounding the nodule was an erythematous, indurated plaque, 6.5 cm in diameter. Mild swelling of the forearm was evident. There was no lymphangitis or lymphadenopathy. The physical examination was otherwise unremarkable.

Hematoxylin–eosin staining of lesional tissue revealed marked superficial papillary edema, diffuse interstitial inflammation with focal blood-vessel congestion, and acute vasculitis. A Gram's stain revealed gram-positive rods, and immunohistochemical analysis confirmed the presence of *Bacillus anthracis*.

The patient continued to take the same dose of ciprofloxacin. At a follow-up examination one week after pres-

entation, the size of the lesion had diminished and the surrounding erythema had resolved. He remained free of constitutional symptoms.

T. CASEY GALLAGHER, M.D.

Bellevue Hospital
New York, NY 10016
tcaseygallagher@yahoo.com

BRUCE E. STROBER, M.D., PH.D.

New York University School of Medicine
New York, NY 10016

Correspondence Copyright © 2001 Massachusetts Medical Society.

FULL TEXT OF ALL *JOURNAL* ARTICLES ON THE WORLD WIDE WEB

Access to the complete text of the *Journal* on the Internet is free to all subscribers. To use this Web site, subscribers should go to the *Journal's* home page (<http://www.nejm.org>) and register by entering their names and subscriber numbers as they appear on their mailing labels. After this one-time registration, subscribers can use their passwords to log on for electronic access to the entire *Journal* from any computer that is connected to the Internet. Features include a library of all issues since January 1993 and abstracts since January 1975, a full-text search capacity, and a personal archive for saving articles and search results of interest. All articles can be printed in a format that is virtually identical to that of the typeset pages. Beginning six months after publication the full text of all original articles and special articles is available free to nonsubscribers who have completed a brief registration.
