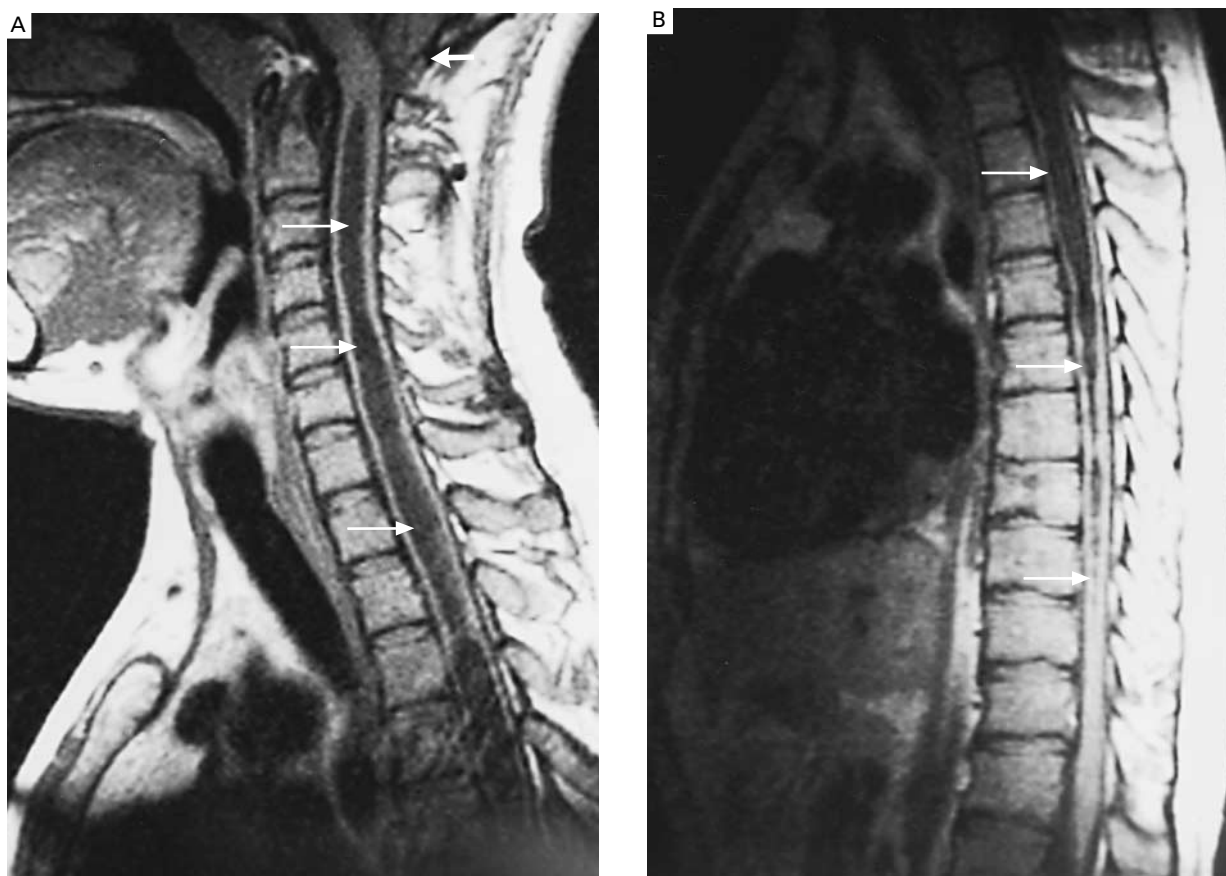




## Images in Clinical Medicine



### *Syringomyelia*

A 24-year-old man had a three-year history of progressive muscle wasting and sensory loss in his arms, dysphonia, and dysphagia. During the previous five months, he had had several painless burns on his hands. He had no history of cranial or cervical trauma. He had marked atrophy of the right deltoid, biceps, and upper trapezius muscles and of the hypothenar eminence and dorsal interosseous muscles of the right hand. Biceps, triceps, and brachioradialis reflexes were bilaterally abolished. Sensitivity to pain and heat was lost in both arms, over the right side of the face, and over the chest and upper back. Hypalgesia was present in the perioral skin of the left side of the face. The right corneal reflex was decreased. Touch and pressure perception was preserved. No gait abnormality was identified. Sagittal, T<sub>1</sub>-weighted magnetic resonance imaging (MRI) of the cervical spine without gadolinium enhancement showed a pathologic cavitation (syrinx) extending along the entire cervical cord (arrows in Panel A). MRI of the dorsal spine showed syringomyelic disease of the dorsal cord (arrows in Panel B). A cervical syringotomy was performed. Two years later, there had been no change in the degree of sensory loss and amyotrophy, but the dysphonia and dysphagia had decreased, and no further clinical deterioration had occurred.

JOSE ALBERTO SAGÁSTEGUI-RODRÍGUEZ, M.D.  
*Universidad Autónoma de Nuevo León  
 Monterrey, Mexico*

SALVADOR CRUZ-FLORES, M.D.  
*Saint Louis University  
 St. Louis, MO 63110*

Copyright © 2002 Massachusetts Medical Society.