

PATERNALLY INHERITED INACTIVATING MUTATIONS OF THE *GNAS1* GENE IN PROGRESSIVE OSSEOUS HETEROPLASIA

EILEEN M. SHORE, PH.D., JAIMO AHN, PH.D., SUZANNE JAN DE BEUR, M.D., MING LI, B.A., MEIQI XU, B.S., R.J. MCKINLAY GARDNER, M.B., MICHAEL A. ZASLOFF, M.D., PH.D., MICHAEL P. WHYTE, M.D., MICHAEL A. LEVINE, M.D., AND FREDERICK S. KAPLAN, M.D.

ABSTRACT

Background Progressive osseous heteroplasia (POH), an autosomal dominant disorder, is characterized by extensive dermal ossification during childhood, followed by disabling and widespread heterotopic ossification of skeletal muscle and deep connective tissue. Occasional reports of mild heterotopic ossification in Albright's hereditary osteodystrophy (AHO) and a recent report of two patients with AHO who had atypically extensive heterotopic ossification suggested a common genetic basis for the two disorders. AHO is caused by heterozygous inactivating mutations in the *GNAS1* gene that result in decreased expression or function of the alpha subunit of the stimulatory G protein ($G_s\alpha$) of adenylyl cyclase.

Methods We tested the hypothesis that *GNAS1* mutations cause POH, using the polymerase chain reaction to amplify *GNAS1* exons and exon-intron boundaries in 18 patients with sporadic or familial POH.

Results Heterozygous inactivating *GNAS1* mutations were identified in 13 of the 18 probands with POH. The defective allele in POH is inherited exclusively from fathers, a result consistent with a model of imprinting for *GNAS1*. Direct evidence that the same mutation can cause either POH or AHO was observed within a single family, in which the phenotype correlated with the parental origin of the mutant allele.

Conclusions Paternally inherited inactivating *GNAS1* mutations cause POH. This finding extends the range of phenotypes derived from haploinsufficiency of *GNAS1*, provides evidence that imprinting is a regulatory mechanism for *GNAS1* expression, and suggests that $G_s\alpha$ is a critical negative regulator of osteogenic commitment in nonosseous connective tissues. (N Engl J Med 2002;346:99-106.)

Copyright © 2002 Massachusetts Medical Society.

BONE formation is a highly regulated process that generally restricts ossification to the skeleton, yet the molecular control of bone-cell differentiation is not well understood. Progressive osseous heteroplasia (POH; number 166350 in *Mendelian Inheritance in Man* [MIM], a catalogue of inherited diseases¹) is a rare disorder characterized by dermal ossification during childhood (Fig. 1A), with progressive and extensive formation of heterotopic bone within deeper tissues (Fig. 1B and 1C).²⁻⁶ POH first appears during infancy with the eruption of islands of heterotopic bone in the re-

ticular dermis and subcutaneous fat. Over time, these ossified areas coalesce into plaques that may invade fascia, skeletal muscle, tendons, and ligaments, resulting in ankylosis of affected joints and focal retardation of the growth of involved limbs.^{2,3,6,7} Progression of dermal ossification into deep connective tissues is the defining feature of POH.^{2,8} POH is not associated with trauma, infection, or metabolic abnormalities and is distinct from fibrodysplasia ossificans progressiva (MIM number 135100).⁸

POH may be either sporadic or inherited as an autosomal dominant trait.^{2,6} The lack of large, multigenerational families or a naturally occurring animal model has impeded gene identification. Reports of dermal and subcutaneous ossification in patients with Albright's hereditary osteodystrophy (AHO),⁹ a complex disorder characterized by developmental defects and dysmorphologies, suggested the possibility of a common molecular basis for POH and AHO.⁵ AHO-specific dysmorphologies are often associated with resistance to parathyroid hormone and with resistance to other hormones (in which case the disorder is referred to as pseudohypoparathyroidism type 1a). When AHO occurs without hormone resistance in families with pseudohypoparathyroidism type 1a, the disorder is described as pseudopseudohypoparathyroidism.

AHO is caused by heterozygous inactivating mutations in *GNAS1*, the gene for guanine nucleotide-binding protein (G protein) alpha stimulating activity polypeptide 1, that result in decreased expression or function of the alpha subunit of the stimulatory G protein ($G_s\alpha$) of adenylyl cyclase.⁹ Although heterotopic ossification in patients with AHO is milder and more superficial than that in patients with POH, the recent description¹⁰ of inactivating *GNAS1* mutations, decreased $G_s\alpha$ activity, or both in two patients with features of both AHO and severe progressive hetero-

From the Departments of Orthopaedic Surgery (E.M.S., J.A., M.L., M.X., F.S.K.), Genetics (E.M.S., M.A.Z.), and Medicine (F.S.K.), University of Pennsylvania School of Medicine, Philadelphia; the Ilyssa Center for Molecular and Cellular Endocrinology (S.J.B., M.A.L.) and the Departments of Medicine (S.J.B.) and Pediatrics (M.A.L.), Johns Hopkins University School of Medicine, Baltimore; Genetic Health Services, Victoria and Murdoch Children's Research Institute, Royal Children's Hospital, Melbourne, Australia (R.J.M.G.); and the Center for Metabolic Bone Disease and Molecular Research, Shriners Hospitals for Children, and the Division of Bone and Mineral Diseases, Washington University School of Medicine, St. Louis (M.P.W.). Address reprint requests to Dr. Shore at the Department of Orthopaedic Surgery, University of Pennsylvania School of Medicine, 424 Stemmler Hall, 36th and Hamilton Walk, Philadelphia, PA 19104-6018, or at shore@mail.med.upenn.edu.

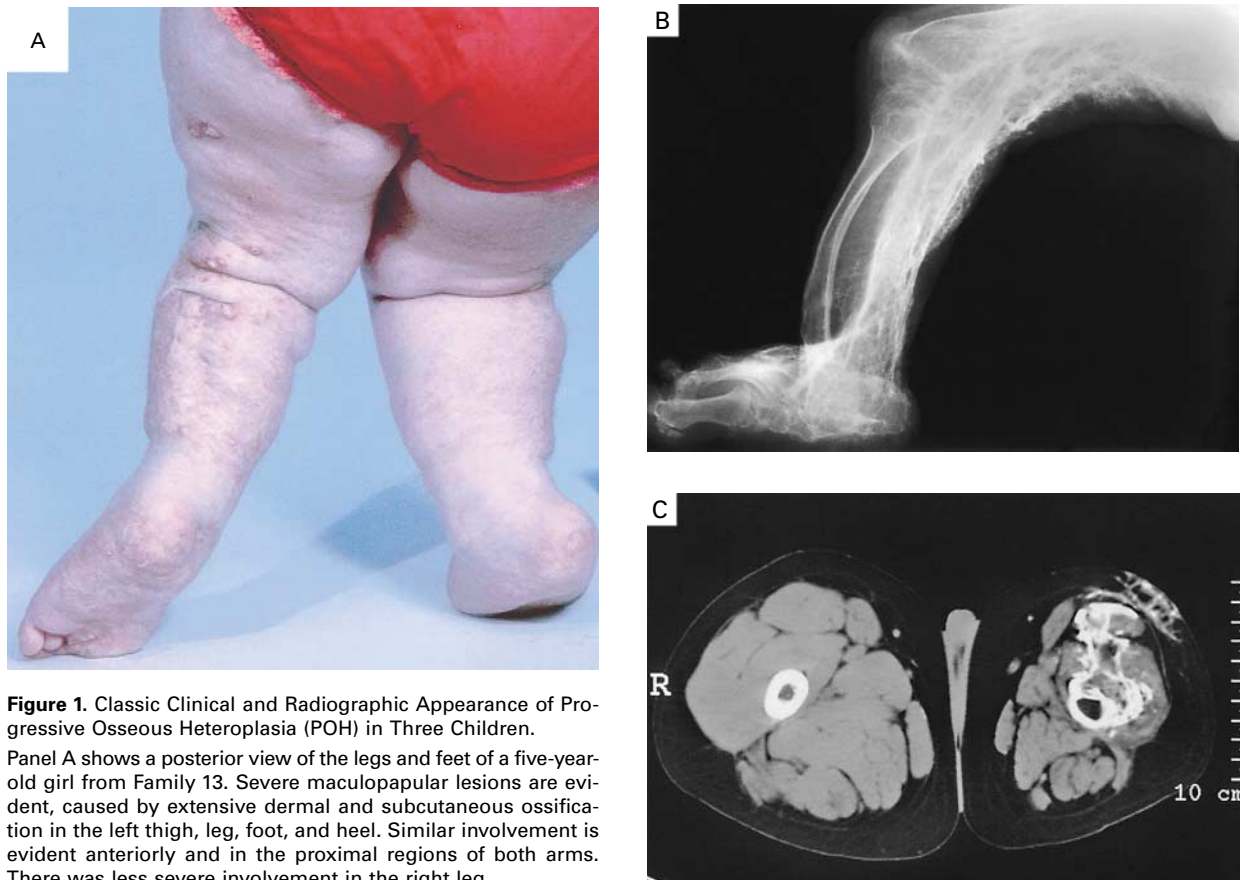


Figure 1. Classic Clinical and Radiographic Appearance of Progressive Osseous Heteroplasia (POH) in Three Children.

Panel A shows a posterior view of the legs and feet of a five-year-old girl from Family 13. Severe maculopapular lesions are evident, caused by extensive dermal and subcutaneous ossification in the left thigh, leg, foot, and heel. Similar involvement is evident anteriorly and in the proximal regions of both arms. There was less severe involvement in the right leg.

Panel B shows the radiographic appearance of severe heterotopic ossification in POH. A lateral roentgenogram of the right leg of an 11-year-old girl from Family 8 shows severe heterotopic ossification of the soft tissues. There was extensive involvement of the entire right side of the body, including the jaw, neck, torso, abdomen, and pelvis, with ankylosis of joints of the axial and appendicular skeleton. Less severe involvement occurred at scattered sites on the left side of the body.

Panel C shows an unenhanced computed tomographic image of the thighs of a 10-year-old boy from Family 14. The right thigh (R) was normal. The soft tissues of the left thigh were atrophied, and there was extensive soft-tissue ossification of the skin, subcutaneous fat, and quadriceps muscles that extended to the anterior cortex of the femur. In addition, the child had similar severe heterotopic ossification involving the left iliac crest and psoas muscle, as well as the entire left leg, with bony ankylosis of the left hip and left knee. Both Achilles tendons and the soft tissues of both heel pads contained extensive heterotopic ossification. The left leg was 4 cm shorter than the right.

topic ossification provided a further rationale to investigate *GNAS1* as a candidate gene for POH.

METHODS

Subjects

We evaluated subjects from 18 unrelated kindreds with familial POH (6 cases) or sporadic POH (12 cases). The protocol was ap-

proved by the investigational review boards of the Children's Hospital of Philadelphia and the University of Pennsylvania, and written informed consent was obtained from the subjects or their parents. Patients from Families 3,⁶ 5, 12, and 13,² 8,³ 11,¹¹ 16,¹² and 18¹³ have been previously described in case reports.

Polymerase-Chain-Reaction Amplification and Sequencing of Genomic DNA

Genomic DNA was isolated directly from blood or from Epstein-Barr virus-transformed lymphocyte lines with the use of DNA blood-isolation reagents (QIAamp, Qiagen, Valencia, Calif); it was amplified with the use of oligonucleotide primers flanking exons 2 to 13 of the human *GNAS1* gene¹⁴ under previously reported polymerase-chain-reaction (PCR) conditions.¹⁵ For exon 1, the primer pair 5'ATGGGCTGCCTCGGGAACAGTA (forward; beginning at the initiator codon) and 5'CCCTTACCCAGCAGCAGCAGGC (reverse) was used for 40 cycles: 1 minute at 94°C, 40 seconds at 70°C, and 1 minute at 72°C. Each PCR reaction contained 200 ng of genomic DNA, each primer at a concentration of 0.4 μM, 0.08 mM deoxynucleoside triphosphates (Pharmacia, Piscataway, N.J.), 1.5 mM magnesium chloride, and 1.25 U of *Taq* polymerase (Life Technologies, Gaithersburg, Md.). Products were sequenced by the DNA Sequencing Core Facility of the University of Pennsylvania School of Veterinary Medicine.

RNA Isolation and Reverse Transcriptase-PCR Analysis

The total RNA from lymphoblastoid cell lines was isolated with use of Trizol reagent (Life Technologies), and poly(A)⁺ RNA was

isolated with use of Micro-FastTrack reagents (Invitrogen, Carlsbad, Calif.). First-strand complementary DNA (cDNA) was synthesized from 1 μg of total RNA with the use of 12.5 μg of oligo-dT primer per milliliter and 1 mg of RNasin (Promega, Madison, Wis.) per milliliter, 5 U of SuperScript II reverse transcriptase (Life Technologies) per milliliter, 5 mM magnesium chloride, 10 mM dithiothreitol, and 1 mM deoxynucleoside triphosphates (Pharmacia) in a final volume of 10 μl at 42°C for 1 hour, followed by heat inactivation at 95°C for 10 minutes. First-strand cDNA (5 μl) was amplified by PCR with 1.5 mM magnesium chloride, 2.5 units of AmpliTaq (Perkin-Elmer, Norwalk, Conn.), and 50 ng of each forward and reverse primer in a final volume of 20 μl for 40 cycles: one minute at 94°C, one minute at 53° to 72°C (optimized for each primer pair), and two minutes at 72°C. The products were gel-purified and sequenced as above. Primer pairs to amplify *GNAS1* cDNA were designed with MacVector (Accelrys, San Diego, Calif.).

The GenBank accession numbers are AH002748 for *GNAS1* human genomic DNA and NM000516 for *GNAS1* human cDNA.

RESULTS

Inheritance Patterns in Families with POH

Subjects with POH from 18 unrelated families were examined (Fig. 2). In four families (Families 1, 2, 3, and 4), children inherited POH from an affected father, a finding consistent with autosomal dominant inheritance. Two additional families (Families 5 and 18) had affected siblings with no affected parent. The severity and distribution of heterotopic ossification varied among affected members in each family; at least one affected person in each family had severe progressive heterotopic ossification during childhood, whereas other affected family members had dermal and subcutaneous ossification later in life, with slower pro-

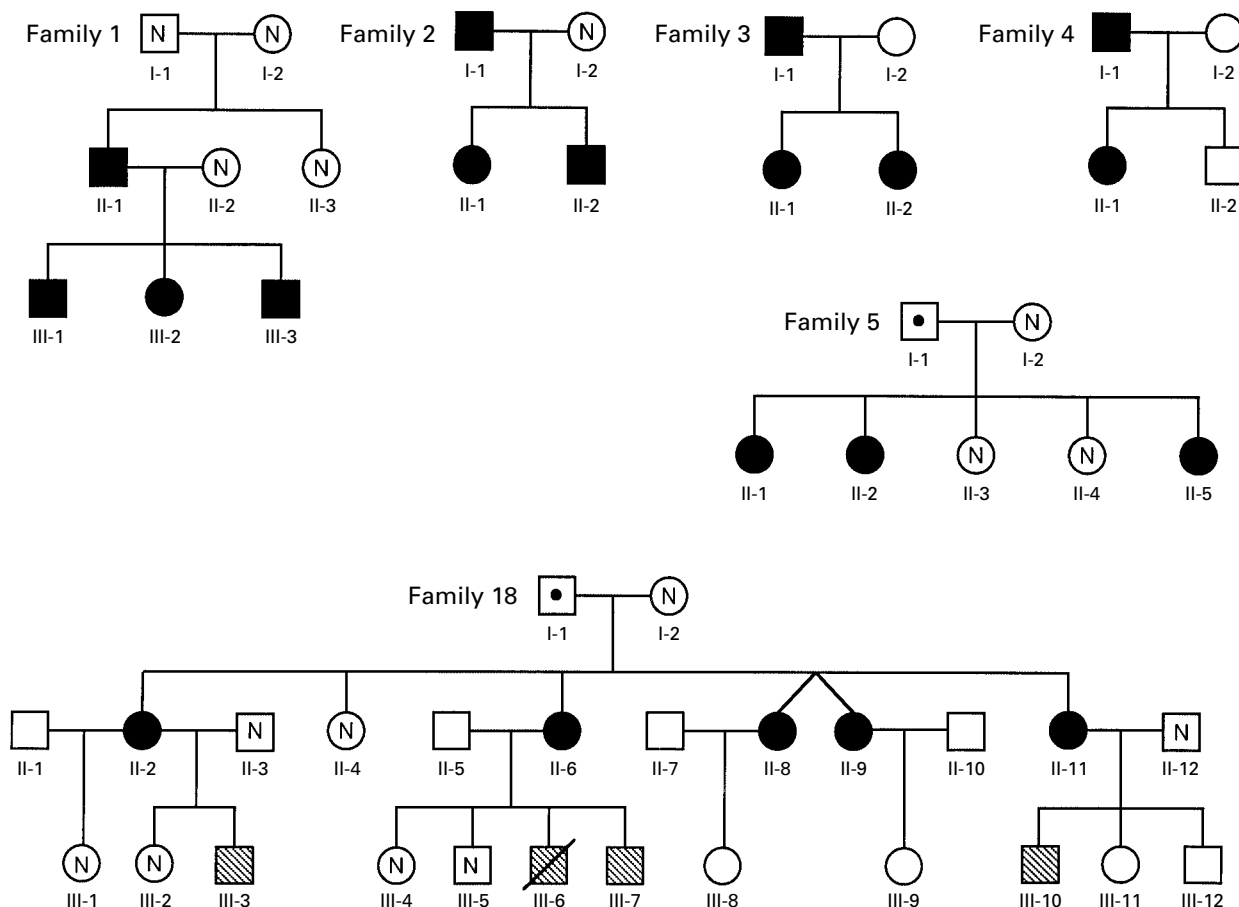


Figure 2. Pedigrees of Six Families with Progressive Osseous Heteroplasia (POH).

Standard notation is used. Circles and squares denote female and male family members, respectively; solid symbols indicate persons with POH, and hatched symbols indicate persons with Albright's hereditary osteodystrophy (AHO). Symbols with a slash indicate deceased family members, and symbols with N family members with no mutations. Families 1, 2, 5, and 18 have identified *GNAS1* mutations; no mutation has been identified in Family 3 or Family 4. All persons shown with filled or hatched symbols in Families 1, 2, 5, and 18 tested positive for the family-specific mutation (except for Subjects III-6 and III-10 in Family 18, who were not tested). Two persons (Subject I-1 in Family 5 and Subject I-1 in Family 18, indicated by a black dot within the symbol) were heterozygous for mutations but had no clinical manifestations. Families 6 through 17 contained a single affected member, and their pedigrees are not shown.

gression to deeper tissues. The remaining 12 families each had only one member with POH. Affected persons had no primary skeletal or developmental defects and no laboratory or clinical evidence of hormone resistance.

Identification of *GNAS1* Mutations in Subjects with POH

Subjects with POH were screened for mutations in *GNAS1* by PCR amplification and DNA sequencing

of exons 1 to 13, all splice junctions, and some small introns. Heterozygous mutations were identified in 13 of 18 families: in 12 families, affected persons had small insertions, deletions, or tandem duplications that resulted in frame shifts predicted to cause premature termination of translation of the messenger RNA (mRNA) and loss of protein function (Fig. 3 and Table 1). In one family, Family 14, a single-nucleotide, G-to-C mutation altered the invariant AG dinucle-

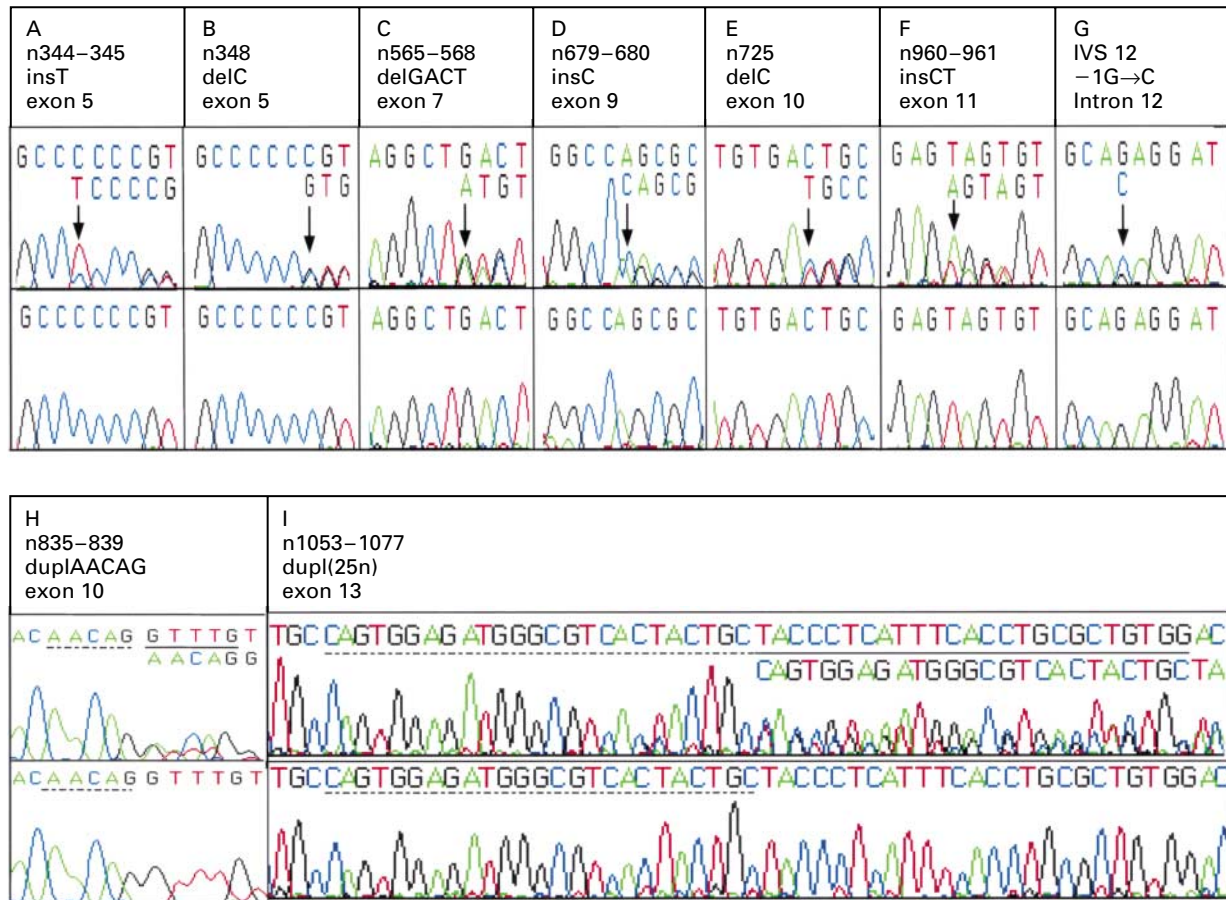


Figure 3. Heterozygous Mutations in Patients with Progressive Osseous Hyperplasia (POH).

For each region of the *GNAS1* gene in which a mutation was identified, sets of DNA sequencing chromatograms for normal *GNAS1* genomic DNA from control subjects (lower panels) and mutated *GNAS1* genomic DNA from control subjects (upper panels) are shown. Chromatograms from control subjects (lower panels) reveal a single DNA sequence from each region, demonstrating that the two alleles of the *GNAS1* gene contain identical DNA sequences (represented by the single nucleotide sequence above each set of chromatogram peaks). In the patients (upper panels), by contrast, mutations that alter the DNA sequence of one of the two *GNAS1* copies are revealed by a discordance or shift of the DNA sequence (as represented in the overlapping pattern of chromatogram peaks and by a second line of nucleotide sequence at the beginning of each discrepancy). In each panel, the specific position of the mutation within the *GNAS1* gene is identified by the complementary DNA nucleotide number (n). Representative chromatograms are shown of frame-shift mutations due to insertions (ins) of nucleotides in the mutant allele (Panels A, D, and F), deletions (del) of nucleotides in the mutant allele (Panels B, C, and E), or tandem duplications (dupl; Panel H, 5 nucleotides duplicated; Panel I, 25 nucleotides duplicated). In Panel F, the reverse sequence is shown in the chromatograms. Panel G shows a one-nucleotide substitution at an acceptor splice site (–1G→C). IVS 12 denotes intron (intervening sequence) 12. In Panels A through F, the arrow indicates the start of the frame-shifted sequence. In Panels H and I, the dashed line indicates the sequence that is duplicated in the region indicated by the solid line.

otide of the intron 12 acceptor splice site (Fig. 3). Mutation of the conserved AG dinucleotide to AC results in the use of a downstream AG as the acceptor site and production of a frame-shifted mRNA (data not shown).

No *GNAS1* mutation was identified in 2 of 6 familial cases (Fig. 2; Families 3 and 4) and 3 of 12 sporadic cases. Large deletions or rearrangements of the *GNAS1* gene of these subjects were excluded by Southern blot analysis of genomic DNA.

Nonpenetrant *GNAS1* Mutations in Families with POH

In four kindreds with POH, we examined genomic DNA from phenotypically normal parents of affected children for *GNAS1* mutations. The clinically unaffected father in Family 5 (Fig. 2) had the same single-nucleotide deletion in exon 10 as his three affected daughters, indicating the absence of penetrance of this mutation in the father. Similarly, the unaffected father in Family 18 (Subject I-1 in Fig. 2) carried the same deletion in exon 7 that was identified in his five affected daughters. In both Family 5 and Family 18, the unaffected mother and the unaffected siblings did not have the mutation. By contrast, the single affected person in Family 6 (pedigree not shown) and Subject II-1 in Family 1 (Fig. 2 and Table 1) presumably had new mutations, because none of their parents carried that mutation, although gonadal mosaicism in a parent is possible. With the exception of the unaffected fathers in Families 5 and 18, all affected subjects who were tested in families with inheritance of POH, but none of the unaffected subjects who were tested in such families, shared the same *GNAS1* mutation.

Expression of *GNAS1* mRNA in POH

According to reverse-transcriptase-PCR amplification of *GNAS1* mRNA from 10 subjects with identified mutations, only 2 (from Families 2 and 14) had expression of both normal and mutant *GNAS1* transcripts (Table 1). Both subjects had a mutation near the 3' end of the gene: one was a frame shift in exon 13, and the other was an altered intron 12 acceptor splice site. The remaining eight subjects had only the normal mRNA sequence. This result indicated that mRNA from the mutant *GNAS1* allele was not synthesized or was rapidly degraded, probably through nonsense-mediated decay,¹⁶ a cellular mechanism causing the rapid turnover of mRNA that contains nonsense and frame-shift mutations.

Variable Expression of *GNAS1* Mutations and Parental Inheritance Patterns

The same 4-bp deletion found in Families 1, 9, 11, and 18 has been identified as the basis for *GNAS1* haploinsufficiency in several patients with AHO.¹⁷ The 348delC frame-shift mutation identified in two sub-

TABLE 1. *GNAS1* MUTATIONS AND mRNA EXPRESSION IN PATIENTS WITH PROGRESSIVE OSSEOUS HETEROPLASIA (POH).

FAMILY No.	MUTATION*	LOCATION†	mRNA ALLELES‡
1, 9, 11, 18	Frame shift 565–568delGACT	Codon 189–190 (exon 7)	+, +, +, ND
2	Frame shift 1053–1077dupl(25n)	Codon 360 (exon 13)	+ and –
5	Frame shift 725delC	Codon 242 (exon 10)	+
6, 12	Frame shift 348delC	Codon 116 (exon 5)	+, +
7	Frame shift 344–345insT	Codon 115 (exon 5)	ND
8	Frame shift 679–680insC	Codon 227 (exon 9)	+
10	Frame shift 835–839duplAACAG	Codon 280 (exon 10)	+
13	Frame shift 960–961insCT	Codon 321 (exon 11)	ND
14	Substitution IVS 12 –1G→C	Splice acceptor (intron 12)	+ and –

*Each mutation is identified by the complementary DNA nucleotide sequence of *GNAS1*. IVS 12 denotes intron (intervening sequence) 12.

†Codon locations are those of the first codons altered by an insertion or duplication or codons containing deleted nucleotides.

‡For families with POH, Subjects II-1 and III-3 were examined in Family 1; Subject I-1 in Family 2; and Subjects I-1 and II-2 in Family 5. RNA from Families 7, 13, and 18 was not available for testing. A plus sign denotes expression of the normal allele, a minus sign expression of the mutant allele, and ND no data (RNA not available for study).

jects with POH from Families 6 and 12 (Table 1) has also been reported in a patient with AHO.¹⁸ Thus, the identical mutations in *GNAS1* can result in widely varying clinical phenotypes. All other *GNAS1* mutations identified in patients with POH are unique.

Direct evidence of variable expression of the same *GNAS1* mutation was observed within a single family, and the phenotype correlated with the parental origin of the mutant allele (Family 18 in Fig. 2). The proband (Subject II-8) had classic features of POH (severe cutaneous and subcutaneous ossification and progressive heterotopic ossification of skeletal muscle). Four of her five sisters had a milder POH phenotype. The proband and her affected siblings had a 4-bp frame-shift deletion in *GNAS1* exon 7. The clinically unaffected father (Subject I-1) carried the mutation, but the unaffected mother did not, indicating inheritance of the mutant *GNAS1* allele from a father with a nonpenetrant mutation. Nonpenetrance was also evident in Subject I-1 in Family 5. In both cases of fathers with nonpenetrant mutations, the parental origin of the mutated allele could not be determined. In Family 18, three children of the proband's sisters (Subjects III-3, III-7, and III-10 in Fig. 2) exhibited

features of AHO, including traces of subcutaneous ossification. Subcutaneous ossification was also noted in a fourth child (Subject III-6), who died suddenly at five months of age.¹³ The two children available for examination (Subjects III-3 and III-7) carried the *GNASI* mutation. The findings in this family support the hypothesis that the parental origin of the mutant *GNASI* allele determines whether POH or AHO will develop in a child.

DISCUSSION

G proteins are members of a superfamily of guanosine triphosphate-binding proteins.¹⁹ All members of this superfamily bind guanine nucleotides with high affinity and specificity, possess intrinsic guanosine triphosphatase activity, and function as molecular switches: they are “on” in the guanosine triphosphate-bound conformation and “off” after hydrolysis of guanosine triphosphate to guanosine diphosphate. The most clearly defined function of G proteins is in signal transduction. A large variety of extracellular first messengers, such as peptide and glycoprotein hormones, neurotransmitters, growth factors, chemotactic agents, and sensory signals, regulate cellular activity or function by binding to cell-surface receptors that are associated with G proteins. The G proteins act as timing switches to regulate the generation of intracellular second messengers, including cyclic AMP.

During the past decade, G proteins have been the focus of intense investigation, with particular interest in the investigation of G_s , the stimulatory G protein of adenylyl cyclase, as a basis for human disease.¹⁹ At least three disorders with features of dysregulated osteogenesis are associated with somatic or germ-line mutations in *GNASI*, the gene that encodes $G_s\alpha$, the alpha subunit of G_s . McCune-Albright syndrome is caused by postzygotic mutations that activate $G_s\alpha$ and cause constitutive (hormone-independent) activation of adenylyl cyclase,²⁰ whereas AHO⁹ and platelike osteoma cutis²¹ are caused by inactivating germ-line *GNASI* mutations. We determined that another disorder of osteogenesis, POH, is due to inactivating mutations in the same gene.

Phenotypic expression of genetic disorders caused by single-gene mutations can be highly variable, most notably in autosomal dominant conditions.²² Many of these disorders vary, either in the severity of a solitary abnormality or in the characteristic set of seemingly unrelated abnormalities, or in both. Inactivating mutations in *GNASI* have both these effects in AHO. Affected subjects have a wide range of developmental and somatic defects of variable severity, including subcutaneous ossification, skeletal dysmorphism, obesity, mental retardation, and hormone resistance. By contrast, patients with POH have a single charac-

teristic disease manifestation (progressive heterotopic ossification) that can vary in its degree of severity.

In addition to variable expression in POH, we observed nonpenetrance (i.e., the complete failure of disease expression in some carriers of a gene mutation) in two families. Carriers of nonpenetrant *GNASI* mutations could have new mutations with a mosaic distribution that excludes cells that would express disease characteristics. Alternatively, nonpenetrance or variable expression could be due to influences from other genetic loci, epigenetic modifications, or environmental factors.

For several human genetic disorders, expression of the disease phenotype is influenced by whether the disease has been inherited from the father or the mother. Recent studies showing that maternal and paternal alleles of some genes do not function identically have helped clarify this phenomenon, known as imprinting.²³ A consistent difference between AHO and POH is the parental origin of the mutant *GNASI* allele. This is illustrated by Family 18, in which paternal inheritance of the mutant *GNASI* allele resulted in POH, and maternal inheritance resulted in AHO.

Previous clinical and molecular studies⁹ have revealed that maternal transmission of *GNASI* mutations leads to the complete form of AHO, termed pseudohypoparathyroidism type 1a (MIM 103580), in which there is resistance to parathyroid hormone and other hormones whose receptors require $G_s\alpha$ to stimulate adenylyl cyclase. By contrast, paternal inheritance of a *GNASI* mutation causes a less severe form of AHO, termed pseudopseudohypoparathyroidism (MIM 300800), in which the somatic defects are accompanied by normal hormone responsiveness. As in pseudopseudohypoparathyroidism, paternal inheritance of a mutant *GNASI* allele in patients with POH is associated with a lack of hormone resistance, but the two clinical phenotypes are otherwise clearly distinguishable.^{8,9}

Molecular studies of the *GNASI* gene show monoallelic transcript expression according to the parent of origin,²⁴⁻²⁷ a result consistent with parental imprinting. However, the manner of expression is far more complex than anticipated. In addition to a $G_s\alpha$ -specific exon 1, three unique, alternative first exons are spliced to exons 2 through 13 of *GNASI*. One of the alternative exons encodes the neurosecretory protein NESP55 and is expressed exclusively from the maternal allele, whereas the other two alternative first exons are transcribed only from the paternal allele.^{24,25,28} Expression of the $G_s\alpha$ -specific exon 1 appears to be biallelic in most tissues that have been examined,^{24,25,29} although expression exclusively from the maternally derived allele has been documented in some tissues (e.g., murine renal cortex and adipose tissue³⁰ and human pituitary³¹).

Given the complexity of transcript synthesis at the *GNAS1* locus, it is not surprising that a wide variety of phenotypic effects results from *GNAS1* mutations and that the phenotypes are influenced by the parent from whom the mutant allele is inherited. Hormone resistance (such as that in pseudohypoparathyroidism type 1a) is strongly correlated with mutations in the maternally derived allele, indicating that the maternal allele is critical (at least in some tissues) for cellular functions required for signal transduction. In contrast, severe, progressive heterotopic ossification, such as that found in POH, correlates with paternal inheritance of the *GNAS1* mutation, suggesting that the paternal allele specifically influences progressive osteoblastic differentiation, proliferation of cells in soft connective tissues, or both.

Why paternal inheritance of a *GNAS1* mutation should result in pseudopseudohypoparathyroidism in some families and POH in others is unclear. Other phenotypes that have been associated with *GNAS1* inactivation (such as features of AHO — including mild dermal ossification — that occur in both pseudohypoparathyroidism type 1a and pseudopseudohypoparathyroidism) seem to be influenced by *GNAS1* mutations in either the maternal or the paternal allele. Tissue and developmental specificity of imprinting at the *GNAS1* locus is a plausible cause of the disparity among phenotypes. Overlapping patterns of variable expressivity (i.e., a range of phenotypic severity) by *GNAS1* maternal, paternal, and biallelic transcripts may result in a complex set of phenotypes among patients with *GNAS1*-inactivating mutations.

Our findings expand the spectrum of phenotypic variability attributable to mutations in the *GNAS1* gene and establishes *GNAS1* as an important regulator of osteoblastic commitment in nonosteogenic connective tissues. Further investigation into imprinting effects and the regulation and function of the multiple transcripts of the *GNAS1* locus will be required to understand the genotypic complexity and phenotypic variability associated with mutations at this locus.

Supported by grants from the Progressive Osseous Heteroplasia Association, the International Fibrodysplasia Ossificans Progressiva Association, the New Jersey Association of Student Councils, the Ian Cali Fund, the Roemex Fellowship, Shriners Hospitals for Children (85480, to Dr. Whyte), the National Institute of Arthritis and Musculoskeletal and Skin Diseases (R01-AR46831, to Dr. Shore, and R01-AR41916, to Dr. Kaplan), and the National Institute of Diabetes and Digestive and Kidney Diseases (R01-DK34281, to Dr. Levine) and by the Isaac and Rose Nassau Professorship of Orthopaedic Molecular Medicine.

We are indebted to R. Bufo, J.P. Chanoine, J.E. Clarkson, J.M. Connor, N. Esterly, J. Fairly, F. Gannon, L. Gordon, G. Lehine, G.D. MacEwen, T. Malpass, S.P. Robertson, S. Rosenfeld, E. Shinall Miller, and J.A. Urtizberea for valuable discussions and referrals of patients; to J.K. Fang of the University of Pennsylvania School of Veterinary Medicine DNA Sequencing Facility; and to F. Gardner, S. Roth, R. El-

kinson, M. Vamvakis, and J. Peeper for encouragement and support. We dedicate this work to our patients with POH worldwide.

REFERENCES

1. McKusick VA, Francomano CA, Antonarakis SA, et al. Mendelian inheritance in man: a catalog of human genes and genetic disorders. 12th ed. Baltimore: Johns Hopkins University Press, 1998.
2. Kaplan FS, Craver R, MacEwen GD, et al. Progressive osseous heteroplasia: a distinct developmental disorder of heterotopic ossification: two new case reports and follow-up of three previously reported cases. *J Bone Joint Surg Am* 1994;76:425-36.
3. Schmidt AH, Vincent KA, Aiona MD. Hemimelic progressive osseous heteroplasia: a case report. *J Bone Joint Surg Am* 1994;76:907-12.
4. Athanasou NA, Benson MK, Brenton BP, Smith R. Progressive osseous heteroplasia: a case report. *Bone* 1994;15:471-5.
5. Kaplan FS. Skin and bones. *Arch Dermatol* 1996;132:815-8.
6. Urtizberea JA, Testart H, Cartault F, Boccon-Gibod L, Le Merrer M, Kaplan FS. Progressive osseous heteroplasia: report of a family. *J Bone Joint Surg Br* 1998;80:768-71.
7. Rosenfeld SR, Kaplan FS. Progressive osseous heteroplasia in male patients: two new case reports. *Clin Orthop* 1995;317:243-5.
8. Kaplan FS, Shore EM. Progressive osseous heteroplasia. *J Bone Miner Res* 2000;15:2084-94.
9. Jan de Beur SM, Levine MA. Pseudohypoparathyroidism: clinical, biochemical, and molecular features. In: Bilezikian JP, ed. *The parathyroids: basic and clinical concepts*. 2nd ed. San Diego, Calif.: Academic Press, 2001:807-25.
10. Eddy MC, De Beur SM, Yandow SM, et al. Deficiency of the α -subunit of the stimulatory G protein and severe extraskeletal ossification. *J Bone Miner Res* 2000;15:2074-83.
11. Pisani V, Cavallo L, Lospalluti M, Bufo R, Bonifazi E. Primary osteoma cutis. *Pediatr Dermatol News* 1985;4:170-5.
12. Rodriguez-Jurado R, Gonzalez-Crussi F, Poznanski AK. Progressive osseous heteroplasia, uncommon cause of soft tissue ossification: a case report and review of the literature. *Pediatr Pathol Lab Med* 1995;15:813-27.
13. Gardner RJM, Yun K, Craw SM. Familial ectopic ossification. *J Med Genet* 1988;25:113-7.
14. Kozasa T, Itoh H, Tsukamoto T, Kaziro Y. Isolation and characterization of the human Gs alpha gene. *Proc Natl Acad Sci U S A* 1988;85:2081-5.
15. Miric A, Vechio JD, Levine MA. Heterogeneous mutations in the gene encoding the alpha-subunit of the stimulatory G protein of adenyl cyclase in Albright hereditary osteodystrophy. *J Clin Endocrinol Metab* 1993;76:1560-8.
16. Culbertson MR. RNA surveillance: unforeseen consequences for gene expression, inherited genetic disorders and cancer. *Trends Genet* 1999;15:74-80.
17. Weinstein LS, Gejman PV, de Mazancourt P, American N, Spiegel AM. A heterozygous 4-bp deletion mutation in the Gs alpha gene (*GNAS1*) in a patient with Albright hereditary osteodystrophy. *Genomics* 1992;13:1319-21.
18. Shapira H, Mouallem M, Shapiro MS, Weisman Y, Farfel Z. Pseudohypoparathyroidism type 1a: two new heterozygous frameshift mutations in exons 5 and 10 of the Gs alpha gene. *Hum Genet* 1996;97:73-5.
19. Farfel Z, Bourne HR, Iiri T. The expanding spectrum of G protein diseases. *N Engl J Med* 1999;340:1012-20.
20. Whyte MP. Fibrous dysplasia. In: Favas MJ, ed. *Primer on the metabolic bone diseases and disorders of mineral metabolism*. Philadelphia: Lippincott Williams & Wilkins, 1999:384-6.
21. Yeh G, Mathur S, Wivel A, et al. *GNAS1* mutation and *Cbfa1* misexpression in a child with severe congenital platelike osteoma cutis. *J Bone Miner Res* 2000;15:2063-73.
22. Nussbaum RL, McInnes RR, Willard HF. *Thompson & Thompson genetics in medicine*. 6th ed. Philadelphia: W.B. Saunders, 2001.
23. Reik W, Walter J. Genomic imprinting: parental influence on the genome. *Nat Rev Genet* 2001;2:21-32.
24. Hayward BE, Moran V, Strain L, Bonthron DT. Bidirectional imprinting of a single gene: *GNAS1* encodes maternally, paternally, and biallelically derived proteins. *Proc Natl Acad Sci U S A* 1998;95:15475-80.
25. Hayward BE, Kamiya M, Strain L, et al. The human *GNAS1* gene is imprinted and encodes distinct paternally and biallelically expressed G proteins. *Proc Natl Acad Sci U S A* 1998;95:10038-43.
26. Hayward BE, Bonthron DT. An imprinted antisense transcript at the human *GNAS1* locus. *Hum Mol Genet* 2000;9:835-41.
27. Peters J, Wroe SF, Wells CA, et al. A cluster of oppositely imprinted

transcripts at the Gnas locus in the distal imprinting region of mouse chromosome 2. *Proc Natl Acad Sci U S A* 1999;96:3830-5.

28. Liu J, Yu S, Litman D, Chen W, Weinstein LS. Identification of a methylation imprint mark within the mouse Gnas locus. *Mol Cell Biol* 2000;20:5808-17.

29. Campbell R, Gosden CM, Bonthron DT. Parental origin of transcription from the human GNAS1 gene. *J Med Genet* 1994;31:607-14.

30. Yu S, Yu D, Lee E, et al. Variable and tissue-specific hormone resist-

ance in heterotrimeric Gs protein alpha-subunit (Galpha) knockout mice is due to tissue-specific imprinting of the Galpha gene. *Proc Natl Acad Sci U S A* 1998;95:8715-20.

31. Hayward BE, Barlier A, Korbonits M, et al. Imprinting of the G(s)alpha gene GNAS1 in the pathogenesis of acromegaly. *J Clin Invest* 2001;107:R31-R36.

Copyright © 2002 Massachusetts Medical Society.

CORRECTION

**Paternally Inherited Inactivating Mutations of the
GNAS1 Gene in Progressive Osseous Heteroplasia**

Paternally Inherited Inactivating Mutations of the *GNAS1* Gene in Progressive Osseous Heteroplasia . Line 2 of the legend for Figure 3 should have read, "mutated *GNAS1* genomic DNA from patients" rather than "from control subjects." Line 4 of the summary of the article in "This Week in the Journal" should have read, "mild heterotopic ossification" rather than "extensive heterotopic ossification." We regret the errors.