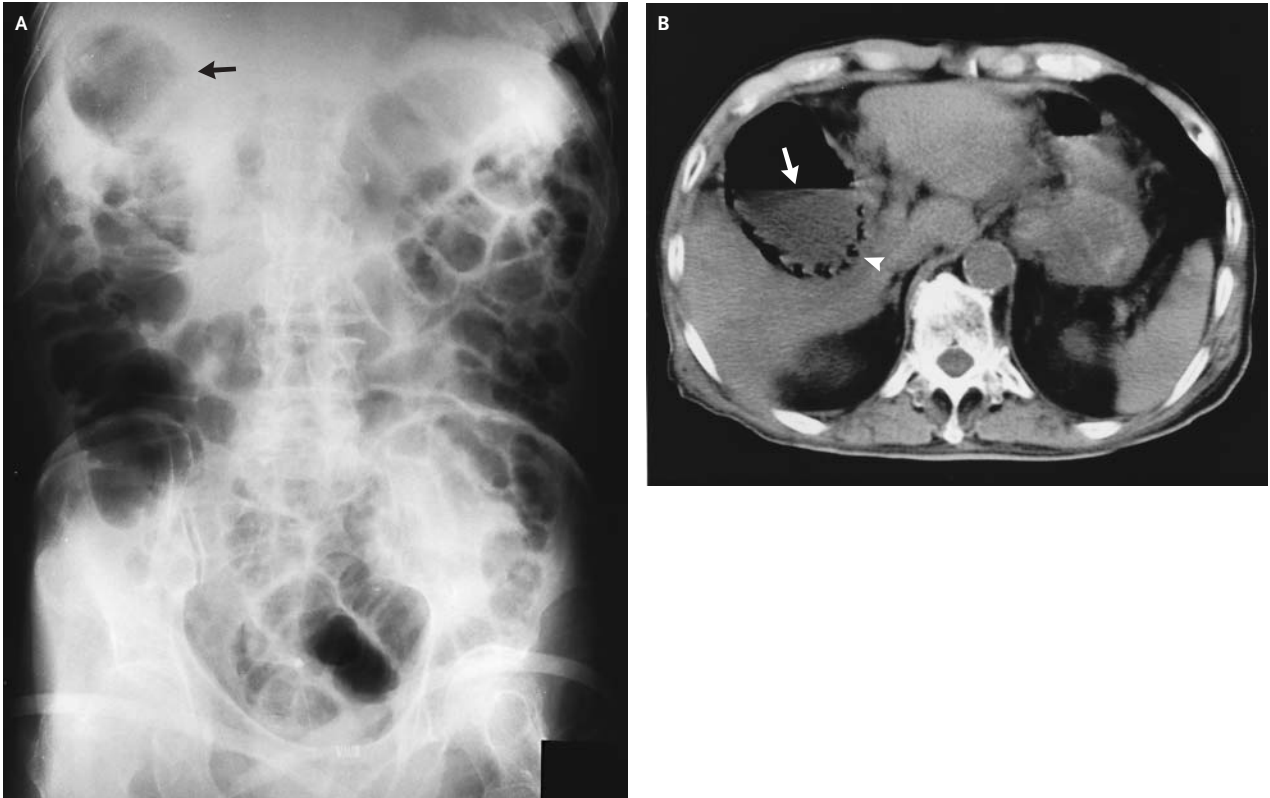


Emphysematous Cholecystitis



AN 83-YEAR-OLD MAN WAS BEING TREATED FOR DIABETES MELLITUS, hypertension, and ischemic heart disease. Cholelithiasis had previously been detected by abdominal ultrasonography. After drinking alcohol at home, the patient had acute abdominal pain. Plain-film radiography of the abdomen (Panel A) showed air (arrow) in the upper right quadrant, and computed tomography (Panel B) showed an air–fluid level (arrow) in the lumen of the gallbladder and gas (arrowhead) within the gallbladder wall. After antibiotic therapy, cholecystectomy and drainage were performed. *Clostridium perfringens* was isolated from the culture of drained biliary fluid. The patient recovered uneventfully.

Copyright © 2003 Massachusetts Medical Society.

Yasuyoshi Sakai, M.D., Ph.D.

Inatsuki Hospital
Fukuoka 820-0207, Japan

An electronic Image in Clinical Medicine (Paelinck B, Dendale PA. Cardiac Tamponade in Dressler's Syndrome. *N Engl J Med* 2003;348:e8) has also been published in this issue and can be seen at <http://www.nejm.org>.