

The NEW ENGLAND JOURNAL of MEDICINE

ESTABLISHED IN 1812

JANUARY 16, 2003

VOL. 348 NO. 3

Imaging Studies after a First Febrile Urinary Tract Infection in Young Children

Alejandro Hoberman, M.D., Martin Charron, M.D., Robert W. Hickey, M.D.,
Marc Baskin, M.D., Diana H. Kearney, R.N., and Ellen R. Wald, M.D.

ABSTRACT

BACKGROUND

Guidelines from the American Academy of Pediatrics recommend obtaining a voiding cystourethrogram and a renal ultrasonogram for young children after a first urinary tract infection; renal scanning with technetium-99m–labeled dimercaptosuccinic acid has also been endorsed by other authorities. We investigated whether imaging studies altered management or improved outcomes in young children with a first febrile urinary tract infection.

METHODS

In a prospective trial involving 309 children (1 to 24 months old), an ultrasonogram and an initial renal scan were obtained within 72 hours after diagnosis, contrast voiding cystourethrography was performed one month later, and renal scanning was repeated six months later.

RESULTS

The ultrasonographic results were normal in 88 percent of the children (272 of 309); the identified abnormalities did not modify management. Acute pyelonephritis was diagnosed in 61 percent of the children (190 of 309). Thirty-nine percent of the children who underwent cystourethrography (117 of 302) had vesicoureteral reflux; 96 percent of these children (112 of 117) had grade I, II, or III vesicoureteral reflux. Repeated scans were obtained for 89 percent of the children (275 of 309); renal scarring was noted in 9.5 percent of these children (26 of 275).

CONCLUSIONS

An ultrasonogram performed at the time of acute illness is of limited value. A voiding cystourethrogram for the identification of reflux is useful only if antimicrobial prophylaxis is effective in reducing reinfections and renal scarring. Renal scans obtained at presentation identify children with acute pyelonephritis, and scans obtained six months later identify those with renal scarring. The routine performance of urinalysis, urine culture, or both during subsequent febrile illnesses in all children with a previous febrile urinary tract infection will probably obviate the need to obtain either early or late scans.

From the Departments of Pediatrics (A.H., R.W.H., E.R.W.) and Radiology (M.C.), University of Pittsburgh School of Medicine and Children's Hospital of Pittsburgh, Pittsburgh; the Department of Pediatrics, Ohio State University and Columbus Children's Hospital, Columbus (R.W.H.); the Department of Pediatrics, Harvard Medical School and Children's Hospital, Boston (M.B.); and the Division of General Academic Pediatrics, Children's Hospital of Pittsburgh, Pittsburgh (D.H.K.). Address reprint requests to Dr. Hoberman at Children's Hospital of Pittsburgh, 3705 5th Ave., Pittsburgh, PA 15213-2583, or at hoberman@chp.edu.

N Engl J Med 2003;348:195-202.

Copyright © 2003 Massachusetts Medical Society.

IMAGING STUDIES ARE THE STANDARD OF care for young children with a first urinary tract infection. The purpose is to identify possible urinary tract abnormalities, such as vesicoureteral reflux, obstruction of the urinary tract, ureteroceles, acute inflammation, and renal scarring, that may predispose the child to recurrent infections or adverse long-term outcomes. Practice guidelines from the American Academy of Pediatrics recommend a voiding cystourethrogram and a renal ultrasonogram after a first urinary tract infection in children 2 to 24 months of age.¹ Although imaging studies are performed routinely, evidence of their value in altering management or improving outcomes is limited.² We assessed the value of routine imaging studies after the diagnosis of a first febrile urinary tract infection in a large cohort of children 1 to 24 months of age.

METHODS

STUDY DESIGN

As part of a multicenter, randomized clinical trial evaluating the efficacy of oral as compared with intravenous antimicrobial agents in children 1 to 24 months of age who had fever, we documented the various imaging studies performed after the diagnosis of a first febrile urinary tract infection. The study, which took place between 1992 and 1997, was approved by the institutional review boards of each of the participating institutions; written informed consent was obtained from the parents of the participants. Children were eligible if they had a rectal temperature of at least 38.3°C at presentation or within 24 hours and if a urinary tract infection was suspected because of the presence of pyuria (10 or more white cells per cubic millimeter in uncentrifuged urine) and bacteriuria (1 or more gram-negative rods per 10 oil-immersion fields in a Gram's-stained smear of uncentrifuged urine).³⁻⁵ Inclusion in the final study group required a positive urine culture (at least 50,000 colony-forming units per milliliter, representing a single pathogen) from a specimen obtained by catheter.

Children randomly assigned to initial intravenous treatment were hospitalized and treated with cefotaxime (Claforan, Aventis; 200 mg per kilogram of body weight per day, in four divided doses) for three days. Subsequently, children received oral cefixime (Suprax, Wyeth-Ayerst; 8 mg per kilogram, once daily) to complete a 14-day course, followed by prophylaxis with cefixime (4 mg per kilogram,

once daily) for 2 weeks, until voiding cystourethrography was performed. Children randomly assigned to oral treatment received cefixime for 14 days (16 mg per kilogram, administered in the emergency department, followed by 8 mg per kilogram once daily for 13 days). After treatment, these children received prophylaxis with cefixime, as described above.

IMAGING STUDIES

Renal scanning with technetium-99m-labeled dimercaptosuccinic acid and renal ultrasonography were performed within 48 hours of diagnosis to determine the presence or absence of acute pyelonephritis and anatomical abnormalities, respectively. Contrast voiding cystourethrography was performed approximately one month after diagnosis, since this constituted the standard of care at participating institutions when the study was conducted. Vesicoureteral reflux was graded according to the classification system of the International Reflux Study Committee; grade I indicates reflux into the proximal ureter without dilatation, grade II reflux into the distal ureter without dilatation, and grades III, IV, and V reflux into the distal ureter with mild, moderate, and severe dilatation, respectively.⁶ Children with vesicoureteral reflux of at least grade II were given prophylactic therapy with either trimethoprim-sulfamethoxazole (5 mg of the trimethoprim component per kilogram) or nitrofurantoin (2 mg per kilogram) once daily for 11 months or until the reflux was classified as grade I or less. Technetium-99m-labeled dimercaptosuccinic acid renal scanning was repeated six months later to determine the incidence and severity of renal scarring.

DEFINITIONS

Technetium-99m-labeled dimercaptosuccinic acid scans were considered normal if homogeneous uptake of the radioisotope was evident throughout the kidneys and the renal contour was preserved. Acute pyelonephritis was defined by the presence of focal or diffuse areas of decreased uptake of labeled dimercaptosuccinic acid without evidence of cortical loss or by the presence of diffusely decreased uptake in an enlarged kidney. Renal scarring was defined by the presence of decreased uptake of labeled dimercaptosuccinic acid associated with loss of the contours of the kidney or by the presence of cortical thinning with decreased volume. The degree of scarring was assessed quantitatively by outlining the scarred area and calculating its ratio to

the total area of the kidney. The scans were interpreted independently by two radiologists who were unaware of the patients' test results or characteristics, using a rating scale described previously.⁷ Discrepancies were resolved by discussion between the evaluators.

LONG-TERM FOLLOW-UP

The children were followed for six months. Urine cultures were obtained routinely at three and six months (for surveillance) and at the time of most febrile illnesses. A history of fever or other signs or symptoms compatible with urinary tract infection was elicited during standardized monthly telephone calls with parents and interim visits.

STATISTICAL ANALYSIS

For categorical variables, the χ^2 test or Fisher's exact test was used; for continuous variables, an independent t-test was used. Independent predictor variables for renal scarring and their interaction were evaluated with use of logistic-regression models. An α value of 0.05 or less was considered to indicate statistical significance.

RESULTS

INITIAL IMAGING STUDIES

A total of 421 children 1 to 24 months of age were eligible for enrollment; 23 parents declined to have their children participate in the study, and 76 children were not enrolled for various reasons (unavailability of the investigator, previous antibiotic therapy, language barrier, refusal by the primary care provider, or out-of-state residence). Thirteen of the remaining 322 children who were initially enrolled because of abnormal findings on urinalysis at the time of presentation had negative urine cultures. Accordingly, they were discharged from the study and did not undergo imaging studies. A total of 309 children (276 girls and 33 boys) are therefore included in the present report.

A renal ultrasonogram and an initial technetium-99m-labeled dimercaptosuccinic acid scintigram were obtained within 48 hours of the diagnosis of a first febrile urinary tract infection in all 309 children. Of the 309 ultrasonograms, 272 (88 percent) were normal; the findings on initial ultrasonography are shown in Table 1. Treatment was not altered by the identification of abnormalities on renal ultrasonography. The initial renal scan demonstrated that 61 percent of the children (190 of 309)

had findings compatible with acute pyelonephritis, and one child had evidence of previous renal scarring; a single scan was considered uninterpretable. The mean percentage of renal parenchymal involvement among children with acute pyelonephritis was 31 percent.

FOLLOW-UP IMAGING STUDIES

Voiding cystourethrography was performed in 98 percent of the children (302 of 309) one month after diagnosis; the results are shown in Table 2. Thirty-nine percent of the children (117 of 302) had evidence of vesicoureteral reflux. In 96 percent of these (112 of 117), the reflux was classified as grade I, II, or III. The proportions of children with an ultrasonogram showing dilatation of the urinary

Table 1. Findings on Renal Ultrasonography in 309 Febrile Children with a First Urinary Tract Infection.*

Finding	No. of Children (%)
Normal	272 (88.0)
Dilated pelvis	13 (4.2)
Pelviciectasis	12 (3.9)
Hydronephrosis	2 (0.6)
Dilated ureter	9 (2.9)
Double collecting system	3 (1.0)
Extrarenal pelvis	1 (0.3)
Calculus	1 (0.3)

* Four children had two anomalies each (dilated pelvis, pelviciectasis, hydronephrosis, or dilated ureter).

Table 2. Findings on Voiding Cystourethrography in 302 Febrile Children with a First Urinary Tract Infection.*

Finding	No. of Children (%)
Normal	185 (61.3)
Vesicoureteral reflux	
Grade I	25 (8.3)
Grade II	42 (13.9)
Grade III	45 (14.9)
Grade IV	5 (1.7)
Grade V	0

* Cystourethrography was not performed in seven children.

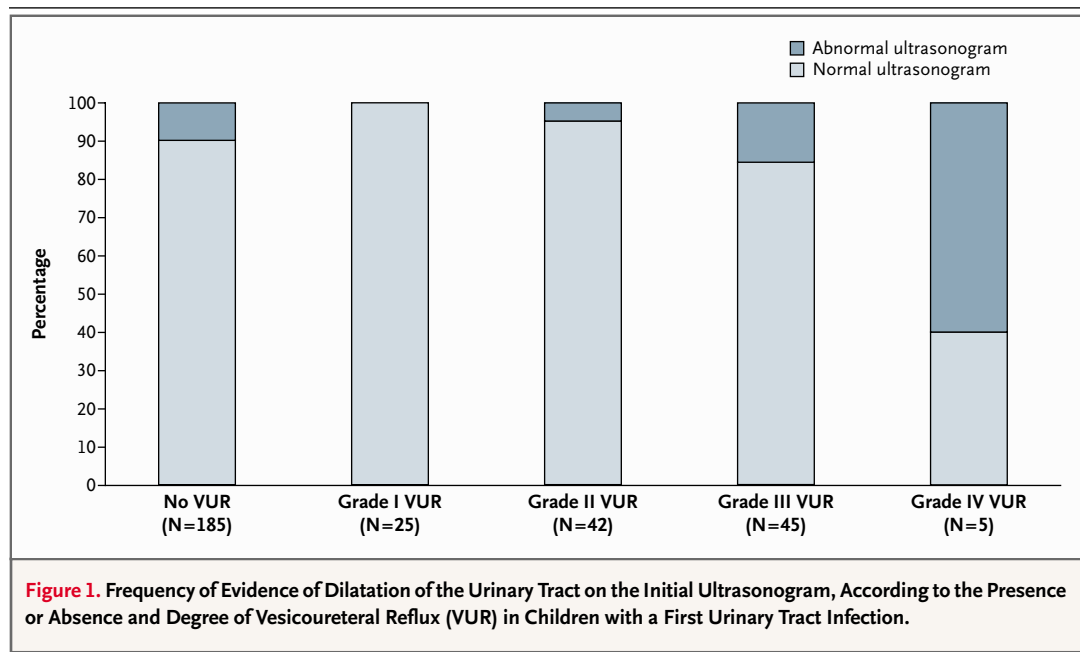
tract, according to the presence and the degree of vesicoureteral reflux, are presented in Figure 1. The sensitivity of evidence of dilatation of the urinary tract on renal ultrasonography for detecting the presence of vesicoureteral reflux on voiding cystourethrography was 0.10, and the positive predictive value was 0.40. Three of the five children with grade IV vesicoureteral reflux had an ultrasonogram showing dilatation of the urinary tract; no cases of grade V vesicoureteral reflux were noted. Although the overall proportion of children with vesicoureteral reflux was similar among those with and those without an ultrasonogram showing dilatation of the urinary tract (12 of 30 vs. 105 of 272, $P=0.96$), vesicoureteral reflux of grade III or IV was more likely to occur among children with abnormal ultrasonographic findings than among those with normal findings (10 of 30 vs. 40 of 272, $P=0.02$) (Fig. 2).

Repeated scintigraphic scanning was performed in 89 percent of the children (275 of 309) six months after entry into the study to detect any renal scarring. A small percentage of renal parenchymal involvement (mean, 8.2 percent) was noted in 9.5 percent of the children (26 of 275). All children whose initial scans were normal had normal scans at follow-up. Fifteen percent of the children (26 of 173) with scintigraphic evidence of acute pyelonephritis at study entry had evidence of renal scarring six months later. Renal scarring was more likely to oc-

cur in children with documented vesicoureteral reflux than in those without vesicoureteral reflux (16 of 109 [15 percent] vs. 10 of 166 [6 percent], $P=0.03$). However, no relation was found between renal scarring and age at diagnosis, duration of fever before the initiation of therapy, or duration of fever after the initiation of therapy (Fig. 3). When independent predictor variables and their interaction were evaluated in logistic-regression models to determine their influence on scarring, only the degree of vesicoureteral reflux was significantly associated with a higher incidence of renal scarring ($P=0.007$).³

DISCUSSION

We analyzed data on a large cohort of children in a primary care setting in whom imaging studies were systematically performed after a first febrile urinary tract infection. Such children are frequently referred for diagnostic imaging of the kidneys and urinary tract, on the assumption that early detection of urologic abnormalities will lead to improved outcomes.² The diagnostic imaging methods that are usually considered include renal ultrasonography, contrast voiding cystourethrography, radionuclide cystography, renal cortical scintigraphy, computed tomography, and magnetic resonance imaging. Although some of these imaging studies are routine-

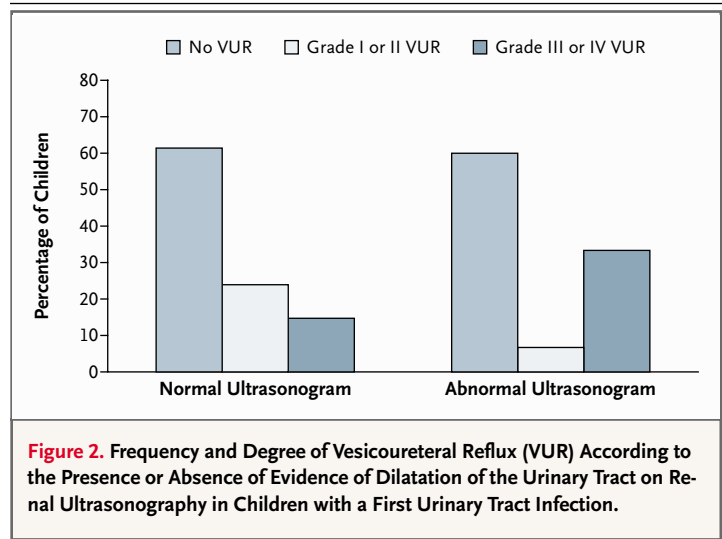


ly performed in children with a first urinary tract infection, there is little evidence that this practice results in prevention of renal scarring, hypertension, or renal failure.

In a review of the literature,² it was noted that controlled clinical trials or analyses evaluating the effect of imaging studies on management were lacking, and substantial methodologic limitations were identified among those that had been published. Many trials and analyses were conducted to evaluate the prevalence of urologic abnormalities in the population studied or the sensitivity and specificity of imaging studies, rather than their value in improving outcomes. Furthermore, they were descriptive in design, and many were marked by potential bias in sampling techniques (e.g., referral for consultation, radiologic investigation, hospitalization, and recurrent urinary tract infection). Because previous investigations have not focused exclusively on first febrile urinary tract infections in a primary care setting, our results may have greater generalizability than earlier findings.²

Renal ultrasonography has completely replaced intravenous pyelography for assessing the gross anatomy of the urinary tract, and it is routinely performed after the diagnosis of a first urinary tract infection. It is a noninvasive test that can demonstrate the size and shape of the kidneys, the presence of duplication and dilatation of the ureters, the presence of ureteroceles, and the existence of gross anatomical abnormalities, such as a horseshoe kidney.⁸ The identification of a nonrefluxing megaureter or ureteropelvic-junction obstruction may lead to surgery; identification of a solitary or dysplastic kidney results in more aggressive management of vesicoureteral reflux. However, ultrasonography is not sensitive enough to detect the presence of hydronephrosis, hydroureter, acute pyelonephritis, or renal scarring consistently.⁹⁻¹⁸ In addition, because of its dynamic nature, vesicoureteral reflux cannot be consistently detected by ultrasonography. In our study, an ultrasonogram showing dilatation of the urinary tract was not helpful in identifying children with grade III or IV vesicoureteral reflux. However, because there were only five children with grade IV vesicoureteral reflux and none with grade V, the validity of renal ultrasonography in identifying such children warrants further study.

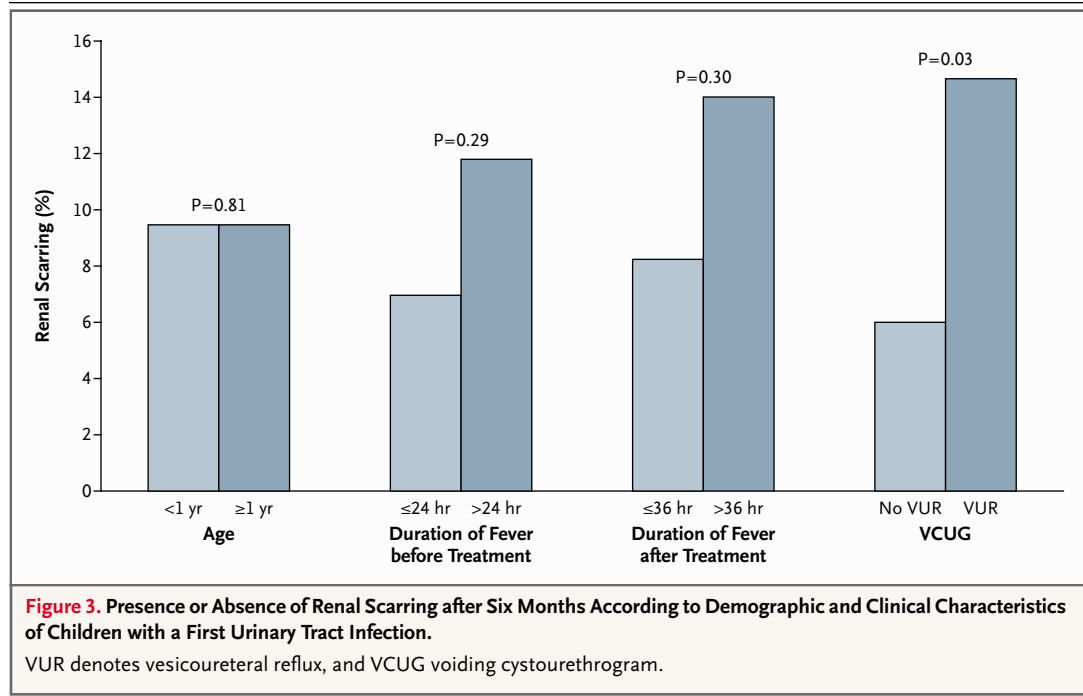
In recent years, the clinical value of routine renal ultrasonography for young children in whom a first urinary tract infection is diagnosed has been questioned because of the limited effect of findings



on clinical management. This lack of effect is probably attributable to the widespread and repetitive use of maternal–fetal ultrasonography, which frequently identifies children with obstructive lesions of the urinary tract in utero.¹⁹⁻²¹ Because ultrasonographic findings in the 309 children in our study who had a first febrile urinary tract infection (in a primary care setting) did not identify obstruction of the urinary tract in any instance, we can be 95 percent confident that the true proportion of children with clinically important findings that would modify management is less than 1 percent.²² Therefore, we do not recommend the routine performance of renal ultrasonography after the diagnosis of a first febrile urinary tract infection in children who have undergone prenatal ultrasonography in an experienced center after 30 to 32 weeks of gestation.

Vesicoureteral reflux, which affects approximately 30 to 40 percent of young children¹ and has been associated with renal scarring, has been an important consideration in the treatment of children with urinary tract infections. A widespread practice has been to initiate long-term prophylactic antimicrobial therapy in children found to have vesicoureteral reflux. However, this empirical approach—which has recently been questioned—was based on an international study conducted in the 1980s that compared medical management (i.e., prophylactic antimicrobial therapy) with surgical management of vesicoureteral reflux and did not include an observation group as a control.

The recommendation of prophylactic antimicrobial therapy is based on the following premises:



coexisting vesicoureteral reflux predisposes children with urinary tract infections to the development of acute pyelonephritis; reflux nephropathy, which leads to renal scarring, is a consequence of infection plus reflux; continuous prophylactic antimicrobial therapy successfully prevents infection until reflux resolves spontaneously or is corrected surgically; and the initiation of treatment after the diagnosis of intercurrent episodes of urinary tract infection in such children will be insufficient to prevent scarring. However, a recent comprehensive analysis of the literature²³ has questioned these assumptions, along with the rationale and need for continuous prophylactic antimicrobial therapy. If it can be shown with certainty in a placebo-controlled study that continuous prophylactic antimicrobial therapy prevents renal scarring in children with vesicoureteral reflux, the necessity and importance of the voiding cystourethrogram will be confirmed. Changing attitudes toward the use of prophylactic antibiotics in general may make it possible to perform a clinical trial evaluating the benefits of continuous prophylactic antimicrobial therapy in children with vesicoureteral reflux.

The role of renal cortical scintigraphy in the treatment of young children with urinary tract infections has not been evaluated systematically. Although renal scintigraphy with technetium-99m-labeled

dimercaptosuccinic acid is a valid diagnostic tool for confirming the presence of acute pyelonephritis and for documenting the presence of renal scarring,^{3,12,24-32} routine use of this imaging method during the acute illness does not alter treatment in the majority of cases. Some experts recommend prophylactic antimicrobial therapy for one year when a scan shows a pattern consistent with acute pyelonephritis; however, the benefits of this strategy have not been evaluated, and it cannot be endorsed at this time. In children two years of age or younger who have a first febrile urinary tract infection, the results of approximately 60 to 65 percent of imaging studies will be abnormal. On the assumption of a sensitivity of 85 to 90 percent, nearly 75 percent of young children with fever and clinically significant bacteriuria will have acute pyelonephritis. It may therefore be reasonable for the clinician to assume that nearly all such children have acute pyelonephritis and treat them accordingly. The most comprehensive strategy is to evaluate aggressively all subsequent episodes of fever in these children by urinalysis,⁴ urine culture, or both to ensure the identification of subsequent urinary tract infections.

The incidence of renal scarring reported here (9.5 percent) is lower than the 30 percent previously reported.^{31,33,34} The relatively low incidence and small size of scars observed in our study may have

resulted from the active surveillance for and treatment of urinary tract infection in young children with fever, as practiced at the participating institutions.³⁵ The fact that the initial scan showed a scar in only one child, rather than in 11 percent of children as reported in previous studies,³³ validates the appropriateness of the criteria used to select a group of children with bona fide first-time febrile urinary tract infection. The long-term implications of small scars identified by renal scintigraphy are unknown. Studies that found an association between scarring early in life and the subsequent development of hypertension, preeclampsia, renal insufficiency, and end-stage renal disease decades later used intravenous pyelography — a method substantially less sensitive than technetium-99m-labeled dimercaptosuccinic acid scanning — and almost certainly identified children with extensive rather than minimal parenchymal damage.^{36,37} A recent study of women with scarring confirmed that renal function was reasonably well preserved and that the incidence of hypertension was lower than had previously been reported.³⁸

In summary, although imaging studies have been considered the standard of care after the diag-

nosis of a first urinary tract infection, the effect of such studies on outcome has been unclear. Our results suggest that renal ultrasonography and renal scanning at the time of the acute illness are of limited value, because they do not provide information that modifies management. The use of voiding cystourethrography (currently performed any time after three to four days of therapy, when increased bladder contractility has resolved) to identify children with vesicoureteral reflux is recommended under the so far unproven assumption that continuous prophylactic antimicrobial therapy is effective in reducing the incidence of reinfection and renal scarring. Renal scans obtained at presentation and six months later identify children with acute pyelonephritis and renal scarring, respectively. However, a strong commitment to the routine performance of urinalysis,⁴ urine culture, or both during subsequent febrile illnesses in all children with a previous febrile urinary tract infection is likely to obviate the need to obtain either early or late scans.

Dr. Hoberman reports having received lecture fees and grant support from GlaxoSmithKline, Pfizer, and Abbott Laboratories. Dr. Charron reports having received grant support from Boston Life Sciences. Dr. Wald reports having received grant support from GlaxoSmithKline and Abbott Laboratories.

REFERENCES

- Downs SM. Technical report: urinary tract infections in febrile infants and young children. *Pediatrics* 1999;103:810. abstract.
- Dick PT, Feldman W. Routine diagnostic imaging for childhood urinary tract infections: a systematic overview. *J Pediatr* 1996;128:15-22.
- Hoberman A, Wald ER, Hickey RW, et al. Oral versus initial intravenous therapy for urinary tract infections in young febrile children. *Pediatrics* 1999;104:79-86.
- Hoberman A, Wald ER, Reynolds EA, Penchansky L, Charron M. Pyuria and bacteriuria in urine specimens obtained by catheter from young children with fever. *J Pediatr* 1994;124:513-9.
- Hoberman A, Wald ER, Penchansky L, Reynolds EA, Young S. Enhanced urinalysis as a screening test for urinary tract infection. *Pediatrics* 1993;91:1196-9.
- Medical versus surgical treatment of primary vesicoureteral reflux: report of the International Reflux Study Committee. *Pediatrics* 1981;67:392-400.
- Patel K, Charron M, Hoberman A, Brown ML, Rogers KD. Intra- and interobserver variability in interpretation of DMSA scans using a set of standardized criteria. *Pediatr Radiol* 1993;23:506-9.
- American Academy of Pediatrics, Committee on Quality Improvement, Subcommittee on Urinary Tract Infection. The diagnosis, treatment, and evaluation of the initial urinary tract infection in febrile infants and young children. *Pediatrics* 1999;103:843-52. [Errata, *Pediatrics* 1999;103:1052, 1999;104:118, 2000;105:141.]
- Foresman WH, Hulbert WC Jr, Rabinowitz R. Does urinary tract ultrasonography at hospitalization for acute pyelonephritis predict vesicoureteral reflux? *J Urol* 2001;165:2232-4.
- Sreenarasimhaiah V, Alon US. Uroradiologic evaluation of children with urinary tract infection: are both ultrasonography and renal cortical scintigraphy necessary? *J Pediatr* 1995;127:373-7.
- Jakobsson B, Nolstedt L, Svensson L, Soderlundh S, Berg U. ^{99m}Tc-dimercaptosuccinic acid scan in the diagnosis of acute pyelonephritis in children: relation to clinical and radiological findings. *Pediatr Nephrol* 1992;6:328-34.
- Jakobsson B, Soderlundh S, Berg U. Diagnostic significance of ^{99m}Tc-dimercaptosuccinic acid scintigraphy in urinary tract infection. *Arch Dis Child* 1992;67:1338-42.
- Biggi A, Dardanelli L, Pomero G, et al. Acute renal cortical scintigraphy in children with a first urinary tract infection. *Pediatr Nephrol* 2001;16:733-8.
- Kass EJ, Fink-Bennett D, Cacciarelli AA, Balon H, Pavlock S. The sensitivity of renal scintigraphy and sonography in detecting nonobstructive acute pyelonephritis. *J Urol* 1992;148:606-8.
- Bjorgvinsson E, Majd M, Egli KD. Diagnosis of acute pyelonephritis in children: comparison of sonography and ^{99m}Tc-DMSA scintigraphy. *AJR Am J Roentgenol* 1991;157:539-43.
- Lavocat MP, Granjon D, Allard D, Gay C, Freycon MT, Dubois F. Imaging of pyelonephritis. *Pediatr Radiol* 1997;27:159-65.
- Mastin ST, Drane WE, Irvani A. TC-^{99m}DMSA SPECT imaging in patients with acute symptoms or history of UTI: comparison with ultrasonography. *Clin Nucl Med* 1995;20:407-12.
- Nguyen HT, Bauer SB, Peters CA, et al. ^{99m}Tc-dimercaptosuccinic acid renal scintigraphy abnormalities in infants with sterile high grade vesicoureteral reflux. *J Urol* 2000;164:1674-8.
- Alon US, Ganapathy S. Should renal ultrasonography be done routinely in children with first urinary tract infection? *Clin Pediatr (Phila)* 1999;38:21-5.
- Morin L, Cendron M, Crombleholme RM, Garmel SH, Klauber GT, Alton ME. Minimal hydronephrosis in the fetus: clinical significance and implications for management. *J Urol* 1996;155:2047-9.
- Fine RN. Diagnosis and treatment of fetal urinary tract abnormalities. *J Pediatr* 1992;121:333-41.

22. Hanley JA, Lippman-Hand A. If nothing goes wrong, is everything all right? Interpreting zero numerators. *JAMA* 1983;249:1743-5.
23. Williams G, Lee A, Craig J. Antibiotics for the prevention of urinary tract infection in children: a systematic review of randomized controlled trials. *J Pediatr* 2001;138:868-74.
24. Benador D, Benador N, Slosman DO, Nussle D, Mermillod B, Girardin E. Cortical scintigraphy in the evaluation of renal parenchymal changes in children with pyelonephritis. *J Pediatr* 1994;124:17-20.
25. Melis K, Vandevivere J, Hoskens C, Vervaet A, Sand A, Van Acker KJ. Involvement of the renal parenchyma in acute urinary tract infection: the contribution of ^{99m}Tc dimercaptosuccinic acid scan. *Eur J Pediatr* 1992;151:536-9.
26. Verber IG, Strudley MR, Meller ST. ^{99m}Tc dimercaptosuccinic acid (DMSA) scan as first investigation of urinary tract infection. *Arch Dis Child* 1988;63:1320-5.
27. Verboven J, Ingels M, Delree M, Piepsz A. ^{99m}Tc-DMSA scintigraphy in acute urinary tract infection in children. *Pediatr Radiol* 1990;20:540-2.
28. Rosenberg AR, Rossleigh MA, Brydon MP, Bass SJ, Leighton DM, Farnsworth RH. Evaluation of acute urinary tract infection in children by dimercaptosuccinic acid scintigraphy: a prospective study. *J Urol* 1992;148:1746-9.
29. Hoberman A, Wald ER. Diagnosis of urinary tract infection in children. *Am Fam Physician* 1998;57:2337-8, 2340.
30. Goldraich NP, Ramos OL, Goldraich IH. Urography versus DMSA scan in children with vesicoureteric reflux. *Pediatr Nephrol* 1989;3:1-5.
31. Jakobsson B, Berg U, Svensson L. Renal scarring after acute pyelonephritis. *Arch Dis Child* 1994;70:111-5.
32. Jakobsson B, Svensson L. Transient pyelonephritic changes on ^{99m}Tc dimercaptosuccinic acid scan for at least five months after infection. *Acta Paediatr* 1997;86:803-7.
33. Rushton HG, Majd M, Jantusch B, Wiedermann BL, Belman AB. Renal scarring following reflux and nonreflux pyelonephritis in children: evaluation with ^{99m}Tc dimercaptosuccinic acid scintigraphy. *J Urol* 1992;147:1327-32. [Erratum, *J Urol* 1992;148:898.]
34. Stokland E, Hellstrom M, Jacobsson B, Jodal U, Sixt R. Renal damage one year after first urinary tract infection: role of dimercaptosuccinic acid scintigraphy. *J Pediatr* 1996;129:815-20.
35. Black WC, Welch HG. Advances in diagnostic imaging and overestimations of disease prevalence and the benefits of therapy. *N Engl J Med* 1993;328:1237-43.
36. Jacobson SH, Eklof O, Eriksson CG, Lins LE, Tidgren B, Winberg J. Development of hypertension and uraemia after pyelonephritis in childhood: 27 year follow-up. *BMJ* 1989;299:703-6.
37. Jacobson SH, Eklof O, Lins LE, Wikstad I, Winberg J. Long-term prognosis of post-infectious renal scarring in relation to radiologic findings in childhood — a 27-year follow-up. *Pediatr Nephrol* 1992;6:19-24.
38. Martinell J, Lidin-Janson G, Jagenburg R, Sivertsson R, Claesson I, Jodal U. Girls prone to urinary infections followed into adulthood: indices of renal disease. *Pediatr Nephrol* 1996;10:139-42.

Copyright © 2003 Massachusetts Medical Society.

COLLECTIONS OF ARTICLES ON THE JOURNAL'S WEB SITE

The Journal's Web site (www.nejm.org) sorts published articles into 51 distinct clinical collections, which are listed on the home page and can be used as convenient entry points to clinical content. In each collection, articles are cited in reverse chronological order, with the most recent first.