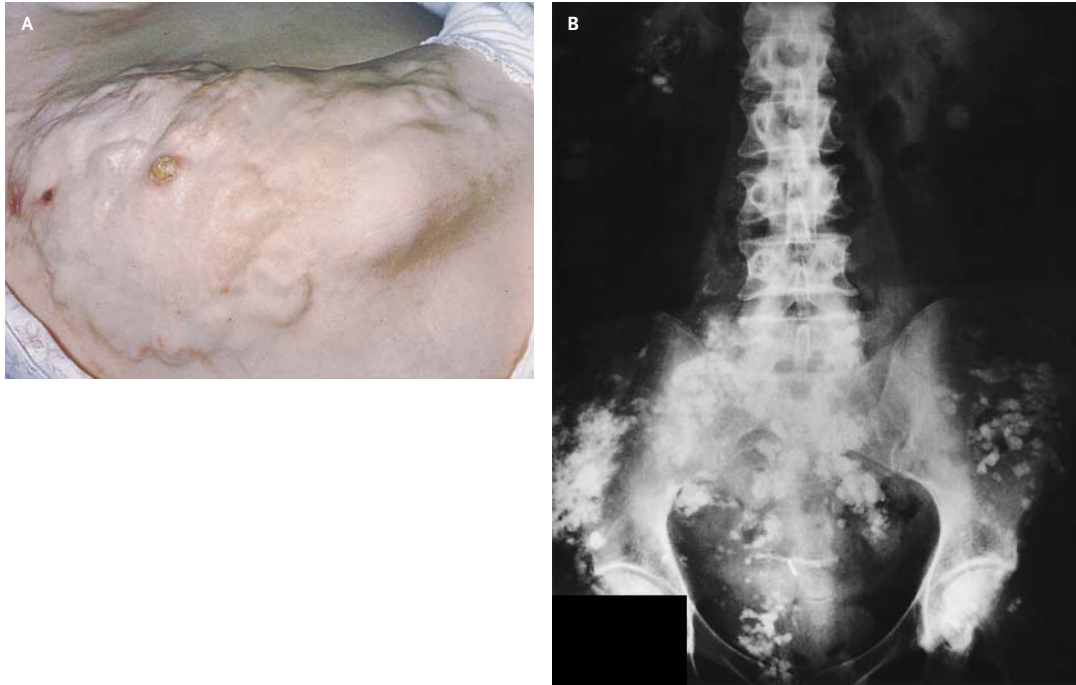


A Medical Mystery



Nicholas Magee, M.R.C.P.
Rory Convery, M.R.C.P.

Craigavon Area Hospital
Portadown BT63 5QQ, Northern Ireland

A 48-YEAR-OLD WOMAN HAD A 30-YEAR HISTORY OF DERMATOMYOSITIS treated with prednisolone. She was admitted for depression and nausea. Examination revealed multiple craggy skin nodules, shown on the right flank (Panel A). Her serum calcium level was normal. An abdominal radiograph was obtained (Panel B). What is your diagnosis?

Editor's note: We invite our readers to submit their answers at <http://nejm.org/mystery>. We will publish the diagnosis in the Correspondence section of the November 13, 2003, issue and e-mail it to everyone who submits an answer. All answers must be received by October 9, 2003.

Copyright © 2003 Massachusetts Medical Society.