

ORIGINAL ARTICLE

A Randomized Comparison of Sentinel-Node Biopsy with Routine Axillary Dissection in Breast Cancer

Umberto Veronesi, M.D., Giovanni Paganelli, M.D., Giuseppe Viale, F.R.C.Path., Alberto Luini, M.D., Stefano Zurrada, M.D., Viviana Galimberti, M.D., Mattia Intra, M.D., Paolo Veronesi, M.D., Chris Robertson, Ph.D., Patrick Maisonneuve, Eng., Giuseppe Renne, M.D., Concetta De Cicco, M.D., Francesca De Lucia, M.D., and Roberto Gennari, M.D.

ABSTRACT

From the Divisions of Senology (U.V., A.L., S.Z., V.G., M.I., P.V., R.G.), Nuclear Medicine (G.P., C.D.), Pathology (G.V., G.R.), Epidemiology (C.R., P.M.), and Anaesthesiology (F.D.), European Institute of Oncology; and the University of Milan School of Medicine (G.V.) — both in Milan, Italy. Address reprint requests to Dr. Umberto Veronesi at the Istituto Europeo di Oncologia, Via G. Ripamonti 435, 20141 Milan, Italy, or at umberto.veronesi@ieo.it.

N Engl J Med 2003;349:546-53.

Copyright © 2003 Massachusetts Medical Society.

BACKGROUND

Although numerous studies have shown that the status of the sentinel node is an accurate predictor of the status of the axillary nodes in breast cancer, the efficacy and safety of sentinel-node biopsy require validation.

METHODS

From March 1998 to December 1999, we randomly assigned 516 patients with primary breast cancer in whom the tumor was less than or equal to 2 cm in diameter either to sentinel-node biopsy and total axillary dissection (the axillary-dissection group) or to sentinel-node biopsy followed by axillary dissection only if the sentinel node contained metastases (the sentinel-node group).

RESULTS

The number of sentinel nodes found was the same in the two groups. A sentinel node was positive in 83 of the 257 patients in the axillary-dissection group (32.3 percent), and in 92 of the 259 patients in the sentinel-node group (35.5 percent). In the axillary-dissection group, the overall accuracy of the sentinel-node status was 96.9 percent, the sensitivity 91.2 percent, and the specificity 100 percent. There was less pain and better arm mobility in the patients who underwent sentinel-node biopsy only than in those who also underwent axillary dissection. There were 15 events associated with breast cancer in the axillary-dissection group and 10 such events in the sentinel-node group. Among the 167 patients who did not undergo axillary dissection, there were no cases of overt axillary metastasis during follow-up.

CONCLUSIONS

Sentinel-node biopsy is a safe and accurate method of screening the axillary nodes for metastasis in women with a small breast cancer.

MODERN SCREENING METHODS MAKE it possible to diagnose breast cancer at an early stage, when the axillary lymph nodes are free of metastases. As a result, routine axillary dissection may constitute excessive treatment. The technique of the sentinel-node biopsy was developed to provide surgeons with information that allows axillary dissection to be avoided if the sentinel node is negative. Numerous studies have shown that the findings in the sentinel node accurately predict the status of the other axillary nodes.¹⁻³ Nevertheless, the efficacy and safety of this method require validation.

We performed a randomized comparison of sentinel-node biopsy followed by routine axillary dissection with sentinel-node biopsy followed by axillary dissection only if, on intraoperative histologic examination, the sentinel node was found to be positive.

METHODS

STUDY DESIGN AND MAIN END POINTS

The study was approved by the ethics committee of the European Institute of Oncology. It was a single-center, randomized trial involving two study groups. Patients with primary breast cancer in whom the tumor was less than or equal to 2 cm in diameter were randomly assigned to undergo, after breast-conserving surgery, either sentinel-node biopsy and total axillary dissection (the axillary-dissection group) or sentinel-node biopsy followed by axillary dissection only if the sentinel node contained metastatic breast cancer (the sentinel-node group). The primary end point of the study was the predictive power of the status of the sentinel node, measured in terms of the percentage of cases of axillary involvement detected by sentinel-node biopsy in relation to the percentage found by routine axillary dissection. Additional end points were indicators of the quality of life, the number of axillary-node metastases appearing during follow-up in patients in the sentinel-node group with a negative sentinel node, and disease-free and overall survival.

PATIENTS

Patients 40 to 75 years of age with invasive breast carcinoma and no history of another cancer except skin cancer were eligible for enrollment. Patients who had multicentric cancer or who had previously undergone excisional biopsy were not eligible.

Between March 1998 and December 1999, 532

of 649 consecutive patients were randomly assigned to one of the two study groups. Of the other 117 patients, 78 were deemed ineligible, 25 declined to undergo randomization, and 14 did not undergo randomization for other reasons. Of the 532 randomized patients, 16 were not able to be evaluated (Table 1). Table 2 summarizes the characteristics of the remaining 516 patients.

All the patients were informed of the aims of the study, the potential effects of the procedures, the risks associated with surgery, and the meaning of the randomization. All the patients signed a consent form approved by the institutional ethics committee (an institutional review board) before the operation.

LOCALIZATION OF THE SENTINEL NODE

All 516 patients were scheduled to undergo surgery early in the morning. In 410 of them (79 percent),

Table 1. Numbers of Patients Eligible for Enrollment, Randomly Assigned to a Study Group, and Able to Be Evaluated.

Patients	No. of Patients
Initially considered for enrollment	649
Not eligible	78
Noninvasive breast cancer	12
Tumor diameter >2 cm	32
Multicentric disease	26
Sentinel node not revealed by scintigraphy	8
Eligible for enrollment	571
Not randomly assigned to a study group	39
Patient's decision	25
Sentinel node not evident on preoperative probe-guided inspection	3
Frozen sectioning not feasible	3
Other	8
Randomly assigned to a study group	532
Not able to be evaluated	16
Multicentric, bilateral, or extensive multifocal disease	5
Sentinel node not identified at surgery	5
Benign lesion on final histologic examination	4
Metastatic disease	2
Able to be evaluated	516
Axillary-dissection group	257
Sentinel-node group	259

Table 2. Characteristics of the Patients in the Two Study Groups.*

Characteristic	Axillary- Dissection Group (N=257)	Sentinel- Node Group (N=259)	Total (N=516)	P Value
	<i>no. of patients (%)</i>			
Age				0.74
40–45 yr	35 (13.6)	32 (12.4)	67 (13.0)	
46–55 yr	88 (34.2)	99 (38.2)	187 (36.2)	
56–65 yr	92 (35.8)	92 (35.5)	184 (35.7)	
66–75 yr	42 (16.3)	36 (13.9)	78 (15.1)	
Diameter of tumor				0.90
<1.0 cm	65 (25.3)	65 (25.1)	130 (25.2)	
1.1–1.5 cm	123 (47.9)	120 (46.3)	243 (47.1)	
>1.5 cm	69 (26.8)	74 (28.6)	143 (27.7)	
Site of tumor				0.84
Outer quadrant	187 (72.8)	186 (71.8)	373 (72.3)	
Inner or central quadrant	70 (27.2)	73 (28.2)	143 (27.7)	
Histologic type				0.63
Ductal infiltrating	212 (82.5)	209 (80.7)	421 (81.6)	
Lobular infiltrating	20 (7.8)	18 (6.9)	38 (7.4)	
Other	25 (9.7)	32 (12.4)	57 (11.0)	
Estrogen-receptor status†				1.00
Positive	236 (91.8)	237 (91.9)	473 (91.8)	
Negative	21 (8.2)	21 (8.1)	42 (8.2)	
Rate of proliferation‡				0.78
<20% of nuclei dividing	166 (64.6)	170 (65.9)	336 (65.2)	
≥20% of nuclei dividing	91 (35.4)	88 (34.1)	179 (34.8)	
Tumor grade§				0.68
I	81 (31.9)	82 (31.9)	163 (31.9)	
II	119 (46.9)	128 (49.8)	247 (48.3)	
III	54 (21.3)	47 (18.3)	101 (19.8)	
Peritumoral vascular invasion				1.00
Yes	43 (16.7)	44 (17.0)	87 (16.9)	
No	214 (83.3)	215 (83.0)	429 (83.1)	

* Because of rounding, not all percentages total 100.

† Estrogen-receptor status was not determined in one patient in the sentinel-node group.

‡ The rate of proliferation was measured by determining the percentage of nuclei in which labeled antigen Ki-67 (a marker of cell division) was expressed. It was not measured in one patient in the sentinel-node group.

§ Tumors were graded according to the system of Elston and Ellis,⁴ where I indicates well differentiated, II moderately differentiated, and III poorly differentiated. The grade was not available for three patients in the axillary-dissection group and two patients in the sentinel-node group.

radioactive tracer was injected during the evening before surgery; in the other 106 patients (21 percent) radioactive tracer was injected on the day of surgery. Five to 10 MBq of technetium-99m-labeled particles of colloidal human albumin (each 50 to 200 nm in diameter) in 0.2 ml of saline was injected close to the tumor.⁵ Injection was subdermal if the tumor was superficial and peritumoral if it was deep. Anterior and anterior-oblique lymphoscintigraphic projections of the breast and axilla were subsequently obtained to determine the exact position of the sentinel node.

Four to 20 hours after the injection of tracer, sentinel-node biopsy was performed during breast surgery. A gamma-ray-detecting probe in a sterile glove was used to identify the radioactive sentinel node and facilitate its removal.

SURGERY

All the patients underwent quadrantectomy or wide resection, immediately followed by sentinel-node biopsy. In the operating room, patients were randomly assigned to one of the two study groups after it was verified that a sentinel node could be detected by the gamma probe and after the macroscopical size of the tumor was determined. The node was removed through the incision used for tumor resection if the tumor was in the upper outer quadrant and through a separate, axillary incision if the tumor was in any other quadrant. The removed sentinel node was sent for immediate frozen-section examination.

In the patients assigned to the axillary-dissection group, sentinel-node biopsy was immediately followed by complete axillary dissection.⁶ In patients in the sentinel-node group, the next event depended on the result of the intraoperative pathological examination of the sentinel node. If the node was negative for metastasis, the operation was concluded at that point; if the node contained a metastasis, complete axillary dissection was performed immediately. In both the patients in the sentinel-node group with a positive node and in all the patients in the axillary-dissection group, all the axillary nodes, at all three Berg levels, were removed. According to Berg, the axillary lymph nodes are divided into three levels according to location: lateral (first level), posterior (second level), or medial (third level) to the minor pectoralis muscle.⁷

The patients who underwent axillary dissection stayed in the hospital an average of 4.3 days, whereas those who underwent only sentinel-node biopsy stayed an average of 2.1 days.

PATHOLOGICAL EXAMINATION

The sentinel node was bisected along its major axis, embedded (cut surface up) in optimal-cutting-temperature compound (CellPath), and frozen in isopentane cooled with liquid nitrogen. Lymph nodes less than 5 mm in diameter were embedded and frozen uncut.⁸ If more than one sentinel lymph node was obtained from a patient, all the nodes were examined in this way.

For each node that was large enough to be cut, 15 pairs of frozen sections, each 4 μ m thick, were cut at 50- μ m intervals in each half of the node, amounting to about 60 sections per node. If residual tissue was left, additional pairs of sections were cut at 100- μ m intervals until the lymph node had been sampled completely. One section in each pair of sections was stained with hematoxylin and eosin. If the result was ambiguous, the other section was stained for cytokeratins by means of a rapid method (EPOS Cytokeratin reagent with HRP, Dako) and stained for the monoclonal antibody MNF116.⁸

The lymph nodes removed during conventional axillary dissection were examined by standard techniques. Nodes greater than 5 mm in diameter were bisected; those less than or equal to 5 mm in diameter were fixed and embedded uncut. Three to six sections were obtained from each lymph node at different levels 100 to 500 μ m apart and stained with hematoxylin and eosin.

ADJUVANT TREATMENT

All the patients received radiation to the ipsilateral breast over a period of eight weeks. A dose of 50 Gy was delivered through two opposed tangential fields with high-energy photons. A 10-Gy boost was given to the skin surrounding the surgical scar. Patients with unfavorable prognostic characteristics were given systemic adjuvant therapy according to the standard protocols used at the European Institute of Oncology.

EVALUATION OF SIDE EFFECTS

The evaluation of side effects included 100 consecutive patients from the axillary-dissection group and 100 consecutive patients from the sentinel-node group who did not undergo total axillary dissection because the sentinel node was negative for metastasis. These 200 patients were interviewed by physicians from the Breast Department 6 months and 24 months after surgery and were asked to complete a questionnaire concerning the intensity of pain, the presence or absence of paresthesias, the extent of

arm mobility (on a scale from 0 [severe restriction] to 100 [no restriction]), and the appearance of the axillary scar. At the same evaluation the circumference of the operated arm was measured and compared with that of the contralateral arm.

STATISTICAL ANALYSIS

One aim of the study was to estimate the percentage of patients in the sentinel-node group whose sentinel node was negative for metastasis but in whom overt axillary nodal metastases developed within five years after surgery. Assuming that 30 percent of 250 recruited patients would have a positive sentinel node, we expected 175 patients to have a negative sentinel node. On the basis of data from a previous study,⁹ we expected axillary metastases to develop in 5 percent of those with a negative sentinel node. The study had 84 percent power to distinguish between an acceptable percentage (5 percent) and an unacceptable percentage (10 percent) of women with nodal metastases at five years; we considered 10 percent the probable maximal percentage. A sensitivity analysis of the power of this one-sided test showed that it varied between 77 percent and 91 percent for a range of acceptable expected percentages less than 5 percent.

One-sided tests and confidence intervals were used because we were interested only in seeing whether the percentage of women with overt nodal metastases in the sentinel-node group was greater than specified values. All P values were two-sided. The overall accuracy of the status of the sentinel node in the axillary-dissection group was defined as the rate of correct classification of patients, on the basis of this status, as having or as not having axillary metastases.

Associations between the status of the axillary nodes and the characteristics of the primary tumor were assessed by means of Fisher's exact test.¹⁰ Logistic-regression methods were used to adjust for the effects of the prognostic factors. Confidence intervals were calculated by the exact binomial method. The log-rank test was used to compare curves representing disease-free survival. All the calculations were carried out using S-Plus 2000, version 3.¹¹

RESULTS

IDENTIFICATION OF THE SENTINEL NODE

Between March 1998 and December 1999, 649 consecutive patients underwent scintigraphy after the

injection of radiolabeled albumin as a prelude to sentinel-node biopsy. In eight patients (1.2 percent), scintigraphy revealed no uptake of radioactivity to the axilla; these patients were considered ineligible.

Seventy other patients also proved ineligible. Of the 571 eligible patients, 39 (6.8 percent) were not randomly assigned to a study group, either because they chose not to participate (25 patients) or because other factors precluded their participation (14 patients). Of the 532 patients who were randomly assigned to a study group, 16 (3.0 percent) could not be evaluated, for various reasons (Table 1).

A total of 429 sentinel nodes were removed and examined from the 257 patients in the axillary-dissection group and 424 from the 259 patients in the sentinel-node group. A mean of 24 nonsentinel axillary nodes were removed in both groups.

DETECTION OF POSITIVE AXILLARY NODES

The primary end point of the study was the capacity of the sentinel-node biopsy to predict the presence or absence of axillary nodes positive for metastasis. Of the 257 patients in the axillary-dissection group, 83 had a positive sentinel node (32.3 percent; 95 percent confidence interval, 26.6 to 38.4) and 174 had a negative sentinel node (67.7 percent). Of the 259 patients in the sentinel-node group, 92 had a positive sentinel node (35.5 percent; 95 percent confidence interval, 29.7 to 41.7), and 167 had a negative sentinel node (64.5 percent; 95 percent confidence interval, 58.3 to 70.3).

In the axillary-dissection group 8 of 174 patients with negative sentinel nodes (4.6 percent; 95 percent confidence interval, 2.0 to 8.9) were subsequently found to have metastatic disease in the axillary nodes; in 2 of these patients, there was micrometastatic disease in only one axillary node. The overall accuracy of the sentinel-node status in the axillary-dissection group was therefore 96.9 percent (in that the results were accurate in 249 of 257 patients), the sensitivity was 91.2 percent (83 of 91 patients with positive nodes were identified), and the specificity was 100 percent. The false negative rate of 8.8 percent (8 of 91 patients with positive nodes were not identified) (95 percent confidence interval, 3.9 to 16.6) and the negative predictive value of 95.4 percent (95 percent confidence interval, 91.1 to 98.0) are consistent with data from previous studies.^{1-3,9}

MICROMETASTASIS

In 60 of the 175 patients with a positive sentinel node, only micrometastases (foci of metastatic cells ≤ 2 mm in diameter) were found. In the axillary-dissection group, 29 patients had a micrometastatic sentinel node; in 24 of these patients, all the other

Table 3. Side Effects in the Two Study Groups.

Side Effect	Axillary-Dissection Group (N=100)		Sentinel-Node Group (N=100)	
	<i>no. of patients</i>			
	6 mo	24 mo	6 mo	24 mo
Axillary pain*				
No	9	61	84	92
Yes, sporadic	72	34	14	7
Yes, continuous	19	5	2	1
Numbness or paresthesias on operated side†				
No	15	32	98	99
Yes	85	68	2	1
Arm mobility‡				
80–100%	73	79	100	100
60–79%	22	18	0	0
40–59%	5	2	0	0
20–39%	0	1	0	0
<20%	0	0	0	0
Aesthetic appearance of axillary scar§				
Good	91	85	98	100
Bad	9	15	2	0
Arm swelling (difference in circumference)¶				
No difference	31	25	89	93
<1 cm	44	38	11	6
1–2 cm	17	25	0	1
>2 cm	8	12	0	0

* Postoperative axillary pain was evaluated as continuous (lasting >50 percent of the day), sporadic, or absent.
 † Numbness and paresthesias were assessed by comparing skin sensitivity on the inner and outer upper arms, axillae, and chest wall on the operated side with that on the untreated side. Sensitivity was recorded as either the presence or absence of numbness.
 ‡ Arm mobility was judged by asking the patient to assign the restriction in motion in the operated arm a value on a scale of 0 percent (severe restriction) to 100 percent (no restriction).
 § The appearance of the axillary scar was judged by asking the patient simply to say whether the result was good or bad.
 ¶ Arm swelling and edema were assessed by comparing the circumference (in centimeters) of the treated arm 15 cm above the lateral epicondyle with that of the untreated arm.

axillary nodes were negative, and in 5, only one other node was positive. In the sentinel-node group, 31 patients had a micrometastatic sentinel node; in 26 of these patients, all the other axillary nodes were negative, and in 5, only one other node was positive.

SIDE EFFECTS AND UNFAVORABLE EVENTS

Side effects are listed in Table 3. The patients who underwent only sentinel-node biopsy had less pain and numbness and better arm mobility than those who underwent axillary-node dissection as well. They also had less arm swelling than those who underwent immediate axillary-node dissection.

The 516 patients were followed for a median of 46 months. As of the most recent follow-up, there have been 34 events (21 in the axillary-dissection group and 13 in the sentinel-node group; $P=0.13$ by the log-rank test) (Table 4). Of the 25 events associated with breast cancer, 15 occurred in the axillary-dissection group (recurrence in the ipsilateral breast in 1, a tumor in the contralateral breast in 2, an axillary metastasis in 2, and distant metastasis in 10), and 10 occurred in the sentinel-node group (recurrence in the ipsilateral breast in 1, a tumor in the contralateral breast in 3, and distant metastasis in 6) ($P=0.26$ by the log-rank test) (Fig. 1). In addition, other primary tumors developed in six patients in the axillary-dissection group and in three in the sentinel-node group (Table 4). As of the most recent follow-up, axillary metastasis has not been detected by physical or ultrasonographic examination in any of the patients.

Thus far, the rate of events associated with breast cancer is 16.4 per 1000 per year (95 percent confidence interval, 9.2 to 26.9) in the axillary-dissection group and 10.1 per 1000 per year (95 percent confidence interval, 4.9 to 18.5) in the sentinel-node group. Eight patients have died, six of them in the axillary-dissection group (two from metastatic breast cancer) and two of them in the sentinel-node group (one from metastatic breast cancer) ($P=0.15$ by the log-rank test). There was no statistically significant difference between the two groups in the rate of overall survival (Fig. 2).

DISCUSSION

The aim of this study was to determine the ability of sentinel-node biopsy to reduce the need for complete axillary dissection in women with breast cancer. In most cases, lymphatic spread within the axilla is orderly, proceeding from the first Berg level to the

Table 4. Unfavorable Events and Deaths in the Two Study Groups.

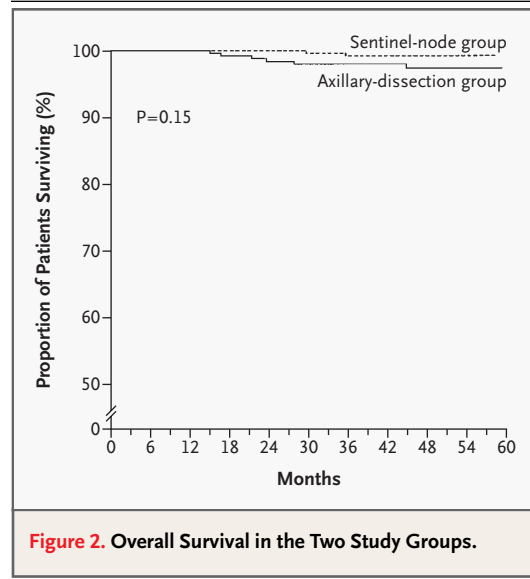
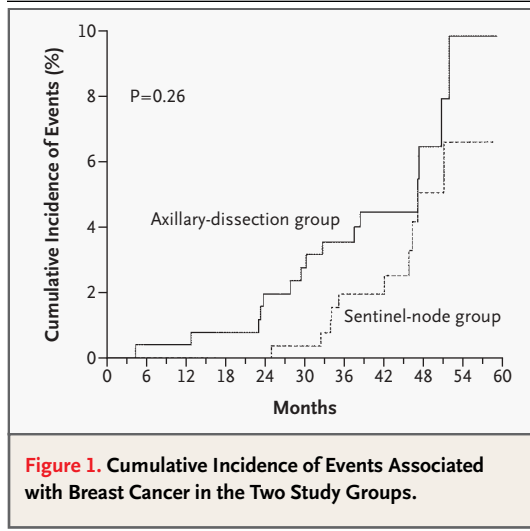
Event	Axillary-Dissection Group (N=257)	Sentinel-Node Group (N=259)
	<i>no. of events</i>	
Events other than death		
Axillary metastasis	0	0
Supraclavicular metastasis	2	0
Recurrence in ipsilateral breast	1	1
Cancer in contralateral breast	2	3
Distant metastasis	10	6
Other primary tumor	6	3
Total	21	13
Death due to breast cancer	2	1
Death from other causes	4	1

third, and skip metastases are infrequent.^{7,12,13} These findings encouraged investigations in breast cancer of sentinel-node biopsy, a procedure that is effective in melanoma.¹⁴ Initial results^{1,2,9,15} and many subsequent studies indicated that sentinel-node biopsy is a reliable axillary staging technique, although a limited number of false negative results has been a feature of all the reports published to date.

In the current study, randomization began in March 1998. As a single-center study, it had the advantages that the procedures used for sentinel-node identification, the surgical techniques, and the standards of pathological examination were uniform. Recruitment was completed quickly (in December 1999), after 532 patients had been randomly assigned to one of the two study groups. It is noteworthy that only 25 of the 649 patients initially considered for enrollment (3.9 percent) chose not to participate in the randomization, some requesting complete axillary dissection and others requesting sentinel-node biopsy procedure.¹⁶

We used a radioactive tracer (technetium-99m) and not blue dye to detect the sentinel node. Because our rate of sentinel-node identification was close to 99 percent, blue dye was not required as an adjuvant localization tool.

An important result of this study is that sentinel-node biopsy is effective in identifying cases in which one or more axillary nodes are positive for metastasis. Of the 259 patients in the sentinel-node group,



92 (35.5 percent) had a positive sentinel node and underwent total axillary dissection — a proportion similar to that in the axillary-dissection group, in which 91 of 257 patients (35.4 percent) were found to have axillary metastases. However, only 83 of those 91 patients had had a positive sentinel node; hence, the accuracy of sentinel-node biopsy in the axillary-dissection group was 96.9 percent. The false negative rate (8.8 percent) is similar to that observed in our previous series.^{1,3,9,17}

Assuming that the proportion of patients in the sentinel-node group who had a negative sentinel node and undetected axillary involvement is similar to that in the axillary-dissection group, we can estimate that 8 (95 percent confidence interval, 3 to 15) of the 167 patients in the sentinel-node group who had a negative sentinel node may have had occult axillary involvement. As of the last follow-up (at the end of March 2003), no overt axillary metastases had appeared in these 167 patients after a median follow-up of 46 months and a total of 634 patient-years at risk.

The possibility that occult metastasis will never become clinically evident if the axilla is left intact has been raised many times.¹⁸ In a series of 221 patients with breast cancer in whom the primary tumor was small (<1.2 cm in diameter) and who underwent conservative breast surgery without axillary dissection, overt axillary metastases developed in only two women (unpublished data).

A serious drawback to the use of sentinel-node biopsy arises if there is frequent discordance be-

tween “routine” findings on frozen section and subsequent findings on permanent section.⁸ Such discordant results would mean that patients with negative findings on intraoperative examination of frozen sections of the sentinel node and positive findings on the final pathological examination will have to undergo axillary dissection some days after the breast operation, a process imposing considerable psychological trauma on the patients. For this reason, we used a new method of intraoperative frozen-section examination, involving complete sectioning of the entire lymph node and examination of a large number of sections (30 to 60).⁸ The intraoperative diagnosis is therefore definitive, and no tissue is left for permanent sectioning.

In 60 of the 175 patients with a positive sentinel node, only micrometastases (foci ≤ 2 mm in diameter) were found in the sentinel nodes, and in only 10 of these 60 patients (17 percent) was another axillary node found to be involved. This poses the question of whether to perform axillary dissection when the sentinel node is micrometastatic or whether attentive follow-up is sufficient.

The fact that a small percentage (4.6 percent) of patients with a negative sentinel node had occult metastases in other axillary nodes suggests that there is a risk of “understaging” in such patients. However, our intraoperative method for examining the sentinel node is more sensitive than routine analysis of permanent sections and may actually lead to “overstaging” and hence to possible overtreatment.

Postoperative side effects were much less frequent in the patients who underwent sentinel-node biopsy only than in those who underwent complete axillary dissection. Disease-free survival was slightly better in the sentinel-node group than in the axillary-dissection group. Because the number of patients was small, however, firm conclusions cannot be drawn. Nevertheless, this randomized trial pro-

vides evidence justifying the use of sentinel-node biopsy as part of the assessment of the stage of breast cancer. Use of this method can obviate the need for total axillary dissection in patients with a negative sentinel node, thereby reducing postoperative morbidity and hospitalization costs.

Supported by the Italian Association for Cancer Research (AIRC).

REFERENCES

1. Giuliano AE, Kirgan DM, Guenther JM, Morton DL. Lymphatic mapping and sentinel lymphadenectomy for breast cancer. *Ann Surg* 1994;220:391-401.
2. Krag D, Weaver D, Ashikaga T, et al. The sentinel node in breast cancer — a multicenter validation study. *N Engl J Med* 1998;339:941-6.
3. Veronesi U, Paganelli G, Galimberti V, et al. Sentinel-node biopsy to avoid axillary dissection in breast cancer with clinically negative lymph-nodes. *Lancet* 1997;349:1864-7.
4. Elston CW, Ellis IO. Pathological prognostic factors in breast cancer. I. The value of histological grade in breast cancer: experience from a large study with long-term follow-up. *Histopathology* 1991;19:403-10.
5. De Cicco C, Cremonesi M, Luini A, et al. Lymphoscintigraphy and radioguided biopsy of the sentinel axillary node in breast cancer. *J Nucl Med* 1998;39:2080-4.
6. Zurrada S, Costa A, Luini A, Galimberti V, Sacchini V, Intra M. The Veronesi quadrantectomy: an established procedure for the conservative treatment of early breast cancer. *Int J Surg Invest* 2001;2:423-31.
7. Berg JW. The significance of axillary node levels in the study of breast carcinoma. *Cancer* 1955;8:776-8.
8. Viale G, Bosari S, Mazzarol G, et al. Intraoperative examination of axillary sentinel lymph nodes in breast carcinoma patients. *Cancer* 1999;85:2433-8.
9. Veronesi U, Paganelli G, Viale G, et al. Sentinel lymph node biopsy and axillary dissection in breast cancer: results in a large series. *J Natl Cancer Inst* 1999;91:368-73.
10. Gould AL. Sample sizes for event rate equivalence trials using prior information. *Stat Med* 1993;12:2009-23.
11. S Plus 2000. S Plus professional release 3. Seattle: Mathsoft, 2000.
12. Veronesi U, Luini A, Galimberti V, Marchini S, Sacchini V, Rilke F. Extent of axillary involvement in 1446 cases of breast cancer. *Eur J Surg Oncol* 1990;16:127-33.
13. Zurrada S, Morabito A, Galimberti V, et al. Importance of the level of axillary involvement in relation to traditional variables in the prognosis of breast cancer. *Int J Oncol* 1999;15:475-80.
14. Morton DL, Wen DR, Wong JH, et al. Technical details of intraoperative lymphatic mapping for early stage melanoma. *Arch Surg* 1992;127:392-9.
15. Albertini JJ, Lyman GH, Cox C, et al. Lymphatic mapping and sentinel node biopsy in the patient with breast cancer. *JAMA* 1996;276:1818-22.
16. Veronesi U, Galimberti V, Zurrada S, et al. Sentinel lymph node biopsy as an indicator for axillary dissection in early breast cancer. *Eur J Cancer* 2001;37:454-8.
17. McMasters KM, Giuliano AE, Ross MI, et al. Sentinel-lymph-node biopsy for breast cancer — not yet the standard of care. *N Engl J Med* 1998;339:990-5.
18. Mansi JL, Gogas H, Bliss JM, Gazet JC, Berger U, Coombes RC. Outcome of primary-breast-cancer patients with micrometastases: a long-term follow-up study. *Lancet* 1999;354:197-202.

Copyright © 2003 Massachusetts Medical Society.

EARLY JOB ALERT SERVICE AVAILABLE AT THE NEW NEJM CAREER CENTER

Register to receive weekly e-mail messages with the latest job openings that match your specialty, as well as preferred geographic region, practice setting, call schedule, and more. Visit the new NEJM Career Center at www.nejmjobs.org for more information.