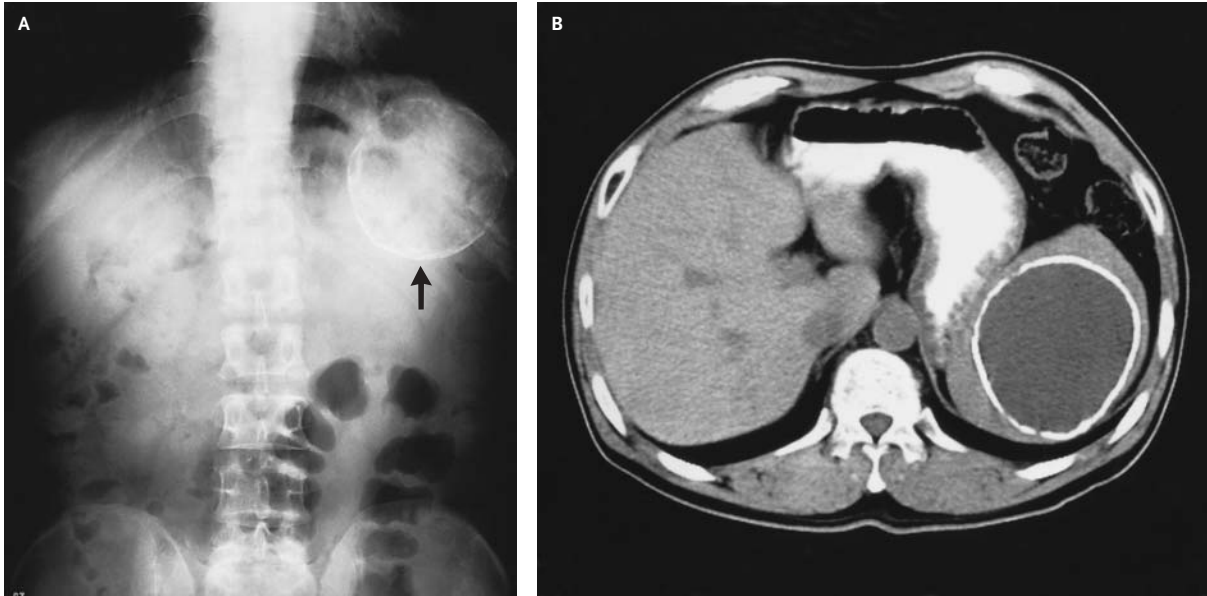


Calcified Splenic Cyst



Ton-Ho Young, M.D.
Hung-Shang Tang, M.D.

Cardinal Tien Hospital
Hsintien, Taipei Hsien, Taiwan

A 45-YEAR-OLD MAN PRESENTED WITH A TWO-MONTH HISTORY OF DIS-comfort in the left upper quadrant. Twenty years earlier, he had been involved in a motor vehicle accident. Physical examination confirmed mild tenderness over the posterior left upper quadrant. A plain abdominal film showed a large calcified lesion (Panel A, arrow) in the left upper abdomen. Computed tomography revealed a large, well-defined, cystic mass (8 by 9 by 11 cm) with mural calcification in the spleen (Panel B). Other causes of cystic splenic masses, such as parasitic cysts, various vascular tumors, fluid collections related to pancreatitis, benign tumors of the spleen, and cystic metastases, were ruled out.

Copyright © 2003 Massachusetts Medical Society.