

BRIEF REPORT

Myostatin Mutation Associated with Gross Muscle Hypertrophy in a Child

Markus Schuelke, M.D., Kathryn R. Wagner, M.D., Ph.D., Leslie E. Stolz, Ph.D., Christoph Hübner, M.D., Thomas Riebel, M.D., Wolfgang Kömen, M.D., Thomas Braun, M.D., Ph.D., James F. Tobin, Ph.D., and Se-Jin Lee, M.D., Ph.D.

From the Departments of Neuropediatrics (M.S., C.H.), Pediatric Radiology (T.R.), and Neonatology (W.K.), Charité, University Medical Center Berlin, Berlin; the Departments of Neurology (K.R.W.) and Molecular Biology and Genetics (S.-J.L.), Johns Hopkins University School of Medicine, Baltimore; the Department of Cardiovascular and Metabolic Diseases, Wyeth Research, Cambridge, Mass. (L.E.S., J.F.T.); and the Institute of Physiological Chemistry, Martin Luther University, Halle-Wittenberg, Germany (T.B.). Address reprint requests to Dr. Schuelke at the Department of Neuropediatrics, Charité, University Medical Center Berlin, Augustenburger Platz 1, D-13353 Berlin, Germany, or at markus.schuelke@charite.de.

N Engl J Med 2004;350:2682-8.
Copyright © 2004 Massachusetts Medical Society.

MUSCLE WASTING AND WEAKNESS ARE AMONG THE MOST COMMON INHERITED and acquired disorders and include the muscular dystrophies, cachexia, and age-related wasting. Since there is no generally accepted treatment to improve muscle bulk and strength, these conditions pose a substantial burden to patients as well as to public health. Consequently, there has been considerable interest in a recently described inhibitor of muscle growth, myostatin, or growth/differentiation factor 8 (GDF-8), which belongs to the transforming growth factor β superfamily of secreted proteins that control the growth and differentiation of tissues throughout the body. The myostatin gene is expressed almost exclusively in cells of skeletal-muscle lineage throughout embryonic development as well as in adult animals and functions as a negative regulator of muscle growth.^{1,2} Targeted disruption of the myostatin gene in mice doubles skeletal-muscle mass.¹ Conversely, systemic overexpression of the myostatin gene leads to a wasting syndrome characterized by extensive muscle loss.³ In adult animals, myostatin appears to inhibit the activation of satellite cells, which are stem cells resident in skeletal muscle.^{4,5}

The potential relevance of myostatin to the treatment of disease in humans has been suggested by studies involving *mdx* mice, which carry a mutation in the dystrophin gene and therefore serve as a genetic model of Duchenne's and Becker's muscular dystrophy.⁶ For example, *mdx* mice that lacked myostatin were found not only to be stronger and more muscular than their *mdx* counterparts with normal myostatin, but also to have reduced fibrosis and fatty remodeling, suggesting improved regeneration of muscle.⁷ Furthermore, injection of neutralizing monoclonal antibodies directed against myostatin into either wild-type or *mdx* mice increases muscle mass and specific force, suggesting that myostatin plays an important role in regulating muscle growth in adult animals.^{8,9}

The function of myostatin appears to be conserved across species, since mutations in the myostatin gene have been shown to be responsible for the "double-muscling" phenotype in cattle.¹⁰⁻¹³ The phenotypes of mice and cattle lacking myostatin and the high degree of sequence conservation of the predicted myostatin protein in many mammalian species have raised the possibility that myostatin may help regulate muscle growth in humans. We report the identification of a myostatin mutation in a child with muscle hypertrophy, thereby providing strong evidence that myostatin does play an important role in regulating muscle mass in humans.

CASE REPORT

A healthy woman who was a former professional athlete gave birth to a son after a normal pregnancy. The identity of the child's father was not revealed. The child's birth weight was in the 75th percentile. Stimulus-induced myoclonus developed several

hours after birth, and the infant was admitted to the neonatal ward for assessment. He appeared extraordinarily muscular, with protruding muscles in his thighs (Fig. 1A) and upper arms. With the exception of increased tendon reflexes, the physical examination was normal. Hypoglycemia and increased levels of testosterone and insulin-like growth factor I were excluded. Muscular hypertrophy was verified by ultrasonography when the infant was six days of age (Fig. 1B and 1C). Doppler echocardiography and electrocardiography performed soon after birth and every six months thereafter were consistently normal. At 4.3 years of age (body-surface area, 0.78 m²), the child had a pulse rate of 95 beats per minute, a left ventricular ejection fraction of 70 percent, fractional shortening at the midwall of 56 percent, and a cardiac output of 2.81 liters per minute, with a left ventricular measurement of 3.42 cm during diastole (50th percentile) and 1.99 cm (25th percentile) during systole and respective septal measurements of 0.59 cm (75th percentile) and 0.81 cm (75th percentile).

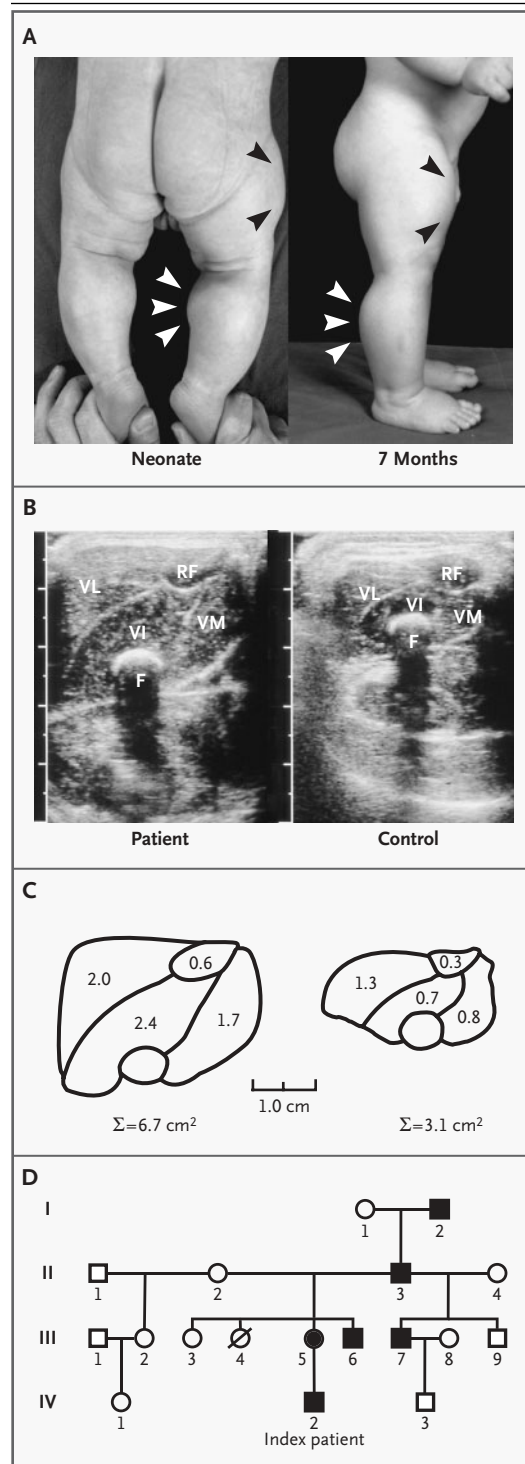
The stimulus-induced myoclonus gradually subsided after two months. The child's motor and mental development has been normal. Now, at 4.5 years of age, he continues to have increased muscle bulk and strength, and he is able to hold two 3-kg dumbbells in horizontal suspension with his arms extended.

Several family members (Fig. 1D) have been reported to be unusually strong. Family member II-3 was a construction worker who was able to unload curbstones by hand. The 24-year-old mother of the

child (III-5) appeared muscular, though not to the extent observed in her son; she did not report any health problems. No family members aside from the mother were available to provide samples for genetic analysis.

Figure 1. Photographs of the Child at the Ages of Six Days and Seven Months (Panel A), Ultrasonograms (Panel B) and Morphometric Analysis (Panel C) of the Muscles of the Patient and a Control Infant, and the Patient's Pedigree (Panel D).

The arrowheads in Panel A indicate the protruding muscles of the patient's thigh and calf. In Panel B, an ultrasonographic transverse section (linear transducer, 10 MHz) through the middle portion of the thigh reveals differences between the patient and a control infant of the same age, sex, and weight. VL denotes vastus lateralis, VI vastus intermedius, VM vastus medialis, RF rectus femoris, and F femur. In Panel C, retracings of the muscle outlines and results of the morphometric analysis of the muscle cross-sectional planes of the two infants also reveal marked differences. Panel D shows the patient's pedigree. Solid symbols denote family members who are exceptionally strong, according to information in their clinical history. Square symbols denote male family members, and circles female family members.



METHODS

The study was approved by the institutional ethics review committee of the Charité, University Medical Center Berlin. Written informed consent was obtained from the child's mother as well as from the parents of all control subjects. Investigations were conducted in accordance with the Declaration of Helsinki (2000).

All three exons of myostatin and flanking intron sequences (GenBank NT_022197) were amplified from genomic DNA by means of the polymerase chain reaction (PCR) with the following oligonucleotides: exon 1 forward primer, 5'ATTCACTGGTGTGGCAAGTTG3'; exon 1 reverse primer, 5'CAGCAGAAGTGTGATATACACTAATAGG3'; exon 2 forward primer, 5'GTTAATGGGAAATAATTCAGCAAC3'; exon 2 reverse primer, 5'AGGTTATTATAATGTTATTTTCAGTTATCAC3'; exon 3 forward primer, 5'CAGGCCTATTGATATTACTGATTGTTC3'; and exon 3 reverse primer, 5'GACTGTAGCATACTCTAGGCC-TATAGCC3'. The samples were then subjected to bidirectional automatic sequencing (BigDye Terminator, Applied Biosystems), and the presence of the g.IVS1+5 g→a mutation was verified by a primer-induced restriction assay with the forward primer 5'CAAAGCTCCTCCACTCCGG3' and the reverse-mismatch primer (mismatch underlined) 5'CAGCAGAAGTGTTCATATACACTAATAGGTCTA3'. Total RNA was extracted from Epstein-Barr virus (EBV)-immortalized lymphoblastoid cells with TRIzol and reverse-transcribed with Superscript III (Invitrogen). Several primer combinations across the boundary between exon 1 and exon 2 were used: 5'CATGCAAAAAC-TGCAACTCTGTGT3' (P1F), 5'AAATGAGAACAGT-GAGCAA3' (P2F), 5'CAAAGCTCCTCCACTCCGG3' (P3R), and 5'ATCCATAGTTGGGCCTTACTACT-TTA3' (P4R). As the reverse-transcribed control, *HPRT* was coamplified in a multiplex PCR (primers, 5'CCTGCTGGATTACATTAAGCACTG3' and 5'CCTGAAGTATTTCATTATAGTCAAGG3').

An 8.4-kb DNA fragment spanning the entire human myostatin gene from the 5' end of the messenger RNA (mRNA) to a site 1.4 kb downstream of the polyadenylation signal was cloned into pCMV5 and MDAF2 vectors, and the mutation was introduced by site-directed mutagenesis. COS-7, Chinese-hamster-ovary, and A204 rhabdomyosarcoma cells were transiently transfected with wild-type or mutant plasmids. Cells were cotransfected with plasmid containing a secreted myc-tagged protein

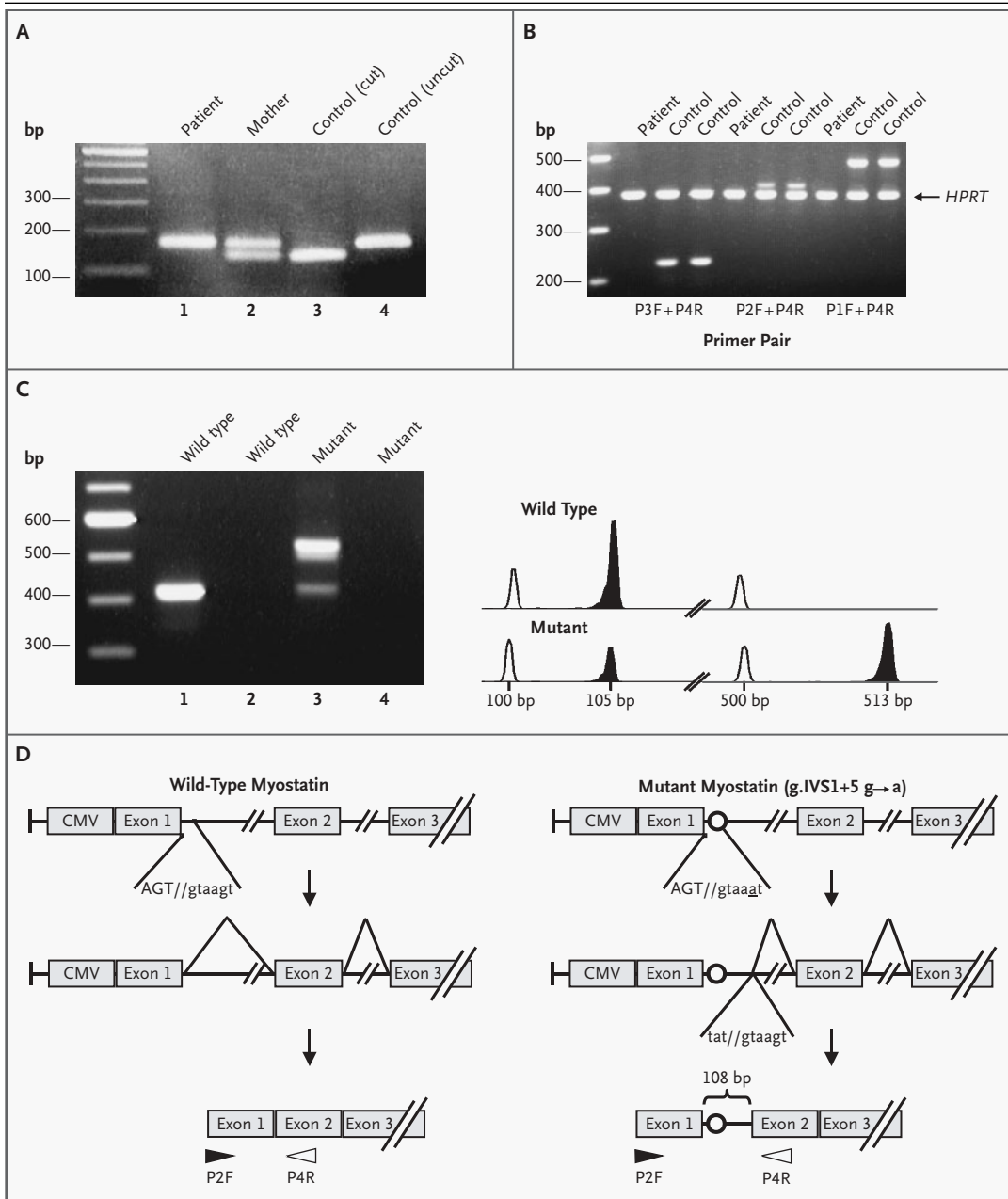
Figure 2 (facing page). Mutation Analysis.

Panel A shows the results of primer-induced restriction analysis for the presence of the g.IVS1+5 g→a mutation in the patient, his mother, and a control subject. *AccI* cleaves a fragment of 166 bp into two segments — one of 135 bp and one of 31 bp — only if the wild-type sequence is present. Lanes 3 and 4 show cleaved (cut) and uncleaved (uncut) segments from a control subject. Panel B shows the results of multiplex reverse-transcriptase PCR of messenger RNA (mRNA) from the patient and two control subjects in Epstein-Barr virus-immortalized lymphoblastoid cells. A housekeeping gene (*HPRT*) was amplified along with various fragments of the myostatin gene and yielded a product of equal intensity in all reactions. No myostatin product could be amplified from RNA from the patient, indicating nonsense-mediated messenger decay. Panel C shows the products of reverse-transcriptase PCR generated with the use of P2F and P4R primers from wild-type myostatin constructs (lanes 1 and 2) and mutant myostatin constructs (lanes 3 and 4) transfected into COS-7 cells, with (lanes 1 and 3) and without (lanes 2 and 4) reverse transcriptase. In the presence of the mutation, 68 percent of the precursor mRNA is spliced incorrectly. Panel D shows that mutant myostatin has a g.IVS1+5 g→a transition at the splice donor site in intron 1, causing splicing to occur 108 bp downstream at a cryptic splice site, which produces a larger transcript in the mutant and results in a premature termination codon. CMV denotes promoter sequences derived from cytomegalovirus.

as a transfection-efficiency control and with an expression construct for the furin protease paired dibasic amino acid-cleaving enzyme to improve processing of the precursor myostatin protein.¹⁴ Conditioned medium was concentrated, separated by reducing sodium dodecyl sulfate-polyacrylamide-gel electrophoresis, and transferred onto a membrane. Myostatin was detected with the use of polyclonal antibodies against a C-terminal domain.¹ The control myc-tagged protein was detected with the use of a monoclonal antibody against myc.

RNA from transiently transfected cells was treated with DNase I (Invitrogen) and amplified by means of reverse-transcriptase PCR with P2F and P4R primers. Wild-type and mutant bands were excised from the agarose gel, purified, and sequenced. The relative abundance of the wild-type and mutant bands was determined by measuring the relative fluorescence after amplification with a FAM-labeled P4R primer on an ABI 3100 gene scanner (Applied Biosystems).

For immunoprecipitation and Western blotting,



JA-16-coupled beads (directed against a C-terminal peptide of myostatin) were prepared and myostatin was immunoprecipitated by incubating 60 μ l of packed beads with 0.5 ml of serum.¹⁵ After washing, bound myostatin was eluted and further separated by sodium dodecyl sulfate–polyacrylamide gel electrophoresis, blotted on a membrane, and probed with the polyclonal rabbit antibody L8825 against myostatin propeptide.

RESULTS

IMAGING

Ultrasonography showed that the cross-sectional plane of the patient's quadriceps muscle was 7.2 SD above the mean (\pm SD) value for 10 age- and sex-matched controls (6.72 cm² vs. 3.13 \pm 0.49 cm²). Moreover, the thickness of his subcutaneous fat pad was 2.88 SD below the mean value for controls

(0.18 cm vs. 0.36 ± 0.06 cm). There was no significant difference in the diameter of the femoral bone between the patient and the controls (0.57 cm vs. 0.50 ± 0.13 cm). The echogenicity of the muscle was normal, with no indication of fibrosis or deposition of fat tissue (Fig. 1B and 1C).

MOLECULAR BIOLOGY

The phenotype of our patient was reminiscent of the increased musculing and decreased adiposity reported in mice^{1,16-18} and cattle¹⁰⁻¹³ with loss-of-function mutations in the myostatin gene. Therefore, we sequenced all exons and flanking intron regions of the gene in the patient and his mother. Although no mutations were detected in the coding region, a g→a transition at nucleotide g.IVS1+5 was present in both alleles of the patient and one allele of his mother. The mutation was confirmed by restriction analysis (Fig. 2A) and was absent in 200 alleles from control subjects with a similar ethnic background, thus excluding a common polymorphism.

The presence of this mutation raised the possibility of missplicing of the myostatin precursor mRNA in the patient, since the +5 position at the splice donor site is a common location for splice-site mutations in humans.¹⁹ When we applied the scoring method of Shapiro and Senapathy²⁰ to analyze the degree of matching between the sequence of the splice donor site of intron 1 with the corresponding consensus sequence (AG//gtrag), the score dropped from 79.4 (wild type, GT//gtaagt) to 65.0 (mutant, GT//gtaaat), indicating that missplicing is likely.

In order to investigate the effect of this mutation on the maturation of the myostatin mRNA, we generated genomic wild-type and mutant constructs for the expression of human myostatin mRNA in cultured muscle and nonmuscle cells and performed reverse-transcriptase PCR on RNA isolated from the transfected cells. PCR across the boundary between exon 1 and exon 2 yielded a single band of 405 bp for the wild-type construct. For the mutant construct, however, we detected two PCR products, a faint band equivalent in size to that obtained after transfection of the wild-type construct and a major novel product of higher molecular weight (Fig. 2C). This product contained an insertion of the first 108 bp of intron 1 (including the g.IVS1+5 g→a mutation) and resulted from the activation of a cryptic splice site within intron 1 (at//gtaagt) (Fig. 2D). Quantification of the relative intensities of the major and minor bands ob-

tained from these PCR reactions showed that 68.8 ± 0.032 percent (three samples) of the myostatin mRNA from the mutant construct was misspliced (Fig. 2C). The misspliced mRNA is predicted to give rise to a severely truncated protein, since the 108-bp insertion adds a single lysine residue followed by a premature termination codon.

Consistent with the results of RNA analysis, myostatin protein was detected only in the conditioned medium from COS-7 cells transfected with the wild-type construct, whereas it was virtually absent in cells transfected with the mutant construct (Fig. 3A). Similar results were obtained with other cell lines, including Chinese-hamster-ovary cells and A204 rhabdomyosarcoma cells (data not shown).

We also sought to confirm the effect of this splice-site mutation in samples from the patient. Because we lacked a muscle-biopsy specimen, we examined myostatin mRNA from the patient's EBV-immortalized lymphoblastoid cells. These cells tend to express low levels of illegitimate transcripts, not normally present in blood cells. Illegitimate transcription proceeds through the normal promoters and may be used for the detection of mutations on the mRNA level if specific tissue is unavailable.²¹ We did not find any myostatin products in cells from the patient (Fig. 2B). We believe that general degradation of mRNA is an unlikely explanation for this negative result, since we were able to detect similar levels of transcripts of a housekeeping gene (*HPRT*) in the patient and controls. Mutant transcripts may be specifically degraded through nonsense-mediated messenger decay, since the premature termination codon is located upstream of a spliceable exon.²²

Finally, we attempted to measure myostatin levels in the patient's serum samples. Myostatin is readily detected by Western blotting in serum samples from mice.³ Similar approaches have proved much more difficult in human serum samples, presumably because humans have lower circulating myostatin levels. Using an antibody against myostatin, we first concentrated myostatin in serum samples by immunoprecipitation and then detected its presence with a second antibody against the propeptide region. We opted for the antibody directed against the propeptide (L8825), since it binds more tightly and picks up smaller amounts of protein than the antibody against mature myostatin. We identified a band at approximately 36 kD in rat serum, corresponding to myostatin propeptide. It was present to a lesser degree in the serum samples

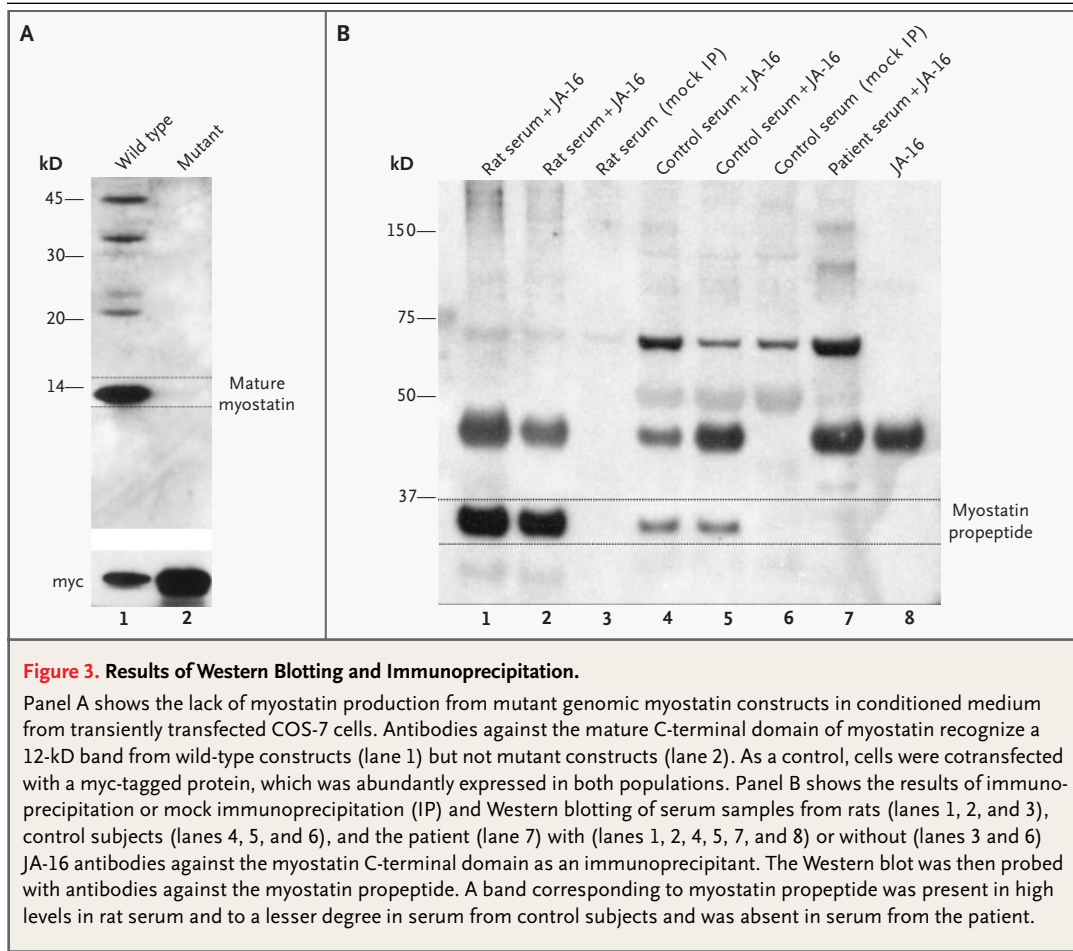


Figure 3. Results of Western Blotting and Immunoprecipitation.

Panel A shows the lack of myostatin production from mutant genomic myostatin constructs in conditioned medium from transiently transfected COS-7 cells. Antibodies against the mature C-terminal domain of myostatin recognize a 12-kD band from wild-type constructs (lane 1) but not mutant constructs (lane 2). As a control, cells were cotransfected with a myc-tagged protein, which was abundantly expressed in both populations. Panel B shows the results of immunoprecipitation or mock immunoprecipitation (IP) and Western blotting of serum samples from rats (lanes 1, 2, and 3), control subjects (lanes 4, 5, and 6), and the patient (lane 7) with (lanes 1, 2, 4, 5, 7, and 8) or without (lanes 3 and 6) JA-16 antibodies against the myostatin C-terminal domain as an immunoprecipitant. The Western blot was then probed with antibodies against the myostatin propeptide. A band corresponding to myostatin propeptide was present in high levels in rat serum and to a lesser degree in serum from control subjects and was absent in serum from the patient.

from age- and sex-matched control subjects but was absent in the patient's serum (Fig. 3B). Since the molar ratio between propeptide and mature myostatin in serum is approximately 1:1,¹⁵ we conclude that the absence of the propeptide indicates the absence of mature myostatin in the patient.

DISCUSSION

These results strongly indicate that our patient has a loss-of-function mutation in the myostatin gene, thus suggesting that the inactivation of myostatin has similar effects in humans, mice, and cattle. So far, we have not observed any health problems in the patient. Since myostatin is also expressed in the heart,²³ we have closely monitored our patient's cardiac function but have not yet detected any signs of cardiomyopathy or a conduction disturbance. However, at 4.5 years of age, our patient is still too young for such abnormalities to be ruled out de-

nitively. Our results suggest the possibility that muscle bulk and strength could be therapeutically increased by the inactivation of myostatin in patients with muscle-wasting conditions.

Supported by funds from the parents' self-help group Helft dem Muskelkranken Kind, Hamburg e.V. (to Drs. Schuelke and Hübner), and by grants from the National Institutes of Health (R01HD35887 and R01CA88866, to Dr. Lee, and K08NS02212, to Dr. Wagner) and the Muscular Dystrophy Association (to Dr. Wagner). Dr. Hübner is a member of the Network on Muscular Dystrophies (01GM0302), which is funded by the German Ministry of Education and Research, Bonn, Germany.

Drs. Stolz and Tobin are employees of Wyeth Pharmaceuticals. Dr. Tobin reports having equity in Wyeth Pharmaceuticals, and Dr. Lee reports having served as a paid consultant to and having equity in MetaMorphix and is named on multiple patents related to myostatin, which were licensed by Johns Hopkins University to MetaMorphix and sublicensed to Wyeth, and is entitled to a share of sales royalties.

We are indebted to Xiaoli Chang, Antje Gerlach, Christine Gerstenfeld, Heidemarie Neitzel, Thomas Voit, and Angelika Zwirner for their help; to Orest Hurko, Neil Wolfman, and Seamus McDuff for useful discussions; and to Jeremy Nathans for providing the plasmid containing a myc-tagged protein and the monoclonal antibody against the myc epitope.

REFERENCES

1. McPherron AC, Lawler AM, Lee SJ. Regulation of skeletal muscle mass in mice by a new TGF- β superfamily member. *Nature* 1997;387:83-90.
2. Amthor H, Huang R, McKinnell I, et al. The regulation and action of myostatin as a negative regulator of muscle development during avian embryogenesis. *Dev Biol* 2002; 251:241-57.
3. Zimmers TA, Davies MV, Koniaris LG, et al. Induction of cachexia in mice by systemically administered myostatin. *Science* 2002; 296:1486-8.
4. McCroskery S, Thomas M, Maxwell L, Sharma M, Kambadur R. Myostatin negatively regulates satellite cell activation and self-renewal. *J Cell Biol* 2003;162:1135-47.
5. Mauro A. Satellite cell of skeletal muscle fibers. *J Biophys Biochem Cytol* 1961;9:493-5.
6. Sicinski P, Geng Y, Ryder-Cook AS, Barnard EA, Darlison MG, Barnard PJ. The molecular basis of muscular dystrophy in the mdx mouse: a point mutation. *Science* 1989;244:1578-80.
7. Wagner KR, McPherron AC, Winik N, Lee SJ. Loss of myostatin attenuates severity of muscular dystrophy in mdx mice. *Ann Neurol* 2002;52:832-6.
8. Whittemore LA, Song K, Li X, et al. Inhibition of myostatin in adult mice increases skeletal muscle mass and strength. *Biochem Biophys Res Commun* 2003;300:965-71.
9. Bogdanovich S, Krag TOB, Barton ER, et al. Functional improvement of dystrophic muscle by myostatin blockade. *Nature* 2002; 420:418-21.
10. Grobet L, Martin LJR, Poncelet D, et al. A deletion in the bovine myostatin gene causes the double-muscling phenotype in cattle. *Nat Genet* 1997;17:71-4.
11. Grobet L, Poncelet D, Royo LJ, et al. Molecular definition of an allelic series of mutations disrupting the myostatin function and causing double-muscling in cattle. *Mamm Genome* 1998;9:210-3.
12. Kambadur R, Sharma M, Smith TP, Bass JJ. Mutations in myostatin (GDF8) in double-muscling Belgian Blue and Piedmontese cattle. *Genome Res* 1997;7:910-6.
13. McPherron AC, Lee SJ. Double muscling in cattle due to mutations in the myostatin gene. *Proc Natl Acad Sci U S A* 1997; 94:12457-61.
14. Lee SJ, McPherron AC. Regulation of myostatin activity and muscle growth. *Proc Natl Acad Sci U S A* 2001;98:9306-11.
15. Hill JJ, Davies MV, Pearson AA, et al. The myostatin propeptide and the follistatin-related gene are inhibitory binding proteins of myostatin in normal serum. *J Biol Chem* 2002;277:40735-41.
16. Szabó G, Dallmann G, Müller G, Patthy L, Soller M, Varga L. A deletion in the myostatin gene causes the compact (Cmpt) hypermuscular mutation in mice. *Mamm Genome* 1998;9:671-2.
17. Lin J, Arnold HB, Della-Fera MA, Azain MJ, Hartzell DL, Baile CA. Myostatin knock-out in mice increases myogenesis and decreases adipogenesis. *Biochem Biophys Res Commun* 2002;291:701-6.
18. McPherron AC, Lee SJ. Suppression of body fat accumulation in myostatin-deficient mice. *J Clin Invest* 2002;109:595-601.
19. Krawczak M, Reiss J, Cooper DN. The mutational spectrum of single base-pair substitutions in mRNA splice junctions of human genes: causes and consequences. *Hum Genet* 1992;90:41-54.
20. Shapiro MB, Senapathy P. RNA splice junctions of different classes of eukaryotes: sequence statistics and functional implications in gene expression. *Nucleic Acids Res* 1987;15:7155-74.
21. Chelly J, Gilgenkrantz H, Hugnot JP, et al. Illegitimate transcription: application to the analysis of truncated transcripts of the dystrophin gene in nonmuscle cultured cells from Duchenne and Becker patients. *J Clin Invest* 1991;88:1161-6.
22. Hentze MW, Kulozik AE. A perfect message: RNA surveillance and nonsense-mediated decay. *Cell* 1999;96:307-10.
23. Sharma M, Kambadur R, Matthews KG, et al. Myostatin, a transforming growth factor- β superfamily member, is expressed in heart muscle and is upregulated in cardiomyocytes after infarct. *J Cell Physiol* 1999; 180:1-9.

Copyright © 2004 Massachusetts Medical Society.

CLINICAL PROBLEM-SOLVING SERIES

The *Journal* welcomes submissions of manuscripts for the Clinical Problem-Solving series. This regular feature considers the step-by-step process of clinical decision making. For more information, please see <http://authors.nejm.org>.