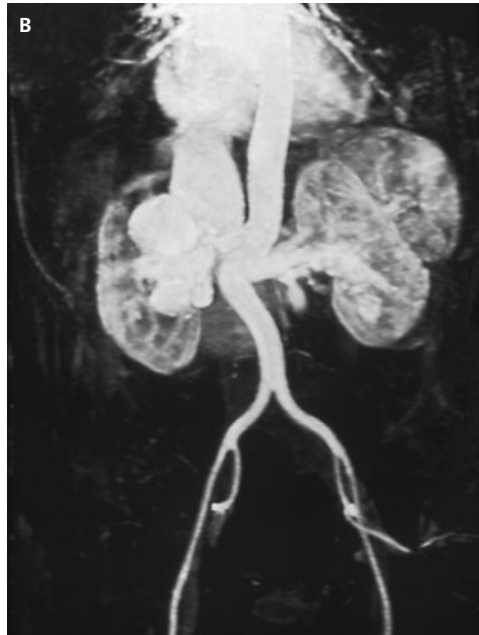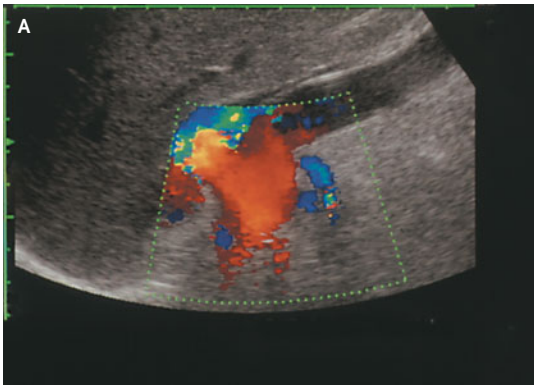


IMAGES IN CLINICAL MEDICINE

Bilateral Renal Arteriovenous Malformation



A 43-YEAR-OLD WOMAN PRESENTED WITH DYSPNEA ON MODERATE EXERCISE and bilateral flank bruits. The patient had no history of trauma. Echocardiography revealed left ventricular hypertrophy and an enlarged inferior vena cava. Color Doppler examination (Panel A) showed increased blood flow in one of two left renal arteries and in a giant right renal artery. A coronal scan of the right flank (video clip) showed a longitudinal view of the aorta, which was visibly pulsating behind the vena cava. A giant right renal artery originated from the aorta and was directed upward (to the left, in the video image). When the course of the renal artery was followed laterally to the right renal hilum, a lesion that resembled a multiloculated parahilar cyst could be seen. Color Doppler analysis revealed high blood flow in the lesion, suggesting the presence of a large, cavernous arteriovenous malformation. Nuclear magnetic resonance angiography (Panel B) showed three renal arteries on the left side. Of those arteries, the most caudal had an arteriovenous fistula, which was successfully treated by means of selective endovascular coil embolization. Endovascular embolization of the arteriovenous malformation involving the right main renal artery and vein was attempted. Subsequently, a right nephrectomy was performed. The patient was discharged with normal renal function.

Copyright © 2004 Massachusetts Medical Society.

Enrico Minetti, M.D.
Alberto Montoli, M.D.

Ospedale Niguarda Ca'Granda
20162 Milan, Italy