

CORRESPONDENCE

- 2232 HIV-1 and HCV Infections
in Antibody-Negative Blood
Donors
- 2235 MRI in Breast Cancer
- 2236 C/EBP α in Asthma
- 2237 Hypocalciuric Hypercalcemia
and Autoantibodies against
the Calcium-Sensing Receptor
- 2239 Generalized Anxiety Disorder
- 2239 More on Blue Cohosh
and Perinatal Stroke
- 2241 Soluble fms-like Tyrosine
Kinase 1

BOOK REVIEWS

- 2243 One of Us: Conjoined Twins
and the Future of Normal
- 2244 Mutants: On Genetic Variety
and the Human Body
- 2244 The World of Deaf Infants:
A Longitudinal Study
- 2245 Encyclopedia of Medical Anthro-
pology: Health and Illness
in the World's Cultures

CONTINUING MEDICAL EDUCATION

- 2249 Acute Pericarditis
- 2250 Advances in H₁-Antihistamines
- 2251 Ultrasound-Enhanced Systemic
Thrombolysis for Acute
Ischemic Stroke

**Next Week
in the Journal**

NOVEMBER 25, 2004

The Business of Cord Blood

Robert Steinbrook

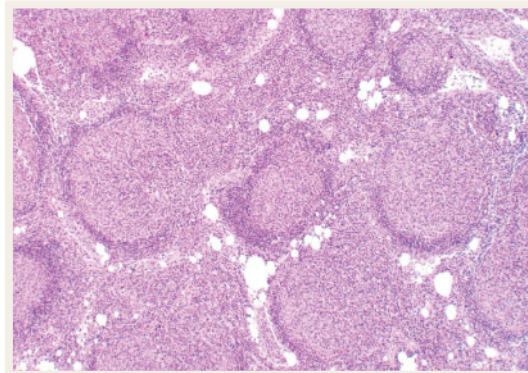


This Week in the Journal

NOVEMBER 18, 2004

ORIGINAL ARTICLE

Tumor-Infiltrating Immune Cells and Survival in Follicular Lymphoma



Patients with follicular lymphoma may survive for periods ranging from less than a year to several decades. In this study, DNA-microarray analysis of gene expression in specimens of follicular lymphoma showed that two genetic signatures predicted the length of survival with a high degree of

accuracy. Surprisingly, one signature consisted of genes that are typically expressed in normal T cells, and the other consisted of genes expressed in monocytes and dendritic cells.

This study conveys two important ideas about follicular lymphoma: accurate prognostic stratification is possible with the use of molecular technology, and tumor-infiltrating immune cells have an important prognostic role.

SEE P. 2159; PERSPECTIVE, P. 2152

ORIGINAL ARTICLE

Ultrasound-Enhanced Thrombolysis for Acute Ischemic Stroke

Thrombolytic therapy is not consistently effective in patients with acute ischemic stroke. In this phase 2 study, transcranial Doppler ultrasonography that was aimed at residual obstruction in the middle cerebral artery during thrombolytic therapy with tissue plasminogen activator resulted in improved recanalization of the artery. Ultrasonic enhancement of thrombolysis may be due to improved transport of the drug to the thrombus. A larger trial will be needed to investigate the effects of this approach on neurologic recovery.

SEE P. 2170; PERSPECTIVE, P. 2154; CME, P. 2251

ORIGINAL ARTICLE

Prematurity and Later Insulin Resistance

Term infants who are small for gestational age are prone to the development of insulin resistance later in life. This study measured insulin sensitivity at the age of 4 to 10 years in children who had been born prematurely. An isolated reduction in insulin sensitivity was observed in both children who had been born prematurely but were appropriate for gestational age at birth and those who had been born prematurely but were small for gestational age, suggesting that premature infants may be at high risk for the metabolic syndrome and type 2 diabetes mellitus.

SEE P. 2179; EDITORIAL, P. 2229

SPECIAL ARTICLE

Medicaid Prior Authorization and the Use of Selective Cyclooxygenase-2 Inhibitors

To control costs, some state Medicaid programs have implemented policies requiring prior approval before a selective cyclooxygenase-2 inhibitor (coxib) can be prescribed. This study found that the implementation of such programs resulted in a 15 percent decrease in the use of coxibs as a proportion of all prescriptions for nonsteroidal antiinflammatory agents and substantial reductions in drug spending.

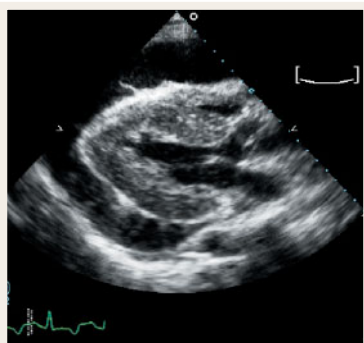
SEE P. 2187; PERSPECTIVE, P. 2156

CLINICAL PRACTICE

Acute Pericarditis

A 35-year-old woman who is otherwise healthy has had constant retrosternal chest pain for two days. The pain worsens when she lies down and improves when she sits up and leans forward. On physical examination, the patient is afebrile and has a friction rub. The 12-lead electrocardiogram shows widespread ST-segment elevation and concomitant PR-segment depression. How should this patient be evaluated and treated?

SEE P. 2195; CME, P. 2249



DRUG THERAPY

H₁-Antihistamines

Histamine has an important role as a chemical messenger in physiologic responses, neurotransmission, allergic inflammation, and immunomodulation by way of the H₁-receptor. Most H₁-antihistamines, which are useful in treating these effects, possess similar efficacy in allergic rhinoconjunctivitis and chronic urticaria. However, there are clinically relevant differences among them in their pharmacology and safety profiles. This article suggests a rational approach to selecting H₁-antihistamines.

SEE P. 2203; CME, P. 2250

CASE RECORDS OF THE

MASSACHUSETTS GENERAL HOSPITAL

A Man with End-Stage Renal Disease and Thickening of the Skin

Thickening of the skin of the arms and legs, with flexion contractures of the knees, elbows, fingers, and toes, developed in a 68-year-old man with long-standing diabetes mellitus complicated by retinopathy, neuropathy, and renal failure. He was unable to walk and had nonhealing ulcers on both heels. Examination disclosed brown-pigmented, indurated plaques on the arms and legs. A diagnostic procedure was performed.

SEE P. 2219

