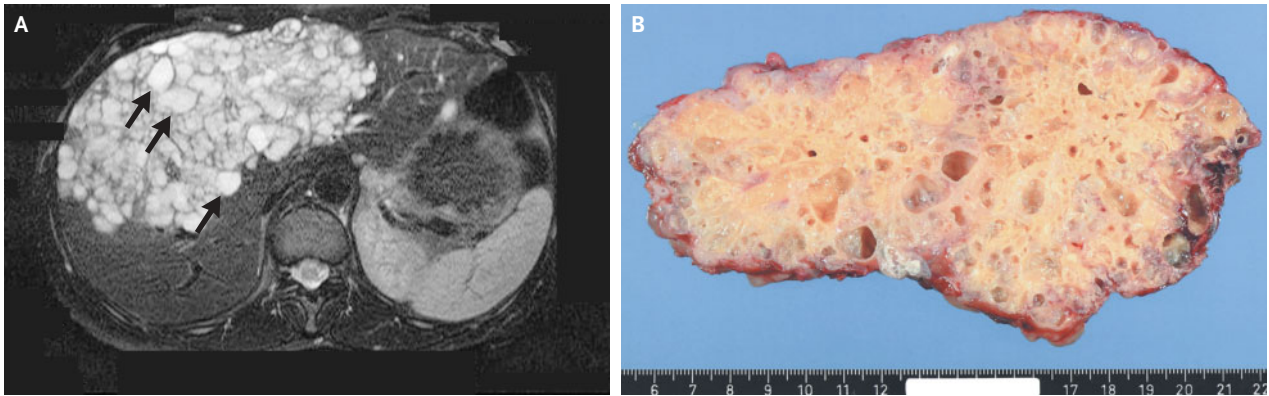


## A Cystic Mass in the Liver



**A** 44-YEAR-OLD WOMAN PRESENTED WITH A 10-MONTH HISTORY OF INTERMITTENT discomfort in the right upper abdomen. On physical examination, a mass filling the epigastrium and the right subcostal region was noted. Ultrasonography and computed tomography of the abdomen showed multiple cysts in both lobes of the liver. An image of the liver obtained by magnetic resonance imaging showed a cystic mass involving the medial segment of the left lobe and the anterior segment of the right lobe (Panel A, arrows). Serologic testing for hydatid disease by means of an enzyme-linked immunosorbent assay and a complement-fixation test were positive (titer, 1:8). A radical excision of the cyst was performed (Panel B), and microscopical examination of the specimen confirmed the diagnosis of alveolar hydatid disease. Albendazole therapy was begun postoperatively, and the patient had a complete recovery.

Alveolar echinococcosis is caused by infection with the cestode *Echinococcus multilocularis*. Transmission is limited to specific geographic regions in the Northern Hemisphere, such as western Alaska, central and northern Europe, and northern Asia, including Siberia, China, and Japan. When the lesions are completely resected, the prognosis is excellent.

Copyright © 2004 Massachusetts Medical Society.

Nermin Halkic, M.D.  
Michel Gillet, M.D.

University of Lausanne Medical School  
CH-1101 Lausanne, Switzerland