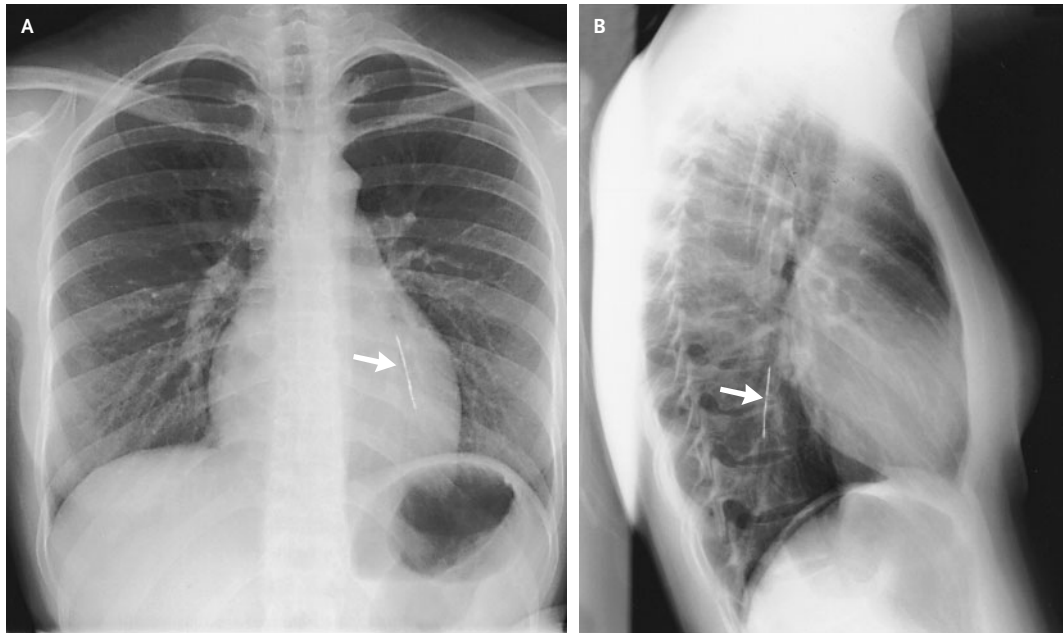


Inhaled Foreign Body



Syed Mohammad Tariq,
M.R.C.P.

Jojo George, M.R.C.P.

Sultan Qaboos University Hospital
Muscat, Oman

MANY ARAB WOMEN WEAR A HEAD SCARF, TERMED THE *LAHAAF* OR *hejaab*. It is usually secured around the head and neck with one or two pins. A 20-year-old Arab woman presented after having accidentally inhaled a pin as she adjusted her *lahaaf* while holding the pin in her mouth. Posteroanterior and lateral chest radiographs (Panels A and B, respectively) showed the pin in a bronchus of the left lower lobe (arrow in each panel). A fiberoptic bronchoscopy was performed. The pin was seen in the distal part of the left-lower-lobe bronchus, with the pinhead lodged in the posterior segment. The pin was removed endoscopically, without adverse consequences.

Copyright © 2004 Massachusetts Medical Society.