

**CORRESPONDENCE**

- 1039 Implantable Cardioverter-Defibrillator Therapy after Myocardial Infarction
- 1041 Isosorbide Dinitrate and Hydralazine in Blacks with Heart Failure
- 1044 Intradermal Vaccination against Influenza
- 1046 The U.S. Vaccine Supply
- 1047 Medical Mystery — The Answer
- 1048 Peripartum Dissection of the Right Coronary Artery
- 1049 Imatinib and Regression of Type 2 Diabetes

**BOOK REVIEWS**

- 1051 Vaccines: Preventing Disease and Protecting Health
- 1052 Moving Mountains: The Race to Treat Global AIDS
- 1054 The Black Death 1346–1353: The Complete History
- 1055 Plagues and Poxes: The Impact of Human History on Epidemic Disease

**CONTINUING MEDICAL EDUCATION**

- 1057 Neurocardiogenic Syncope
- 1058 Electronic Alerts to Prevent Venous Thromboembolism among Hospitalized Patients
- 1059 Anemia of Chronic Disease

---

## Next Week in the Journal

MARCH 17, 2005

### What Ails the FDA?

Susan Okie

---

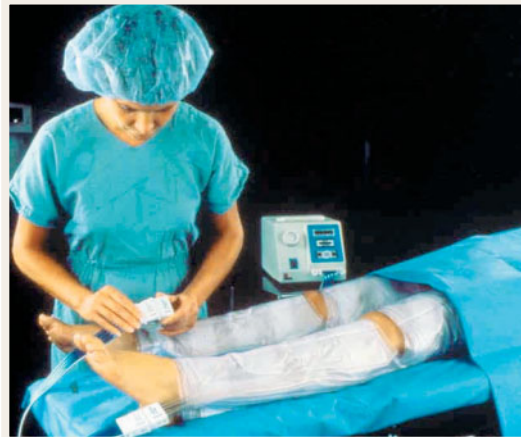

# This Week in the Journal

MARCH 10, 2005

**ORIGINAL ARTICLE**

### Electronic Alerts to Prevent Venous Thromboembolism



Hospitalized patients may be at risk for venous thromboembolism as a result of bed rest, cancer, or major surgery, yet not all such patients receive prophylaxis against deep-vein thrombosis. An electronic alert system, which prompted physicians to prescribe prophylaxis to patients at risk for deep-vein thrombosis, was deter-

mined not only to increase the use of prophylactic measures but also to reduce the risk of venous thromboembolism.

These findings should lead to wider implementation of electronic alert systems for the purpose of preventing venous thromboembolism in hospitalized patients.

SEE P. 969; EDITORIAL, P. 1034; CME, P. 1058

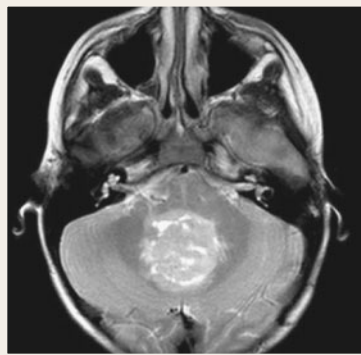
ORIGINAL ARTICLE

**Chemotherapy in Young Children with Medulloblastoma**

Medulloblastoma in young children has a poor prognosis. Furthermore, cognitive function in survivors is often impaired owing to treatment with cranial radiotherapy. This study obtained promising results in children undergoing intensive chemotherapy alone.

For years there has been little progress in the treatment of medulloblastoma, the commonest tumor of the central nervous system in children. This study provides a hopeful advance, especially for children without metastases.

SEE P. 978; EDITORIAL, P. 1036



ORIGINAL ARTICLE

**Radiotherapy plus Temozolomide for Glioblastoma**

Most patients with glioblastoma multiforme, the most common primary malignant brain tumor in adults, die within two years of the diagnosis, despite surgery and radiotherapy. This trial compared postoperative radiotherapy with postoperative radiotherapy plus temozolomide, an alkylating agent. The combined treatment was safe and reduced the risk of death by 37 percent.

The results of this trial are encouraging, especially because no previous trial of radiotherapy plus chemotherapy has shown a survival benefit over radiotherapy alone. Nevertheless, the prognosis for patients with glioblastoma multiforme remains poor. The results with temozolomide should serve as a stepping-stone to much better treatment for brain tumors.

SEE P. 987; EDITORIAL, P. 1036

ORIGINAL ARTICLE

**MGMT Gene Silencing and the Response to Temozolomide in Glioblastoma**

In this companion to the randomized trial of temozolomide in glioblastoma, also reported in this issue of the *Journal*, the methylation status of the promoter of the *MGMT* (O<sup>6</sup>-methylguanine–DNA methyltransferase) DNA-repair gene in glioblastoma was determined. Methylation of the promoter silences the gene and thereby inhibits the repair of DNA damaged by temozolomide. Patients with a tumor that contained a methylated *MGMT* promoter benefited more from the drug than patients whose tumor contained an unmethylated *MGMT* promoter.

Determination of the methylation status of the *MGMT* promoter could be a useful predictor of responsiveness to treatment with DNA-damaging alkylating agents.

SEE P. 997; EDITORIAL, P. 1036

CLINICAL PRACTICE

**Neurocardiogenic Syncope**

A 23-year-old nurse presents for evaluation after having five episodes of syncope at work during the previous three months. All the episodes occurred while she was standing and were characterized by a feeling of light-headedness lasting one to two seconds and then an abrupt loss of consciousness. Two of the episodes caused falls that resulted in facial trauma. The syncope was brief and not associated with incontinence; it was followed by severe fatigue but no confusion. How should the patient be evaluated and treated?

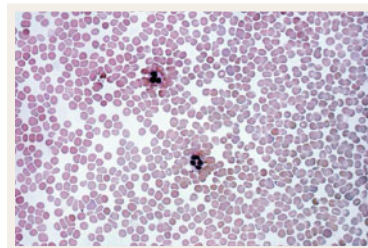
SEE P. 1004; CME, P. 1057

MEDICAL PROGRESS

**Anemia of Chronic Disease**

New therapeutic strategies have emerged along with our understanding that disturbances of iron homeostasis, impaired proliferation of erythroid progenitor cells, and blunted erythropoietin response occur in anemia of chronic disease. This review discusses advances in our knowledge of the causes and management of the condition.

SEE P. 1011; CME, P. 1059



CASE RECORDS OF THE MASSACHUSETTS GENERAL HOSPITAL

**A Woman with an Incidentally Discovered Adrenal Nodule**

A 59-year-old woman was incidentally found to have an adrenal cortical nodule on abdominal computed tomography for evaluation of a colovesical fistula. Two years earlier, she had been found to have mild hypertension, which proved difficult to control with antihypertensive medication. She was slightly obese. How should she be evaluated?

SEE P. 1025