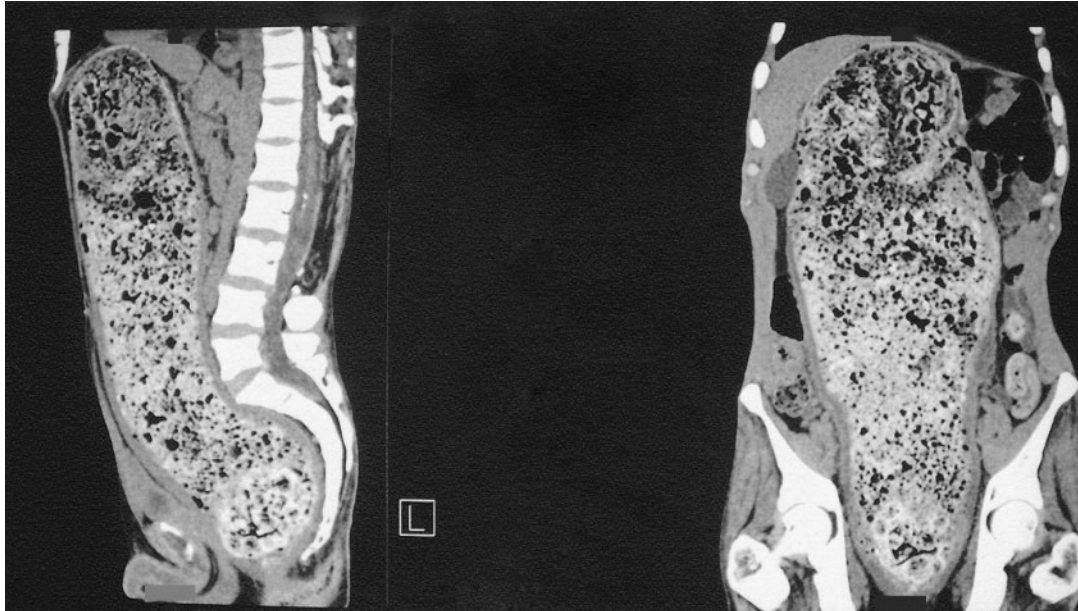


Severe Fecal Impaction



Yann Loubières, M.D.
Olivier Chereau, M.D.

Centre Hospitalier de Poissy–Saint
Germain-en-Laye
78105 Saint Germain-en-Laye, France

A 49-YEAR-OLD MAN WITH A HISTORY OF PARAPLEGIA DUE TO POLIOMYELITIS, surgical treatment of a lumbar ependymoma, and chronic renal insufficiency due to a neuropathic bladder was admitted to the intensive care unit because of abdominal pain, vomiting and diarrhea, and hyperkalemia (serum potassium, 7 mmol per liter). Computed tomography of the abdomen showed a severe fecal impaction with marked compression of the abdominal viscera without any sign of colonic perforation. After rehydration and correction of the hyperkalemia, the patient underwent manual disimpaction under general anesthesia. His recovery was unremarkable.

Copyright © 2005 Massachusetts Medical Society.