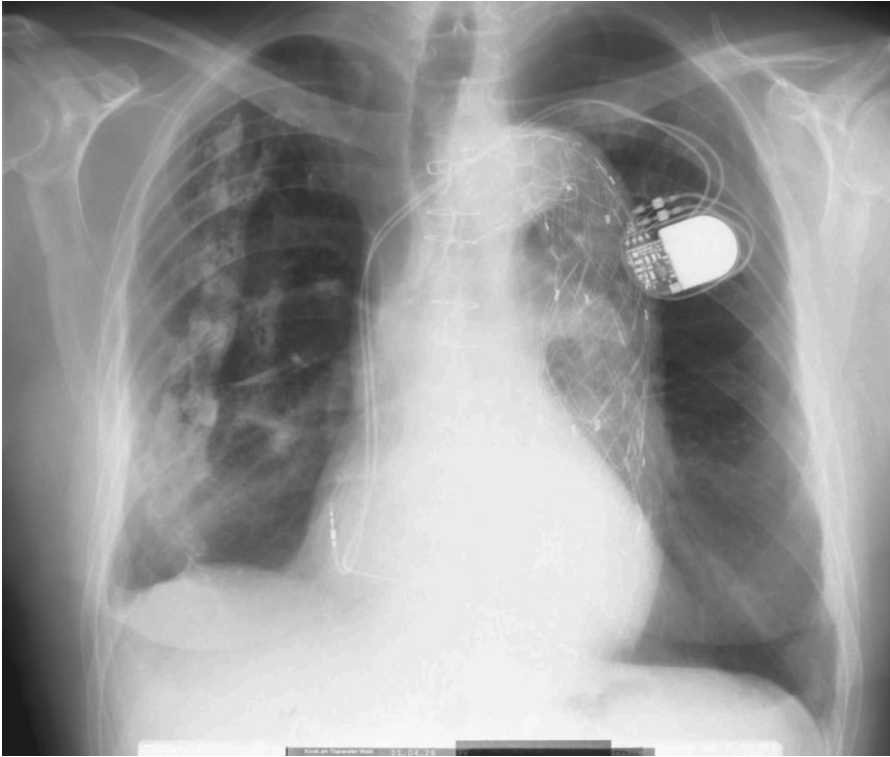


## Medical Mystery — 50 Years of Medical Progress



**B**ETWEEN 1949 AND 2002, A PATIENT UNDERWENT FOUR LIFESAVING PROCEDURES that documented medical progress throughout the past 50 years. This plain chest radiograph, which was performed when the patient was 74 years old, highlights all four of the procedures. What are they?

*Editor's note:* We invite our readers to submit their answers at [www.nejm.org/mystery](http://www.nejm.org/mystery). We will publish the diagnosis in the Correspondence section of the June 2, 2005, issue and e-mail it to everyone who submits an answer. All answers must be received by April 21, 2005.

Copyright © 2005 Massachusetts Medical Society.

Ralf Ostermaier, M.D.

Asklepios Fachkliniken München-Gauting  
D-82131 Gauting, Germany

Marianne Taut, M.D.

Klinik am Tharandter Wald  
D-09600 Niederschöna, Germany