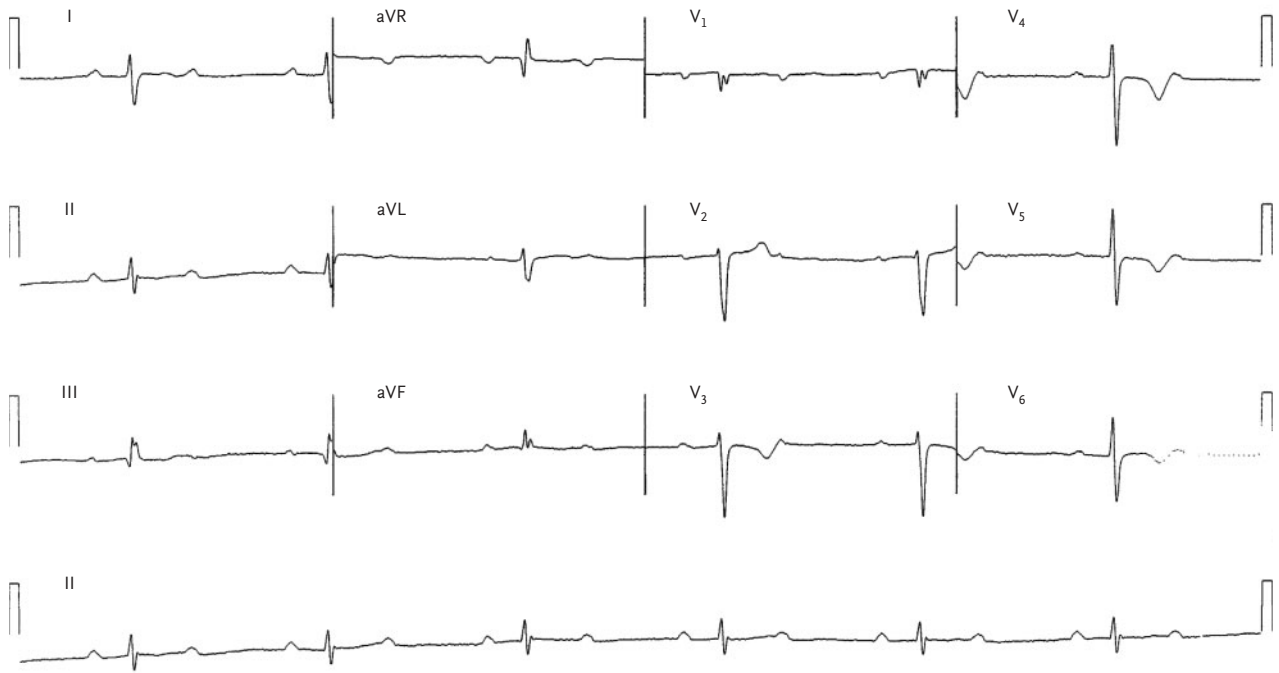


IMAGES IN CLINICAL MEDICINE

A Medical Mystery — Bradycardia



AT AN OFFICE VISIT IN JUNE 2004, A 49-YEAR-OLD MAN REPORTED FATIGUE, arthralgia, and headache, along with a two-day history of chest pain. The patient had hypercholesterolemia, for which he was taking atorvastatin (20 mg daily) and aspirin (81 mg); he had stopped smoking cigarettes 20 years earlier. The patient reported that his father had died at the age of 71 years of myocardial infarction. Physical examination revealed a pulse of 38 beats per minute. Electrocardiography was performed. What is the diagnosis?

Editor's note: We invite our readers to submit their answers at www.nejm.org/mystery. We will publish the diagnosis in the Correspondence section of the July 28, 2005, issue and e-mail it to everyone who submits an answer. All answers must be received by June 16, 2005.

Copyright © 2005 Massachusetts Medical Society.

Ralph Rosenberg, M.D.

University of Connecticut Health Center
Avon, CT 06001