

BRIEF REPORT

Survival after Treatment of Rabies with Induction of Coma

Rodney E. Willoughby, Jr., M.D., Kelly S. Tieves, D.O.,
George M. Hoffman, M.D., Nancy S. Ghanayem, M.D.,
Catherine M. Amlie-Lefond, M.D., Michael J. Schwabe, M.D.,
Michael J. Chusid, M.D., and Charles E. Rupprecht, V.M.D., Ph.D.

SUMMARY

We report the survival of a 15-year-old girl in whom clinical rabies developed one month after she was bitten by a bat. Treatment included induction of coma while a native immune response matured; rabies vaccine was not administered. The patient was treated with ketamine, midazolam, ribavirin, and amantadine. Probable drug-related toxic effects included hemolysis, pancreatitis, acidosis, and hepatotoxicity. Lumbar puncture after eight days showed an increased level of rabies antibody, and sedation was tapered. Paresis and sensory denervation then resolved. The patient was removed from isolation after 31 days and discharged to her home after 76 days. At nearly five months after her initial hospitalization, she was alert and communicative, but with choreoathetosis, dysarthria, and an unsteady gait.

From the Departments of Pediatric Infectious Diseases (R.E.W., M.J.C.), Pediatric Critical Care Medicine (K.S.T., N.S.G.), Pediatric Anesthesiology (G.M.H.), and Pediatric Neurology (C.M.A.-L., M.J.S.), Medical College of Wisconsin, Milwaukee; and the Centers for Disease Control and Prevention, Atlanta (C.E.R.). Address reprint requests to Dr. Willoughby at the Department of Pediatric Infectious Diseases, 8701 Watertown Plank Rd., Midwest Athletes against Childhood Cancer Fund Research Center, Suite 3019, Milwaukee, WI 53226, or at rewillou@mail.mcw.edu.

N Engl J Med 2005;352:2508-14.
Copyright © 2005 Massachusetts Medical Society.

A related video is available at
www.nejm.org

RABIES IN HUMANS IS A FATAL ILLNESS CHARACTERIZED BY SEVERE EN- cephalopathy and generalized paresis. When the disease is not treated, death typically occurs within five to seven days after the onset of symptoms. Medical management may prolong survival up to 133 days.^{1,2} There is scant evidence to indicate that any treatment alters median survival, although five people have survived after receiving immunoprophylaxis before the onset of symptoms.^{3,4} We report the survival of a patient with rabies who was treated with an intense antiexcitotoxic strategy while the native immune response matured but who received no immune prophylaxis.

CASE REPORT

The patient was a 15-year-old girl who rescued and released a bat that struck an interior window. She sustained a 5-mm laceration to her left index finger from the bat. The wound was washed with peroxide. No medical attention was sought, and no rabies post-exposure prophylaxis was administered. The patient continued to excel in school and play sports until one month after exposure, when she experienced generalized fatigue and paresthesia of the left hand. Two days later diplopia developed and she felt unsteady. The next day, she had nausea and vomiting without fever. A neurologist noted partial bilateral sixth-nerve palsy and ataxia. The results of magnetic resonance imaging and angiography of her brain were unremarkable. By the fourth day after the onset of symptoms, blurred vision, weakness of the left leg, and a gait abnormality were present. On the fifth day, fever (38.8°C), slurred speech, nystagmus, and tremors of the left arm developed. With the progression of symptoms and an elicited history of a bat bite, the patient was transferred to our facility.

On the first hospital day, the patient was febrile (temperature, 38.2°C) and semiobtunded but answered simple questions and complied with simple commands during diagnostic maneuvers. She had scanning speech, bilateral sixth-nerve palsies, decreased upward gaze, dysarthria, myoclonus, intention tremor of the left arm, and ataxia. Samples of serum, cerebrospinal fluid, nuchal skin, and saliva were submitted to the Centers for Disease Control and Prevention (CDC) for the diagnosis of rabies. Repeated brain magnetic resonance imaging and angiography showed no abnormalities. The patient began salivating, with uncoordinated swallowing, and was intubated for airway protection. On the second hospital day, the presence of rabies virus-specific antibody in her cerebrospinal fluid and serum was confirmed by the CDC. Attempts to isolate rabies virus, detect viral antigen, and amplify viral nucleic acid from two skin biopsies and nine saliva samples were unsuccessful.

The patient's parents were counseled about her diagnosis and prognosis. We offered both hospice care and an aggressive approach on the basis of an untested strategy that combined antiexcitatory and antiviral drugs with supportive intensive care. We provided information about the probable failure of antiviral therapy and the unknown effect of the proposed therapy, as well as the possibility of severe disability if the patient were to survive. The patient's parents requested that we institute aggressive care on the basis of the principles we had discussed.

We administered ketamine at 2 mg per kilogram of body weight per hour with midazolam at 1 to 3.5 mg per kilogram of body weight per hour to suppress background activity on electroencephalography so that only one to two seconds of cerebral activity were interspersed (Fig. 1). Oxygen delivery was optimized without inotropic agents by red-cell transfusion to maintain the hemoglobin level at more than 10 g per deciliter, appropriate volume loading, and mechanical ventilation targeting arterial normoxia and mild hypercapnia.⁵ Adequacy of oxygen delivery to organs was monitored by intermittent assessment of venous saturation, and brain and somatic oxygenation by near-infrared spectroscopy.⁶ Heparin (10 U per kilogram per hour) was administered prophylactically.⁷

After the induction of coma and on the basis of discussions with scientists at the CDC, we instituted antiviral therapy. Studies in animals have shown little penetration of ribavirin into the central ner-

vous system, and it has had little effect in animal models, but we administered the drug with the rationale that elevated protein levels in the cerebrospinal fluid indicated permeability of the blood-brain barrier (Table 1) and that ribavirin might protect against rabies myocarditis.³ Ribavirin was administered on the third hospital day, with a loading dose of 33 mg per kilogram followed by a maintenance dose of 16 mg per kilogram every six hours. Interferon alfa was not used because of its neurotoxicity. Neither rabies vaccine nor rabies immune globulin was administered because of the patient's demonstrated immune response and the potential for harm from a potentiated immune response.⁸ Amantadine (200 mg per day, administered enterally) was added on the fourth hospital day because of its *in vitro* activity against rabies virus, as well as its antiexcitotoxic activity, which is distributed more rostrally in the brain than is that of ketamine.^{9,10}

High doses of benzodiazepines with supplemental barbiturates were necessary to maintain burst suppression. Limited availability of preservative-free midazolam necessitated the use of midazolam containing 1 percent benzyl alcohol. Biochemical evidence of hemolysis and acidosis was detected by the fifth hospital day. The hemoglobin level declined from 13.7 to 10.9 g per deciliter, whereas the lactate dehydrogenase level rose from 420 to 1020 U per liter over seven days, a finding that was consistent with hemolysis, probably after a cumulative total of 276 mg per kilogram of ribavirin had been administered. An arterial base excess of 2.7 mmol per liter declined to -3.8 mmol per liter over five days, which was consistent with metabolic acidosis, without a change in the blood lactate level, probably reflecting the cumulative total of 362 mg per kilogram of benzyl alcohol. Ribavirin was reduced to 8 mg per kilogram for nine doses, and midazolam was tapered to 1.5 mg per kilogram per hour, with phenobarbital supplementation to maintain burst suppression.

There were minimal systemic effects of brainstem and peripheral neuropathy. The patient had transient evidence of both deficiency and excess of antidiuretic hormone on the fifth through seventh hospital days. Clinical autonomic denervation developed on the fifth hospital day, with reduced cardiac variability (Fig. 1) and higher central venous pressure.^{1,11-13} Salivation decreased on the eighth hospital day. The patient's skin became flushed, and ileus developed. Increased levels of liver aminotransferase (52 IU per liter), lipase (1193 U per milli-

liter), and amylase (288 U per milliliter) were noted. Lipase and amylase peaked on the 15th to 18th hospital days (at 2532 U and 539 U per milliliter, respectively), but without enlargement of the pancreas on sonography. A lumbar puncture on the eighth hospital day showed an increased level of rabies-virus antibody in both the serum and cerebrospinal fluid (Fig. 1 and Table 1). Ketamine was tapered over 24 hours, and diazepam was given to replace midazolam.

On the 10th hospital day, the patient responded to suctioning with increases in pulse and blood pressure. A high fever developed on the 12th hospital day, without leukocytosis or culture evidence of infection. The patient's fever did not respond to acetaminophen, ibuprofen, ketorolac, or external cooling. On the 14th day, therapy was intensified with ketamine, high-dose diazepam, and amantadine, without effect on her fever (Fig. 1). Studies in both animals and humans describe marked poikilothermia in rabies.^{1,14} A reduction in the room temperature by 5.5°C on the 15th day was followed by a 3.6°C drop in core body temperature. Ketamine and diazepam were lowered and amantadine continued for one week.

Although the electroencephalographic findings improved after the initial tapering of drugs, the patient had briskly reactive pupils but no other cranial-nerve function on the ninth day. Motor examination showed complete flaccidity, without spontaneous movement or movement in response to pain and the absence of deep-tendon reflexes. Patellar deep-tendon reflexes developed on the 12th day, when the patient also opened her mouth in response to sternal pressure. She blinked when eyedrops were administered and regained eye movements on the 14th day. By the 16th day, she opened her mouth to assist with care and raised her eyebrows in response to speech. On the 19th day, she wiggled her toes and squeezed hands in response to commands, fixed her gaze preferentially on her mother, and had an apneustic breathing pattern associated with dystonic opening of her jaw. Computed tomography of her head was normal.

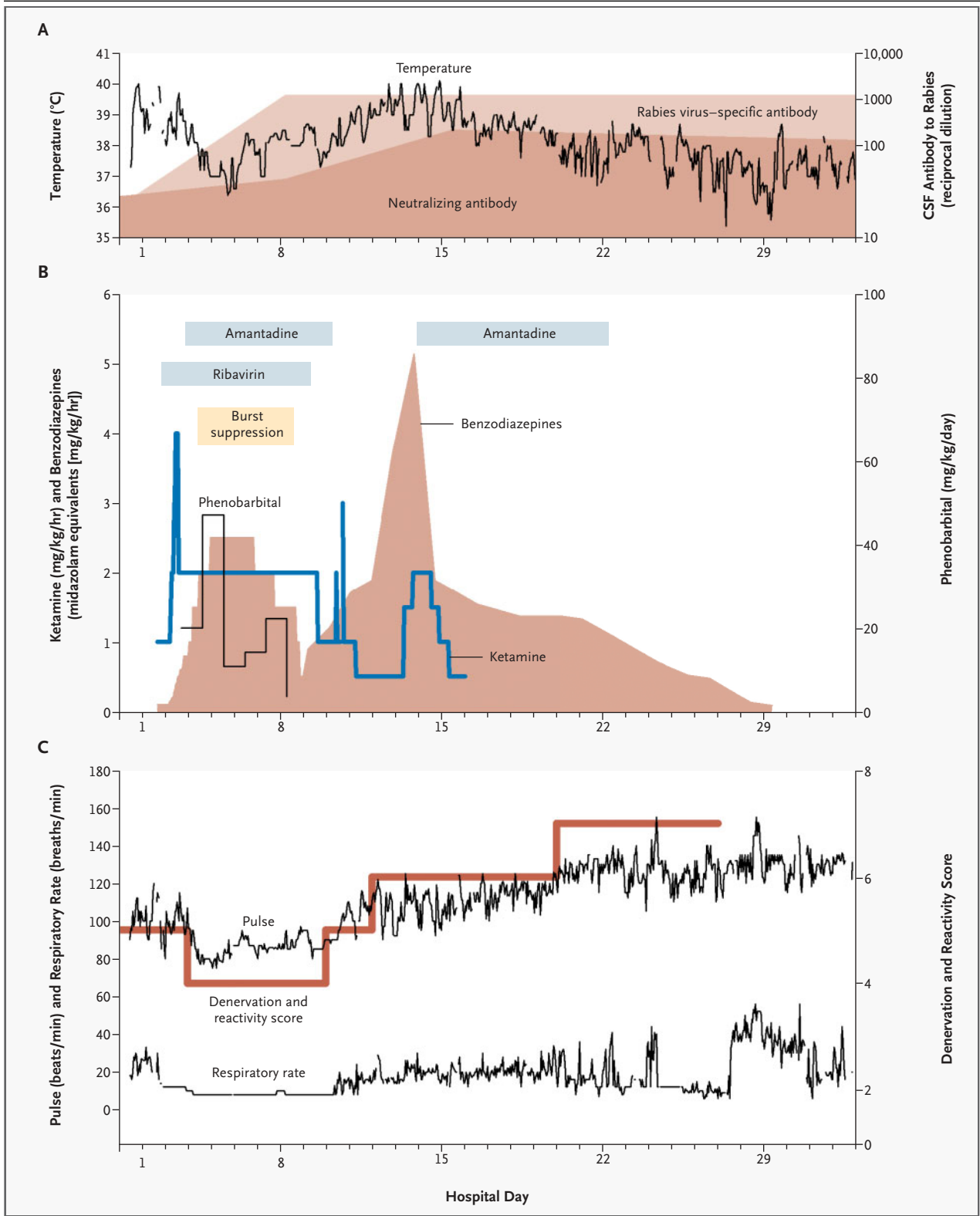
On the 20th day, patellar and ankle deep-tendon reflexes became hyperreflexic, and deep-tendon reflexes in the biceps and triceps developed. Her attention span was 10 to 30 seconds. On the same day, the patient had respiratory distress associated with diaphoresis, tearing of the eyes, the production of thick secretions, and prolonged episodes of coughing and gagging. This condition responded

Figure 1 (facing page). Relationship between Vital Signs in a Patient with Rabies and the Treatment Regimen.

Panel A shows the relationship between temperature and titers of total rabies virus–specific antibody and neutralizing antibody in cerebrospinal fluid (CSF), according to hospital day. A pronounced febrile inflammatory syndrome in the second week was associated with the emergence of neutralizing antibodies in the CSF. Panel B shows the effects of the administration of ketamine, benzodiazepines (in midazolam equivalents, with 3 mg midazolam equal to 1 mg diazepam), phenobarbital, amantadine, and ribavirin. Burst suppression was achieved after an initial sleep pattern was established by electroencephalography. In Panel C, a loss of variability in pulse and respiratory rate and salivary secretions (with an arbitrary score of 4) was followed by a return of heart-rate variability (with a score of 5) and then hyperreactivity (including tearing of the eyes, the production of thick secretions, coughing, and gagging, with a score of 6) and later bronchospasm (with a score of 7).

to applications of lidocaine to her hypopharynx. On the 22nd day, she had episodes of prolonged expiratory phase, responsive to albuterol or suctioning. On the 23rd day, she sat in bed, holding her head erect. On the 26th day, she clearly objected to new staff members, a tremor developed in her jaw, and she showed passive tone when her extremities were moved. She was extubated on the 27th day and later slept for 8 consecutive hours and had 60 seconds of sustained alertness. There was persistent jaw dystonia and limited spontaneous movement. On the 30th day, she cried spontaneously and acknowledged sadness as opposed to fear or pain. Deep-tendon reflexes in her biceps and triceps became hyperreflexic, whereas patellar and ankle reflexes normalized. She reported having no skin hyperesthesia or dysesthesia.

Given her continued neutralizing antibody response to rabies virus in cerebrospinal fluid and blood and our inability to isolate the virus or detect viral nucleic acid in saliva, the patient was considered cleared of transmissible rabies and removed from isolation on the 31st day. After rehabilitation, she was discharged to her home on the 76th day (Fig. 2). In a clinic visit 131 days after her initial hospitalization, she smiled, laughed, and interacted with the examiner; her speech was dysarthric (Video Clip 1 in the Supplementary Appendix, available with the full text of this article at www.nejm.org). The patient was able to dress herself, ate a normal diet, slept well, and attended high school part-time. She had constant buccolingual choreoathetosis with generalized choreoathetosis and in-



termittent dystonia and ballismus, which produced a lurching gait and fine-motor difficulties (Video Clip 2 in the Supplementary Appendix). She was able to write legibly but slowly and to type with her index fingers. She had normal extremity tone, bilateral upward-going toes, and no clonus. She had decreased dorsiflexion in the left ankle and decreased grip in the left hand. She had intact sense of position and light touch.

DISCUSSION

At the time of the patient’s transfer to our facility, a search of the recent literature had confirmed the futility of antiviral therapy and immune modulation in the treatment of clinical rabies. This finding was confirmed by experience at the CDC. We noted that the pathology of the human brain in cases of rabies reflected secondary complications rather than any clear primary process and that a normal immune system cleared the virus.^{2,7,15,16} Clinical reports included the hypothesis that death resulted from “neurotransmitter imbalance” and autonomic failure; supportive care was predicted to succeed.^{5,7,15,17,18} A search of the literature regarding neurotransmitters in rabies identified ketamine as an N-methyl-D-aspartate (NMDA)–receptor antagonist with specific activity against rabies in animal models.¹⁹ We conceived a strategy to try to protect the brain from injury while enabling the immune system to mount a natural response and clear the virus. Hypothermia was ruled out because of its effects on immune function.²⁰ We elected to induce therapeutic coma using γ -aminobutyric acid (GABA)–receptor agonism

with benzodiazepines and barbiturates, along with NMDA-receptor antagonism with ketamine and amantadine, to reduce excitotoxicity, brain metabolism, and autonomic reactivity.²¹⁻²³

This improvised approach was a logical extension of previous efforts to prevent complications through aggressive critical care.^{5,7,18} The induction of coma was associated with a remarkably uneventful course in the intensive care unit, suggesting that much of the dysautonomia characteristic of rabies can be avoided with therapeutic sedation anesthesia. An alternative hypothesis is that this patient would not have developed substantial dysautonomia. Autonomic hyperreflexia emerged while the drugs were being tapered, which suggests a parallel to the hypersensitivity to environmental stimuli seen in tetanus, with a general preservation of higher cortical function.^{7,24} Induction of coma through GABA agonism with NMDA antagonism may have conferred specific benefit. Although similar strategies have not shown consistent clinical efficacy for protection against excitotoxicity, our high-dose, multimodal regimen was more aggressive and the insult less cytopathic.

The patient survived, but with neurologic impairment. Although her improvement continued five months after her initial hospitalization, we cannot predict the long-term outcome. In addition to this girl, there are five well-documented survivors of rabies. All of the patients had received either occupationally related preexposure rabies vaccination or postexposure prophylaxis.⁴ Our patient survived with only naturally acquired immunity, although her exposure to rabies virus consisted of minimal

Table 1. Evolution of Inflammation and Levels of Rabies Virus–Specific Antibody in Cerebrospinal Fluid, According to Hospital Day.*

Hospital Day	White Cells	Red Cells	Glucose	Protein	CSF IFA		CSF RFFIT	Serum IFA		Serum RFFIT
	cells/mm ³				IgM	IgG		IgM	IgG	
1	22	130	57	75	32	32	47	32	128	102
8	121	0	54	80	32	2048	89	128	512	229
16	57	3	70	90	32	2048	556	32	2,048	651
45	15	1225	56	107	32	2048	285	8	8,192	1188
52	72	2950	46	113	32	2048	493	4	32,768	1604
66	8	1	48	71	<4	2048	1300	<4	32,768	1183

* CSF denotes cerebrospinal fluid, IFA indirect immunofluorescence antibody titer, and RFFIT rapid fluorescence focus inhibition test. Antibody values are expressed as the reciprocal dilution. The bat exposure occurred on September 12, 2004. Hospital days are numbered from October 18, 2004.

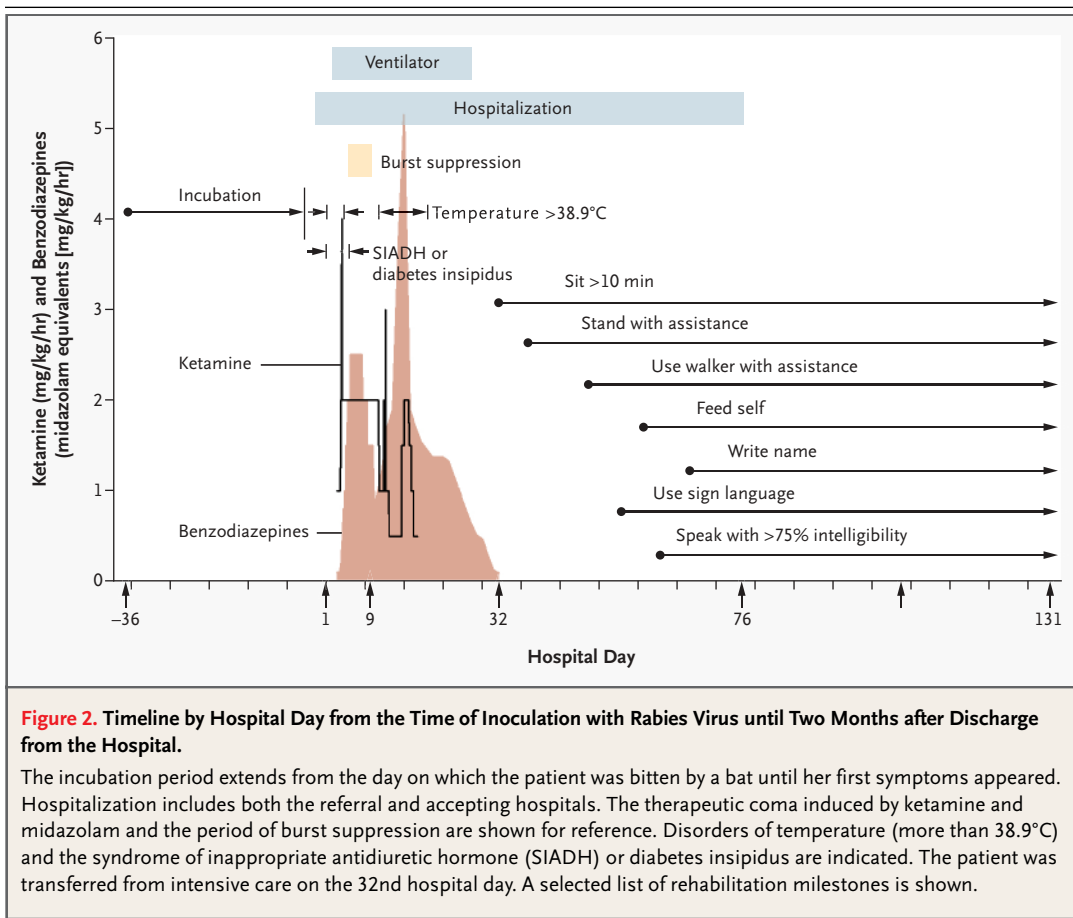
trauma at a distal body site, probably with a limited quantity of inoculum. She was young and athletic. The bat that bit her was not recovered, and we were unable to isolate or detect rabies virus from saliva, cerebrospinal fluid, or nuchal-biopsy specimens. We therefore cannot rule out the possibility that her survival was due to an unusual, more temperate or attenuated variant of the virus or a rare host polymorphism. Therapy may have been more effective than in past cases because of the inferred limited exposure to rabies virus, early recognition of the disease, and aggressive management.

Clearly, our experience with this patient requires replication in other patients and proof-of-concept experiments in animal models. Although our primary therapeutic intent was to provide protection against excitotoxic neuronal injury, the patient may have benefited from the dual action of ketamine and amantadine, drugs with activity against rabies virus. She incurred possible toxic effects associated with ribavirin (hemolysis, pancreatitis, and mitochondrial toxicity) and benzyl alcohol (acidosis).

Further review of the literature indicates that rabies virus infection of the heart is infrequent and limited in extent.^{12,13}

Ribavirin is variably toxic to mitochondria, and we measured profoundly depleted serum levels of coenzyme Q10 (0.30 μg per milliliter; range, 0.57 to 3.03) during the second month of her convalescence in association with persistently depressed myocardial contractility.²⁵ Rabies virus is largely restricted to the nervous system, so depletion of coenzyme Q10 was probably associated with her critical illness or administered drugs. For patients whose disease is diagnosed before their immune response to rabies virus can be detected, we suggest considering the use of ribavirin, but at a more limited dose or with concurrent supplementation with coenzyme Q10. Given that manifestations of dysautonomia were easily managed, we recommend a longer-acting benzodiazepine with less preservative for future patients.

Survival of this single patient does not change the overwhelming statistics on rabies, which has



the highest case fatality ratio of any infectious disease. Any regimen may be ineffective in cases associated with extremes of age, massive traumatic inoculation, or delayed diagnosis and must be coupled with strategies to reduce the risk of complications from long-term treatment in the intensive care unit.

We are indebted to the following people for their advice, excellent clinical care, laboratory diagnosis, or chart abstraction: S. Connolly, R.N.; A. Church, R.N.; L. Grade, R.N.; C. Hanlon, V.M.D.; J. Kane, M.D.; A. Joseph, M.D.; I. Kuzmin, Ph.D.; K. Larsen, R.N.; B. Ludwig, R.N.; P. Morrill; K. Murkowski, R.R.T.; M. Niezgoda, M.S.; N. Norins, M.D.; L. Orciari, M.S.; L. Quarterman, R.N.; J. Surgis; J. Twanow, M.D.; and P. Yager.

REFERENCES

- Gode GR, Raju AV, Jayalakshmi TS, Kaul HL, Bhide NK. Intensive care in rabies therapy: clinical observations. *Lancet* 1976;2:6-8.
- Emmons RW, Leonard LL, DeGenaro F Jr, et al. A case of human rabies with prolonged survival. *Intervirology* 1973;1:60-72.
- Jackson AC, Warrell MJ, Rupprecht CE, et al. Management of rabies in humans. *Clin Infect Dis* 2003;36:60-3.
- Willoughby RE, Rotar MM, Dohnau HL, et al. Recovery of a patient from clinical rabies — Wisconsin, 2004. *MMWR Morb Mortal Wkly Rep* 2005;53:1171-3.
- Hattwick MA, Weis TT, Stechschulte CJ, Baer GM, Gregg MB. Recovery from rabies: a case report. *Ann Intern Med* 1972;76:931-42.
- Hoffman GM, Stuth EA, Jaquiss RD, et al. Changes in cerebral and somatic oxygenation during stage 1 palliation of hypoplastic left heart syndrome using continuous regional cerebral perfusion. *J Thorac Cardiovasc Surg* 2004;127:223-33.
- Bhatt DR, Hattwick MA, Gerdson R, Emmons RW, Johnson HN. Human rabies: diagnosis, complications, and management. *Am J Dis Child* 1974;127:862-9.
- Mrak RE, Young L. Rabies encephalitis in humans: pathology, pathogenesis and pathophysiology. *J Neuropathol Exp Neurol* 1994;53:1-10.
- Superti F, Seganti L, Pana A, Orsi N. Effect of amantadine on rhabdovirus infection. *Drugs Exp Clin Res* 1985;11:69-74.
- Porter RH, Greenamyre JT. Regional variations in the pharmacology of NMDA receptor channel blockers: implications for therapeutic potential. *J Neurochem* 1995;64:614-23.
- Maton PN, Pollard JD, Davis JN. Human rabies encephalomyelitis. *Br Med J* 1976;1:1038-40.
- Jogai S, Radotra BD, Banerjee AK. Rabies viral antigen in extracranial organs: a post-mortem study. *Neuropathol Appl Neurobiol* 2002;28:334-8.
- Jackson AC, Ye H, Phelan CC, et al. Extraneural organ involvement in human rabies. *Lab Invest* 1999;79:945-51.
- Bell JF, Moore GJ. Effects of high ambient temperature on various stages of rabies virus infection in mice. *Infect Immun* 1974;10:510-5.
- Rubin RH, Sullivan L, Summers R, Gregg MB, Sikes RK. A case of human rabies in Kansas: epidemiologic, clinical, and laboratory considerations. *J Infect Dis* 1970;122:318-22.
- Lodmell DL, Bell JF, Moore GJ, Raymond GH. Comparative study of abortive and nonabortive rabies in mice. *J Infect Dis* 1969;119:569-80.
- Jackson AC. Rabies virus infection: an update. *J Neurovirol* 2003;9:253-8.
- Gode GR, Saksena R, Batra RK, Kalia PK, Bhide NK. Treatment of 54 clinically diagnosed rabies patients with two survivals. *Indian J Med Res* 1988;88:564-6.
- Lockhart BP, Tordo N, Tsiang H. Inhibition of rabies virus transcription in rat cortical neurons with the dissociative anesthetic ketamine. *Antimicrob Agents Chemother* 1992;36:1750-5.
- Beilin B, Shavit Y, Razumovsky J, Wolloch Y, Zeidel A, Bessler H. Effects of mild perioperative hypothermia on cellular immune responses. *Anesthesiology* 1998;89:1133-40.
- Reich DL, Silvay G. Ketamine: an update on the first twenty-five years of clinical experience. *Can J Anaesth* 1989;36:186-97.
- Wang X, Shimizu-Sasamata M, Moskowitz MA, Newcomb R, Lo EH. Profiles of glutamate and GABA efflux in core versus peripheral zones of focal cerebral ischemia in mice. *Neurosci Lett* 2001;313:121-4.
- Nargi-Aizenman JL, Havert MB, Zhang M, Irani DN, Rothstein JD, Griffin DE. Glutamate receptor antagonists protect from virus-induced neural degeneration. *Ann Neurol* 2004;55:541-9.
- Warrell DA, Davidson NM, Pope HM, et al. Pathophysiologic studies in human rabies. *Am J Med* 1976;60:180-90.
- Fleischer R, Boxwell D, Sherman KE. Nucleoside analogues and mitochondrial toxicity. *Clin Infect Dis* 2004;38:e79-e80.

Copyright © 2005 Massachusetts Medical Society.

POWERPOINT SLIDES OF JOURNAL FIGURES AND TABLES

At the *Journal's* Web site, subscribers can automatically create PowerPoint slides of *Journal* figures and tables. Click on a figure or table in the full-text version of any article at www.nejm.org, and then click on PowerPoint Slide for Teaching. A PowerPoint slide containing the image, with its title and reference citation, can then be downloaded and saved.