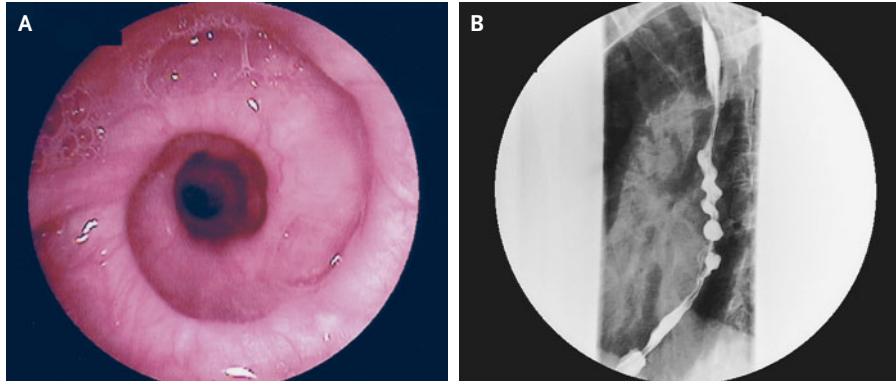


IMAGES IN CLINICAL MEDICINE

## Corkscrew Esophagus



Giovanni Cammarota, M.D.  
Maria Certo, M.D., Ph.D.

A. Gemelli University Hospital  
00168 Rome, Italy

**A**N 81-YEAR-OLD MAN WAS ADMITTED TO THE HOSPITAL BECAUSE OF A six-month history of intermittent dysphagia, regurgitation, and vomiting during meals. Upper gastrointestinal endoscopy revealed an abnormal appearance of the esophageal peristalsis; it resembled the features of a winding staircase (Panel A). Radiographs of the esophagus that were performed with the use of barium contrast material showed a spiral formation of the barium column up to the cervical esophagus (Panel B). Manometry confirmed an alternative form of normal peristalsis and an absence of peristalsis in the esophageal body. On further questioning, the patient reported a six-month history of persistent nocturnal coughing. Radiographs and computed tomographic examination of the chest, together with the findings on bronchoscopy, were compatible with the diagnosis of pneumonia caused by recurrent aspiration due to ineffective esophageal peristalsis. Aging may result in physiological deterioration of esophageal motility, rendering patients susceptible to pulmonary complications.

Copyright © 2005 Massachusetts Medical Society.

Web-only Images in Clinical Medicine are published every week in the *Journal*. They are listed (with e page numbers) in the table of contents on the cover of the printed *Journal* and can be seen at [www.nejm.org](http://www.nejm.org).