

BRIEF REPORT

Ovarian Transplantation between Monozygotic Twins Discordant for Premature Ovarian Failure

Sherman J. Silber, M.D., Kathleen M. Lenahan, R.N., David J. Levine, M.D.,
Jorge A. Pineda, M.D., Kim S. Gorman, B.A., Michael J. Friez, Ph.D.,
Eric C. Crawford, Ph.D., and Roger G. Gosden, Ph.D., D.Sc.

SUMMARY

Monozygotic 24-year-old twins presented with discordant ovarian function. One had had premature ovarian failure at the age of 14 years, whereas her sister had normal ovaries and three naturally conceived children. After unsuccessful egg-donation therapy, the sterile twin received a transplant of ovarian cortical tissue from her sister by means of a minilaparotomy. Within three months after transplantation, the recipient's cycles resumed and serum gonadotropin levels fell to the normal range. During the second cycle, she conceived, and her pregnancy progressed uneventfully. At 38 weeks' gestation, she delivered a healthy-appearing female infant.

From St. Luke's Hospital, St. Louis (S.J.S., K.M.L., D.J.L., J.A.P.); Paternity Testing, Columbia, Md. (K.S.G.); Greenwood Genetic Center, Greenwood, S.C. (M.J.F.); Sentara Hospital Cytogenetics Laboratory, Norfolk, Va. (E.C.C.); and Weill Medical College of Cornell University, New York (R.G.G.). Address reprint requests to Dr. Silber at the Infertility Center of St. Louis, St. Luke's Hospital, 224 S. Woods Mill Rd., Suite 730, St. Louis, MO 63017, or at drsherm@aol.com or silber@infertile.com.

This article was published at www.nejm.org on June 7, 2005.

N Engl J Med 2005;353:58-63.

Copyright © 2005 Massachusetts Medical Society.

NUMEROUS STUDIES HAVE CONFIRMED THAT OVARIAN GRAFTS CAN RESTORE ovarian function and fertility in sterilized animals.¹⁻⁶ With the rise in the number of young survivors of neoplastic and other diseases who are rendered sterile by gonadotoxic drugs or radiation, the possibility of ovarian transplantation in humans is receiving increased attention. Some centers offer to bank ovarian tissue of young patients with cancer, with the aim of restoring fertility by transplanting thawed ovarian tissue after they are cured or in long-term remission. If ovarian transplantation is proven to be safe and effective in humans, fertility preservation might become readily available for young women who need to delay childbearing for medical or social reasons. We report a case of ovarian transplantation between healthy monozygotic twins by means of a simple cortical-graft technique. One twin had premature menopause, whereas the other twin was fertile and volunteered to donate one of her ovaries.

CASE REPORT

The patients were 24-year-old twin sisters who were confirmed to be monozygotic by means of genetic fingerprinting at 15 loci. One of the sisters (the donor) had three naturally conceived children and had been using oral contraceptives during the year preceding transplantation. Secondary amenorrhea had developed in the other twin (the recipient) at the age of 14 years, after three years of cycles with scanty menses. She had had no menses for 10 years before the ovarian transplantation. Her serum follicle-stimulating hormone (FSH) level at the age of 15 years ranged from 49 to 104 mIU per milliliter. When she was 20 years old, a laparoscopic examination and ovarian biopsy revealed atrophic, elongated ("streak") gonads with no follicles and a small uterus with an otherwise normal reproductive tract. At the age of 23 years, the sisters underwent two un-

successful cycles of in vitro fertilization (IVF) at another center. The donor sister received controlled ovarian stimulation with standard doses of hormones for egg donation. A total of 14 oocytes (9 of which were mature) were recovered from 16 pre-ovulatory follicles, and 7 zygotes were generated by IVF. Pregnancy was not achieved after the transfer of two fresh embryos or after the transfer of two cryopreserved embryos in a subsequent cycle of IVF.

The twins declined any further attempts at egg donation. Informed that an attempt could be made to transplant ovarian tissue, they requested that this approach be tried instead to restore fertility to the menopausal sister. The women were in excellent general health, and the donor's ovarian function was considered to be normal on the basis of her reproductive history, peripheral hormone levels, ovarian ultrasonographic findings, and previous ovarian stimulation for IVF. Peripheral hormones measured in the infertile twin one day before the transplantation remained at menopausal levels: 75 mIU of FSH per milliliter, 32 mIU of luteinizing hormone (LH) per milliliter, and 4 pg of estradiol per milliliter.

METHODS

SURGERY

The surgical procedure was approved by the ethics review committee of St. Luke's Hospital, and both sisters provided written informed consent. They were screened for human immunodeficiency virus type 1 and hepatitis B and C viruses, and the recipient stopped taking oral contraceptives as hormone-replacement therapy two weeks before surgery. The donor underwent laparoscopic removal of her left ovary under general anesthesia. The excised ovary was then dissected ex vivo. The ovarian cortical tissue was trimmed to a thickness of 1 to 2 mm by excising medullary tissue and bursting small antral follicles. This dissection was performed in Leibovitz (L15) medium on ice in less than one hour (Fig. 1A).

Meanwhile, the recipient underwent a minilaparotomy through a 3.5-cm incision above the pubis. The cortex of each streak ovary was resected under magnification of 16× to 25×, exposing the entire raw surface of the medulla. No follicles were observed. Hemostasis was meticulously controlled in the medulla with the use of pinpoint microbipolar forceps and continuous irrigation with heparin-treated saline in order to prevent the formation of a hematoma under the graft, but at the same time care

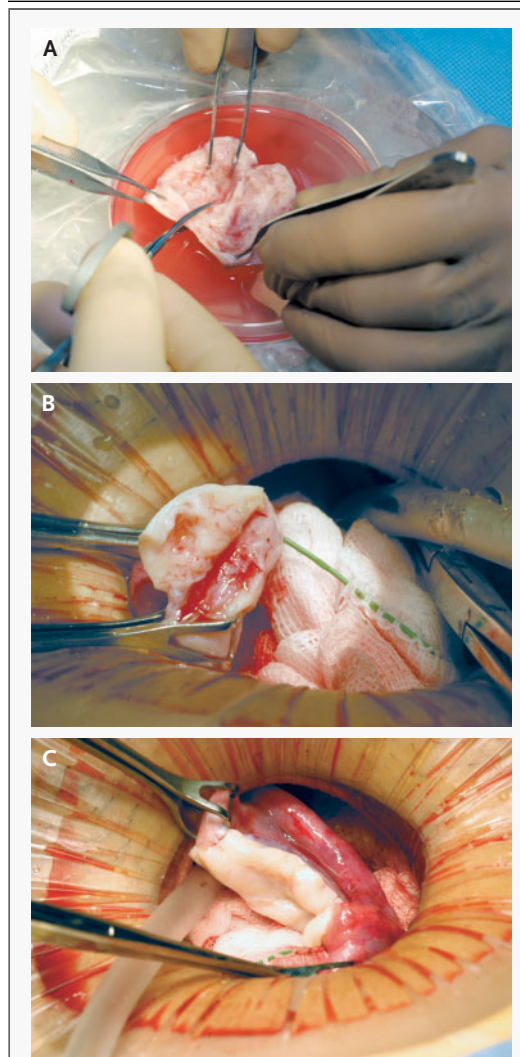


Figure 1. Ovarian Transplantation.

Panel A shows the ex vivo dissection of the donor ovarian cortex. Panel B shows the donor cortex being sutured to the medulla of the recipient after the empty recipient cortex has been removed. Panel C shows the transplant after the completion of the procedure.

was taken to avoid impairing revascularization by minimizing the amount of cautery. A section of approximately one third of the donor ovarian cortex was laid over the raw medulla of each ovary in the recipient and sutured onto the medulla with the use of 9-0 nylon interrupted sutures (Fig. 1B, 1C, and 2). The remaining third of the donor ovarian cortex was cryopreserved after equilibration in 1.5 M 1,2-propanediol and 0.1 M sucrose and slow cooling in an

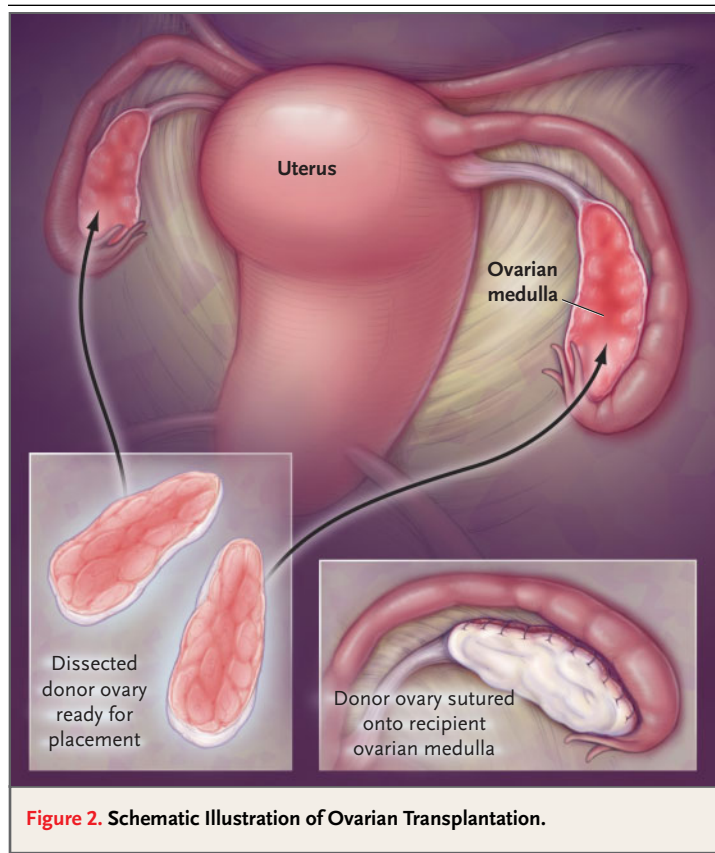


Figure 2. Schematic Illustration of Ovarian Transplantation.

automated freezer.^{7,8} Tissue from the ovaries of both women were fixed in Bouin's fluid for histologic examination.

LABORATORY INVESTIGATIONS

Spare cortical and medullary tissues were cultured for cytogenetic analyses according to standard procedures, including G-banding. In addition, enzymatically digested ovarian tissue obtained by direct harvest was examined by fluorescence in situ hybridization. Both women were also evaluated for skewed X-chromosome inactivation at the androgen receptor locus⁹ and for an increase in the number of CGG repeats in the *FMR1* gene (indicative of fragile X syndrome) by means of Southern analysis or the polymerase chain reaction, since these mutations have been associated with premature ovarian failure.^{10,11} Serum samples were analyzed for FSH, LH, and estradiol with the use of standard immunoassays.

RESULTS

Both patients recovered rapidly and returned to their home state one day after surgery. Seventy-one days

after transplantation, a 14-mm follicle had developed in the recipient; the serum estradiol level at this time was 154 pg per milliliter (Table 1) and the uterine-lining thickness was 8 mm. At 80 days, she had her first postoperative menses, although it lasted only a single day. The endocrine profile indicated that her ovaries then remained quiescent until 48 days later (128 days after transplantation), when a 14-mm follicle was again noted sonographically. The thickness of the uterine lining was 10 mm, the estradiol level was 193 pg per milliliter, and the LH level was 123.4 mIU per milliliter. Her basal body temperature then rose from 36.4° to 36.9°C and remained elevated for 13 days. At 141 days after transplantation, her serum FSH and LH had decreased to 9.1 and 4.7 mIU per milliliter, respectively. The following day, a heavy menstrual period began, and her basal body temperature dropped.

On day 3 of the second menstrual cycle (145 days after transplantation), the recipient's FSH level was 7.1 mIU per milliliter. On day 26 of the same cycle, her β human chorionic gonadotropin level was 828 mIU per milliliter. Ultrasonographic examination five weeks after her second menstrual period (day 176 after transplantation) revealed a normal intrauterine pregnancy with a well-defined secondary yolk sac; the β human chorionic gonadotropin level was then 30,289 mIU per milliliter. She had conceived naturally. At seven weeks, ultrasonography verified that she had a normally developing intrauterine pregnancy associated with a fetal heart rate of 148 beats per minute. The 22-week ultrasonogram was normal. She gave birth to a healthy-appearing girl at 38 weeks' gestation by vaginal delivery. The infant's birth weight was 3600 g, and the Apgar scores were 9 at one minute and 10 at five minutes.

All specimens (peripheral lymphocytes, ovarian cortex, and ovarian medulla) from both patients had a normal 46,XX karyotype, and G-banding did not reveal any structural chromosomal aberrations. Moreover, dual-colored fluorescence in situ hybridization of 250 cells from each sample of uncultured tissue with the use of probes for two genes on the sex chromosomes (*DXZ1* and *SRY*, Vysis) did not reveal any XX–XY mosaicism. The degree of inactivation of the X chromosome was within normal limits in both patients (50:50 for the donor and 65:35 for the recipient), and neither patient had an increase in the number of CGG repeats in the *FMR1* gene that was in the premutation or mutation range.

Tissue sections from each sister were compared.

Table 1. Serum Gonadotropin and Estradiol Levels before and after Isologous Ovarian Grafting.*

Days	Follicle-Stimulating Hormone	Luteinizing Hormone	Estradiol
	mIU/ml		
Before transplantation			
1	74.6	32.1	4
After transplantation			
44	90.3	33.7	—
71	45.6	36.9	154
80	First menses		
84	34.9	—	—
100	68.5	26.2	54
128	50.2	123.4	193
141	9.1	4.7	196
142	Second menses		
145	7.1	—	—
167†	—	—	—

* Dashes indicate that a measurement was not obtained.

† On day 167 after transplantation (day 26 of the second menstrual cycle), the β human chorionic gonadotropin level was 828 mIU per milliliter.

The streak ovaries of the recipient had no detectable follicles (Fig. 3). There was extensive fibrosis, including fibrotic remnants of old corpora albicantia presumably dating from the sporadic ovulatory cycles that had last occurred more than a decade earlier. The smaller fragments of tissue from the donor ovary appeared histopathologically normal and contained follicles of various sizes. Tissue from the contralateral ovary of the donor was not available for study, but its size and appearance suggested that this ovary was also normal.

DISCUSSION

We describe a successful pregnancy in a prematurely menopausal monozygotic twin who received an ovary from her healthy, fertile twin. The pregnancy was established spontaneously, without ancillary medical assistance. It is extremely unlikely that the restoration of ovarian function in this patient after transplantation was due to residual follicles in the streak ovary of the recipient; she had a decade-long history of amenorrhea with elevated gonadotropin levels on all occasions on which they were measured

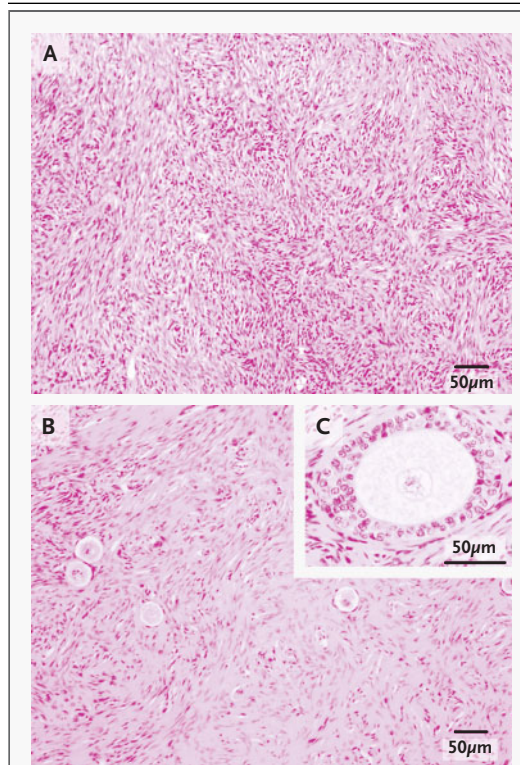


Figure 3. Histologic Findings in the Streak Ovary of the Recipient (Panel A) and the Ovary of the Donor (Panels B and C) (Hematoxylin and Eosin).

Follicles were completely absent in the recipient's ovary (Panel A). In contrast, her twin sister's ovary had four primordial follicles (Panel B) and a developing follicle (Panel C) in this section.

and no detectable follicles on pathological examination.

Studies in animals have indicated that only primordial follicles survive transplantation-related ischemia,¹² but the rapid onset of cyclicity in our patient suggested that at least one growing follicle had survived and grown to maturity. However, follicle recruitment may not have normalized until the second cycle, about three months after transplantation, when serum levels of gonadotropin and estrogen returned to levels characteristic of those in young, fertile women. Endometrial thickness also reached preovulatory dimensions at this time, and an LH surge and elevated basal body temperature indicated that ovulation had occurred. The patient conceived naturally during this cycle.

Grafting of ovarian cortex was chosen because it is minimally invasive and involves substantially less

risk and recovery time than a vascular graft (which one of us described in a report of testis transplantation between male homozygous twins discordant for anorchia¹³). Moreover, cortical grafting (in contrast to vascular anastomosis) affords the opportunity to cryopreserve additional ovarian tissue for a future transplantation, should it be required. To date, whole-ovary cryopreservation has been successful only in rats and would be unlikely to be effective with the much larger human ovary.¹⁴ Although heterotopic grafts of human (or monkey) cortical tissue can generate mature oocytes for IVF,¹⁵⁻¹⁷ we did not pursue that strategy in the present case because the twins had declined further attempts at IVF.

An important technical limitation of cortical grafting, whether orthotopic or heterotopic, is the potential for follicle atresia during the period of ischemia, before the tissue becomes revascularized^{12,18}; such an event might compromise long-term ovarian function. Yet experimental studies suggest that long-term ovarian function may not be compromised by grafting.⁶ Studies in animals have indicated that a short interval before conception is related to adequate follicular reserves and that the use of grafted ovarian cortex can result in prolonged resumption of fertility.⁶ In the current case, the recipient's low levels of serum FSH on day 3 of the second cycle (after she had received only two thirds of one ovary from her sister) and the rapid return of normal ovarian function suggest that normal menstrual cycles and fertility may resume in this patient after pregnancy. If, however, ovarian function were not maintained over the long term, the recipient could receive a second graft of remaining cryopreserved tissue.

The procedure we used is based on a simple method that was first described in sheep.¹⁹⁻²¹ In

the first reported clinical cases of ovarian autografting, ovarian function was transitory, perhaps because of a paucity of follicles in the grafted tissue as a result of prior chemotherapy.^{22,23} Recently, a viable pregnancy was reported after ovarian-tissue banking and transplantation in a patient who was thought to be sterile after treatment for Hodgkin's disease.²⁴ However, doubts have been expressed as to whether ovulation in that conception cycle occurred from the grafted tissue or from tissue left in situ and in close proximity to the graft.²⁵ It is impossible to verify the origin of the fertilized egg in that case retrospectively, but the present report provides a compelling demonstration that cortical grafts can restore fertility. Furthermore, our technique involved a single, simple procedure rather than repeated laparoscopic procedures to attach multiple slices of tissue to the pelvic wall. Cryopreservation is not required for this procedure, but if a second transplantation is required, frozen-thawed tissue can be used; experimental evidence suggests that cryopreservation should have only a minor effect on follicular wastage.⁷ Routine genetic testing revealed no obvious cause for the discordance between these monozygotic twin sisters, nor any obvious cause for concern about the health of future offspring.

Although ovarian transplantation between monozygotic twins will be rare, the demonstration that ovarian function can be restored and that natural conception and successful pregnancy can be achieved after transplantation of ovarian tissue may have broader implications for preserving fertility in young women, such as those who require potentially sterilizing treatment for cancer.

We are indebted to Dr. Braden Richmond for his follow-up care in Alabama, to Julie Heintzelman for assistance in the preparation of the manuscript, and to Debby Grenia for coordination of the studies.

REFERENCES

1. Nugent D, Meirou D, Brook PF, et al. Transplantation in reproductive medicine: previous experience, present knowledge and future prospects. *Hum Reprod Update* 1997; 3:267-80.
2. Gosden RG, Aubard Y. Transplantation of ovarian and testicular tissues (medical intelligence unit). Austin, Tex.: Landes Bioscience, 1996.
3. Sonmezer M, Oktay K. Fertility preservation in female patients. *Hum Reprod Update* 2004;10:251-66.
4. Parrott DMV. The fertility of mice with orthotopic ovarian grafts derived from frozen tissue. *J Reprod Fertil* 1960;1:230-41.
5. Gunasena KT, Villines TM, Critser ES, Critser JK. Live births after autologous transplant of cryopreserved mouse ovaries. *Hum Reprod* 1997;12:101-6.
6. Candy CJ, Wood MJ, Whittingham DG. Restoration of a normal reproductive lifespan after grafting of mouse ovaries. *Hum Reprod* 2000;15:1300-4.
7. Newton H, Aubard Y, Rutherford A, Sharma V, Gosden R. Low temperature storage and grafting of human ovarian tissue. *Hum Reprod* 1996;11:1487-91.
8. Gook DA, Edgar DH, Stern C. Effect of cooling rate and dehydration regimen on the histological appearance of human ovarian cortex following cryopreservation in 1,2-propanediol. *Hum Reprod* 1999;14:2061-8.
9. Allen RC, Zoghbi HY, Moseley AB, Rosenblatt HM, Belmont JW. Methylation of HpaII and HhaI sites near the polymorphic CAG repeat in the human androgen-receptor gene correlates with X chromosome inactivation. *Am J Hum Genet* 1992;51:1229-39.
10. Maddalena A, Richards CS, McGinniss MJ, et al. Technical standards and guidelines for fragile X: the first of a series of disease-specific supplements to the Standards and Guidelines for Clinical Genetics Laboratories of the American College of Medical Genetics. *Genet Med* 2001;3:200-5.

11. Sherman SL. Premature ovarian failure among fragile X premutation carriers: parent-of-origin effect? *Am J Hum Genet* 2000; 67:11-3.
12. Baird DT, Webb R, Campbell BK, Harkness LM, Gosden RG. Long-term ovarian function in sheep after ovariectomy and transplantation of autografts stored at -196°C . *Endocrinology* 1999;140:462-71.
13. Silber SJ. Transplantation of a human testis for anorchia. *Fertil Steril* 1978;30:181-7.
14. Wang X, Chen H, Yin H, Kim SS, Lin Tan S, Gosden RG. Fertility after intact ovary transplantation. *Nature* 2002;415:385.
15. Oktay K, Economos K, Kan M, Rucinski J, Veeck L, Rosenwaks Z. Endocrine function and oocyte retrieval after autologous transplantation of ovarian cortical strips to the forearm. *JAMA* 2001;286:1490-3.
16. Oktay K, Buyuk E, Veeck L, et al. Embryo development after heterotopic transplantation of cryopreserved ovarian tissue. *Lancet* 2004;363:837-40.
17. Lee DM, Yeoman RR, Battaglia DE, et al. Live birth after ovarian tissue transplant. *Nature* 2004;428:137-8.
18. Kim SS, Yang HW, Kang HG, et al. Quantitative assessment of ischemic tissue damage in ovarian cortical tissue with or without antioxidant (ascorbic acid) treatment. *Fertil Steril* 2004;82:679-85.
19. Gosden RG, Baird DT, Wade JC, Webb R. Restoration of fertility to oophorectomized sheep by ovarian autografts stored at -196°C . *Hum Reprod* 1994;9:597-603.
20. Aubard Y, Piver P, Cogni Y, Fermeaux V, Poulin N, Driancourt MA. Orthotopic and heterotopic autografts of frozen-thawed ovarian cortex in sheep. *Hum Reprod* 1999; 14:2149-54.
21. Salle B, Demirci B, Franck M, Rudigoz RC, Guerin JF, Lornage J. Normal pregnancies and live births after autograft of frozen-thawed hemi-ovaries into ewes. *Fertil Steril* 2002;77:403-8.
22. Oktay K, Karlikaya G. Ovarian function after transplantation of frozen, banked autologous ovarian tissue. *N Engl J Med* 2000; 342:1919.
23. Radford JA, Lieberman BA, Brison DR, et al. Orthotopic reimplantation of cryopreserved ovarian cortical strips after high-dose chemotherapy for Hodgkin's lymphoma. *Lancet* 2001;357:1172-5.
24. Donnez J, Dolmans MM, Demylle D, et al. Live birth after orthotopic transplantation of cryopreserved ovarian tissue. *Lancet* 2004;364:1405-10. [Erratum, *Lancet* 2004; 364:2020.]
25. Oktay K, Tilly J. Live birth after cryopreserved ovarian tissue autotransplantation. *Lancet* 2004;364:2091-3.

Copyright © 2005 Massachusetts Medical Society.

CLINICAL TRIAL REGISTRATION

The *Journal* encourages investigators to register their clinical trials in a public trials registry. The members of the International Committee of Medical Journal Editors plan to consider clinical trials for publication only if they have been registered (see *N Engl J Med* 2004;351:1250-1). The National Library of Medicine's www.clinicaltrials.gov is a free registry, open to all investigators, that meets the committee's requirements.