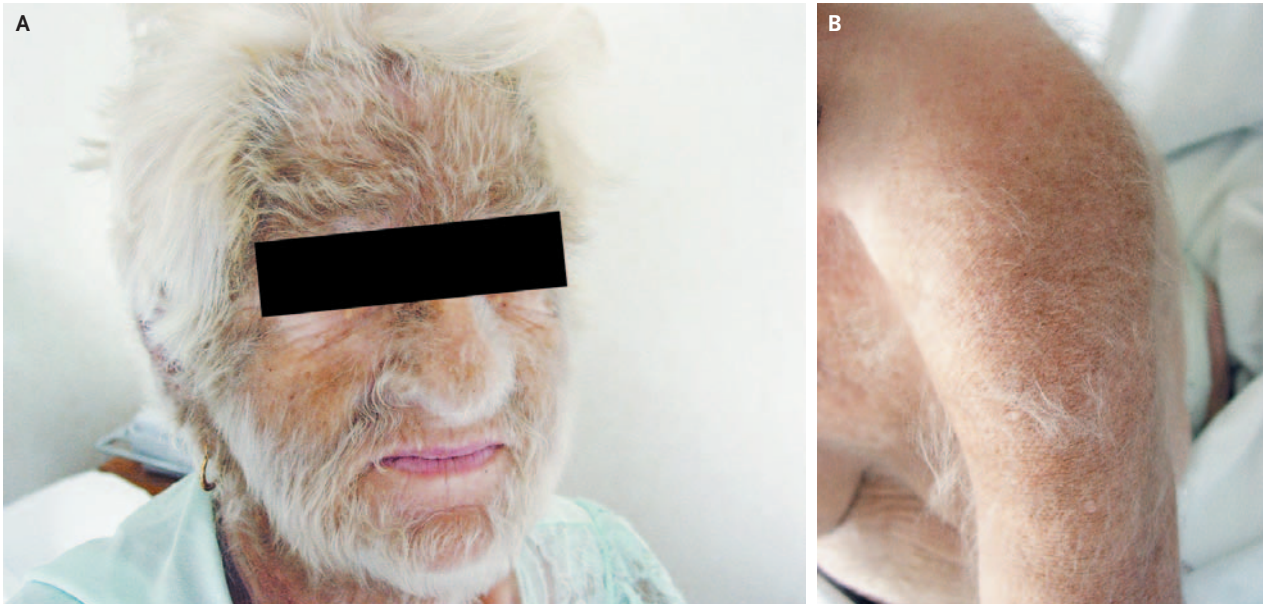


IMAGES IN CLINICAL MEDICINE

Acquired Hypertrichosis Lanuginosa



Gerard Lorette, M.D.
Annabel Maruani, M.D.

Hôpital Trousseau
Centre Hospitalier Universitaire de Tours
37044 Tours, France

A 68-YEAR-OLD WOMAN REQUESTED MEDICAL ATTENTION FOR A SUDDEN increase in hair growth that she had noticed 11 months earlier. She had lost more than 30 kg during this same period. Physical examination revealed fine lanugo hair all over her face (Panel A) and body (Panel B) and a deeply furrowed tongue, which caused a burning sensation. A diagnosis of acquired hypertrichosis lanuginosa was made. The results of laboratory investigations, including measurements of hormonal factors, were normal except for an increased serum level of carcinoembryonic antigen. Advanced rectal adenocarcinoma was found, without metastasis. The patient underwent radiotherapy (a total of 45 Gy). The rectal mass regressed slightly, but there was no evidence of concomitant regression of mucocutaneous signs. The woman was depressed about her condition and decided to shave. She underwent a curative resection of her rectal tumor and postoperative adjuvant chemotherapy.

Acquired hypertrichosis lanuginosa is a rare disorder, which consists of abnormal and excessive growth of fine lanugo hair. Stomatologic symptoms are frequently associated with the disorder. The disorder is usually linked to an internal malignant condition, especially colorectal cancer, and it may regress with removal of the tumor.

Copyright © 2006 Massachusetts Medical Society.

WEB-ONLY IMAGES IN CLINICAL MEDICINE

Click on "Featured Images" at www.nejm.org to see the *Journal's* Web-only Images in Clinical Medicine. The Images are listed (with e page numbers) in the table of contents of the printed *Journal* the week they are published and are compiled on the *Journal's* Web site.