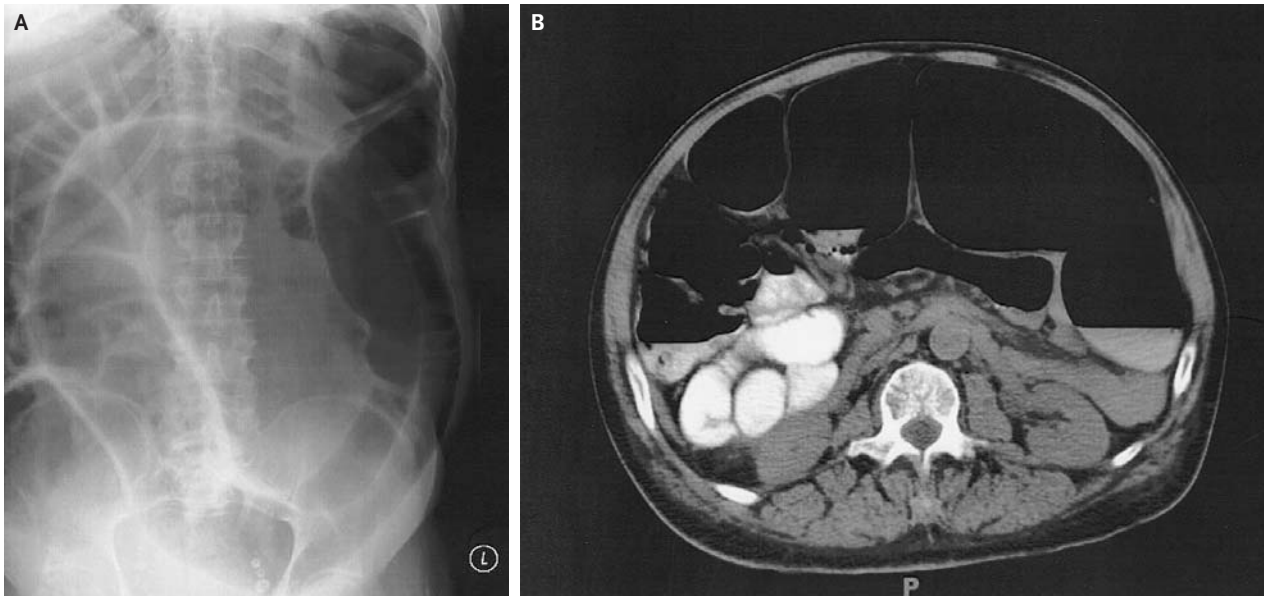


IMAGES IN CLINICAL MEDICINE

Colonic Ileus



Senator Hazelwood, M.D.
Mt. Sinai School of Medicine
Jersey City, NJ 07302

Denise Burton, Ph.D.
Department of Veterans Affairs
Washington, DC 20420

A 77-YEAR-OLD MAN WITH A HISTORY OF HYPERTENSION, DIABETES MELLITUS, and seizure disorder presented to the emergency room with abdominal pain and distention of approximately two to three days' duration. The patient reported no nausea, vomiting, or diarrhea. On physical examination, he had diffuse abdominal distention without guarding or rebound tenderness. Laboratory studies were unremarkable except for hypokalemia (serum potassium level, 2.6 mmol per liter). Abdominal radiography (Panel A) and computed tomography (CT) (Panel B) demonstrated marked colonic dilatation. Mechanical obstruction was excluded by the presence of air in the rectosigmoid, as shown on the CT scan, and a diagnosis of colonic pseudo-obstruction was made. Treatment was initiated with the insertion of a rectal tube and correction of the hypokalemia. The patient's abdominal pain and distention rapidly resolved.

Copyright © 2006 Massachusetts Medical Society.