

ORIGINAL ARTICLE

Evaluation of Patients Treated with Natalizumab for Progressive Multifocal Leukoencephalopathy

Tarek A. Yousry, Dr.Med.Habil., Eugene O. Major, Ph.D., Caroline Ryschkewitsch, B.S., Gary Fahle, B.S., Steven Fischer, M.D., Ph.D., Jean Hou, B.S., Blanche Curfman, B.S., Katherine Miszkiel, M.D., Nicole Mueller-Lenke, M.D., Esther Sanchez, M.D., Frederik Barkhof, M.D., Ph.D., Ernst-Wilhelm Radue, M.D., Hans R. Jäger, M.D., and David B. Clifford, M.D.

ABSTRACT

BACKGROUND

From the Institute of Neurology, Queen Square, London (T.A.Y., K.M., H.R.J.); the Laboratory of Molecular Medicine and Neuroscience, National Institute of Neurological Disorders and Stroke, National Institutes of Health (NIH), Bethesda, Md. (E.O.M., C.R., J.H., B.C.); the Department of Laboratory Medicine, NIH Clinical Center, Bethesda, Md. (G.F., S.F.); the Department of Neuroradiology, University of Basel, Basel, Switzerland (N.M.-L., E.-W.R.); the Department of Radiology, Vrije Universiteit Medical Centre, Amsterdam (E.S., F.B.); and the Departments of Neurology and Medicine, School of Medicine, Washington University, St. Louis (D.B.C.). Address reprint requests to Dr. Major at the Laboratory of Molecular Medicine and Neuroscience, National Institute of Neurological Disorders and Stroke, NIH, 10 Center Dr., Bldg. 10, Rm. 3B14, Bethesda, MD 20892-1296, or at majorg@ninds.nih.gov.

Drs. Yousry, Major, and Clifford contributed equally to this article.

N Engl J Med 2006;354:924-33.
Copyright © 2006 Massachusetts Medical Society.

Progressive multifocal leukoencephalopathy (PML) was reported to have developed in three patients treated with natalizumab. We conducted an evaluation to determine whether PML had developed in any other treated patients.

METHODS

We invited patients who had participated in clinical trials in which they received recent or long-term treatment with natalizumab for multiple sclerosis, Crohn's disease, or rheumatoid arthritis to participate. The clinical history, physical examination, brain magnetic resonance imaging (MRI), and testing of cerebrospinal fluid for JC virus DNA were used by an expert panel to evaluate patients for PML. We estimated the risk of PML in patients who completed at least a clinical examination for PML or had an MRI.

RESULTS

Of 3417 patients who had recently received natalizumab while participating in clinical trials, 3116 (91 percent) who were exposed to a mean of 17.9 monthly doses underwent evaluation for PML. Of these, 44 patients were referred to the expert panel because of clinical findings of possible PML, abnormalities on MRI, or a high plasma viral load of JC virus. No patient had detectable JC virus DNA in the cerebrospinal fluid. PML was ruled out in 43 of the 44 patients, but it could not be ruled out in one patient who had multiple sclerosis and progression of neurologic disease because data on cerebrospinal fluid testing and follow-up MRI were not available. Only the three previously reported cases of PML were confirmed (1.0 per 1000 treated patients; 95 percent confidence interval, 0.2 to 2.8 per 1000).

CONCLUSIONS

A detailed review of possible cases of PML in patients exposed to natalizumab found no new cases and suggested a risk of PML of roughly 1 in 1000 patients treated with natalizumab for a mean of 17.9 months. The risk associated with longer treatment is not known.

PROGRESSIVE MULTIFOCAL LEUKOENCEPHALOPATHY (PML) is a demyelinating disease of the central nervous system that is encountered most frequently in the setting of immunodeficiency.¹ The disease is caused by the human polyomavirus JC virus, a common and widespread infection in humans. PML was reported in three patients who received natalizumab (Tysabri, Biogen Idec and Elan Pharmaceuticals).²⁻⁴ Natalizumab is a recombinant humanized antibody directed to the α_4 integrins, both $\alpha_4\beta_1$ and $\alpha_4\beta_7$.⁵ The drug was approved by the Food and Drug Administration (FDA) for the treatment of relapsing forms of multiple sclerosis in November 2004 and is being investigated for the treatment of Crohn's disease and rheumatoid arthritis. Because of the occurrence of PML, the use of natalizumab was suspended on February 28, 2005.⁶ We report the evaluation of patients exposed to natalizumab for the occurrence of PML.

METHODS

INDEPENDENT ADJUDICATION COMMITTEE

An independent adjudication committee (IAC) was established with a formal charter approved by the members of the committee. The committee included a neurovirologist with experience with JC virus and PML (who served as the chair of the committee), a neuroradiologist, and a clinical neurologist (see Appendix). The committee agreed to evaluate all suspected cases of PML in patients who had been exposed to natalizumab to determine whether a diagnosis of PML was confirmed, indeterminate, or ruled out. The committee established criteria for the neuroradiologic evidence and laboratory assays used in the diagnosis of PML. Biogen Idec and Elan Pharmaceuticals assisted in the collection of the data. Physicians who were representatives of each of these companies were nonvoting participants in the discussion of the materials reviewed but were excluded from closed sessions of the IAC.

PATIENTS

A total of 3826 patients who had participated in recent clinical trials of natalizumab were recruited for the evaluation (Fig. 1). Eligible patients included those with multiple sclerosis who were participating in the Natalizumab Safety and Efficacy in Relapsing Remitting Multiple Sclerosis⁷ (AFFIRM) study (NCT00027300), the Safety and

Efficacy of Natalizumab in Combination with Interferon Beta-1a in Patients with Relapsing Remitting Multiple Sclerosis (SENTINEL) trial (NCT00030966),⁸ and the Natalizumab in Combination with Glatiramer Acetate in Patients with Relapsing-Remitting Multiple Sclerosis study (NCT00097760); patients with Crohn's disease who were participating in the international Efficacy of Natalizumab as Crohn's Therapy trial (ENACT-1, NCT00032799), the Evaluation of Natalizumab as Continuous Therapy (ENACT-2, NCT00032786), and the Clinical Trial of Natalizumab in Individuals with Moderately to Severely Active Crohn's Disease (ENCORE) (NCT00078611); patients with rheumatoid arthritis participating in a phase 2 Natalizumab in the Treatment of Rheumatoid Arthritis in Subjects Receiving Methotrexate trial (NCT00083759); and all patients participating in open-label safety-extension trials (NCT002761721). Of the 3826 patients recruited, 409 had received placebo but were recruited because blinding had not yet been broken; therefore, 3417 patients who had received natalizumab in these trials were included in our study. Because PML is known to be a progressive and often fatal neurologic disease, it was believed that recruiting patients with remote exposure to natalizumab was not required. All previous studies included three to six months of observation after exposure to the drug, and adverse events were reported. The 1708 subjects who had been enrolled in nine trials involving patients with multiple sclerosis that ended before 2001 and in seven trials involving patients with Crohn's disease that ended before 2003 were not actively recruited for this safety evaluation, but we performed a review of the integrated natalizumab safety database, including serious adverse events reported in these studies.

Approximately 7000 patients received one to three doses of natalizumab between November 2004 and February 2005, after the drug became commercially available. Prescribing physicians of commercially treated patients were notified by a "Dear Healthcare Professional" letter (the letter is in the Supplementary Appendix, available with the full text of this article at www.nejm.org) that recommended evaluating and reporting adverse events, and referred cases were eligible for evaluation by the IAC. Two patients treated commercially after FDA approval of natalizumab and one pediatric patient receiving the drug for compassionate use were referred for evaluation.

EVALUATION FOR PML

Treating physicians were asked to submit a structured evaluation, including a detailed history, a physical evaluation, and a neurologic evaluation performed by a neurologist for all patients who had participated in the named studies, to arrange for brain magnetic resonance imaging (MRI), and to obtain samples of cerebrospinal fluid, when possible, for all patients. This information was reviewed locally, and patients for whom there were any findings potentially consistent with PML on clinical examination or MRI were referred to the IAC for evaluation. All MRIs were forwarded to one of three reading centers (in London and Basel, Switzerland, for scans of patients with multiple sclerosis and in Amsterdam for patients with Crohn's disease or rheumatoid arthritis) for secondary review. If a reading center found suspicious lesions, cases were forwarded for evaluation to the IAC. Samples of cerebrospinal fluid were sent to laboratories of the National Institutes of Health (NIH) for evaluation.

Diagnostic Criteria

The IAC determined that patients whose evaluation fulfilled all three of the following criteria would receive a diagnosis of confirmed PML: progressive clinical disease, MRI findings typical of PML, and detectable JC virus DNA in the cerebrospinal fluid. Cerebrospinal fluid testing (if not already available) and repeated MRI studies were requested for all patients for whom findings on the neurologic examination were consistent with PML. If follow-up examinations could not be obtained, the IAC considered the diagnosis as indeterminate for PML. The absence of progressive neurologic disease coupled with either lesions on MRI that were not typical of PML or undetectable JC virus DNA in the cerebrospinal fluid was considered sufficient evidence to rule out PML.

Clinical and Imaging Investigation and Criteria

Patients were assessed clinically, including for cognitive, motor, and visual symptoms or signs, and neurologic deterioration was considered potentially consistent with a diagnosis of PML. The MRI protocol consisted of axial T₂-weighted sequences and plain and enhanced T₁-weighted sequences. Previous MRI studies, for comparison, were generally available for patients with multiple sclerosis but were rarely available for those with Crohn's disease or rheumatoid arthritis. For follow-up examinations, an additional fluid-attenuated inversion recovery sequence was requested.

Figure 1 (facing page). Evaluation of Patients for Progressive Multifocal Leukoencephalopathy (PML) by the Independent Adjudication Committee (IAC).

The asterisk indicates official counts of patients as of the locking of the interim database (on August 4, 2005, for patients with multiple sclerosis [MS], and on August 24, 2005, for patients with Crohn's disease [CDJ] or rheumatoid arthritis [RA]). CSF denotes cerebrospinal fluid, NIH National Institutes of Health, MRI magnetic resonance imaging, and JCV JC virus.

An ad hoc committee (see Appendix) consisting of five neuroradiologists with experience in the imaging of white-matter diseases, supported by a neurologist with expertise in demyelinating diseases, developed guidelines for the detection by MRI of PML in the presence of multiple sclerosis lesions (Table 1). The guidelines were designed to assist in the diagnosis of PML, although no feature is pathognomonic.

Laboratory Investigation

Samples of cerebrospinal fluid were independently and concurrently tested for JC virus DNA at two NIH laboratories with use of assays validated by certification by the Clinical Laboratory Improvement Amendment program, in the Laboratory of Molecular Medicine and Neuroscience (LMMN) at the National Institute of Neurological Disorders and Stroke and in the Division of Laboratory Medicine (DLM). The assay performed at the DLM was approximately one order of magnitude less sensitive than that performed at the LMMN because of different methods of DNA template extraction.^{9,10} The LMMN performed nucleic-acid extraction with the use of the QIAamp viral RNA mini-kit (Qiagen), according to the manufacturer's instructions. A starting volume of 200 μ l of the sample was extracted and eluted to 50 μ l. All samples were assayed in duplicate with the use of 10 μ l of DNA template by polymerase chain reaction (PCR) (TaqMan PCR chemistry, Applied Biosystems) and the ABI 7500 sequence-detection system (Applied Biosystems). The locations of the primer and probe, the cycling conditions, and the standard curve design have been described previously.⁹ The DLM used the MagNa Pure Instrument (Roche) for sample extraction, with a starting volume of 1 ml eluted to 50 μ l. A volume of 10 μ l of template was used for each reaction, and each sample was run once. The DLM performed quantitative PCR (Rotor-Gene, Corbett Research).

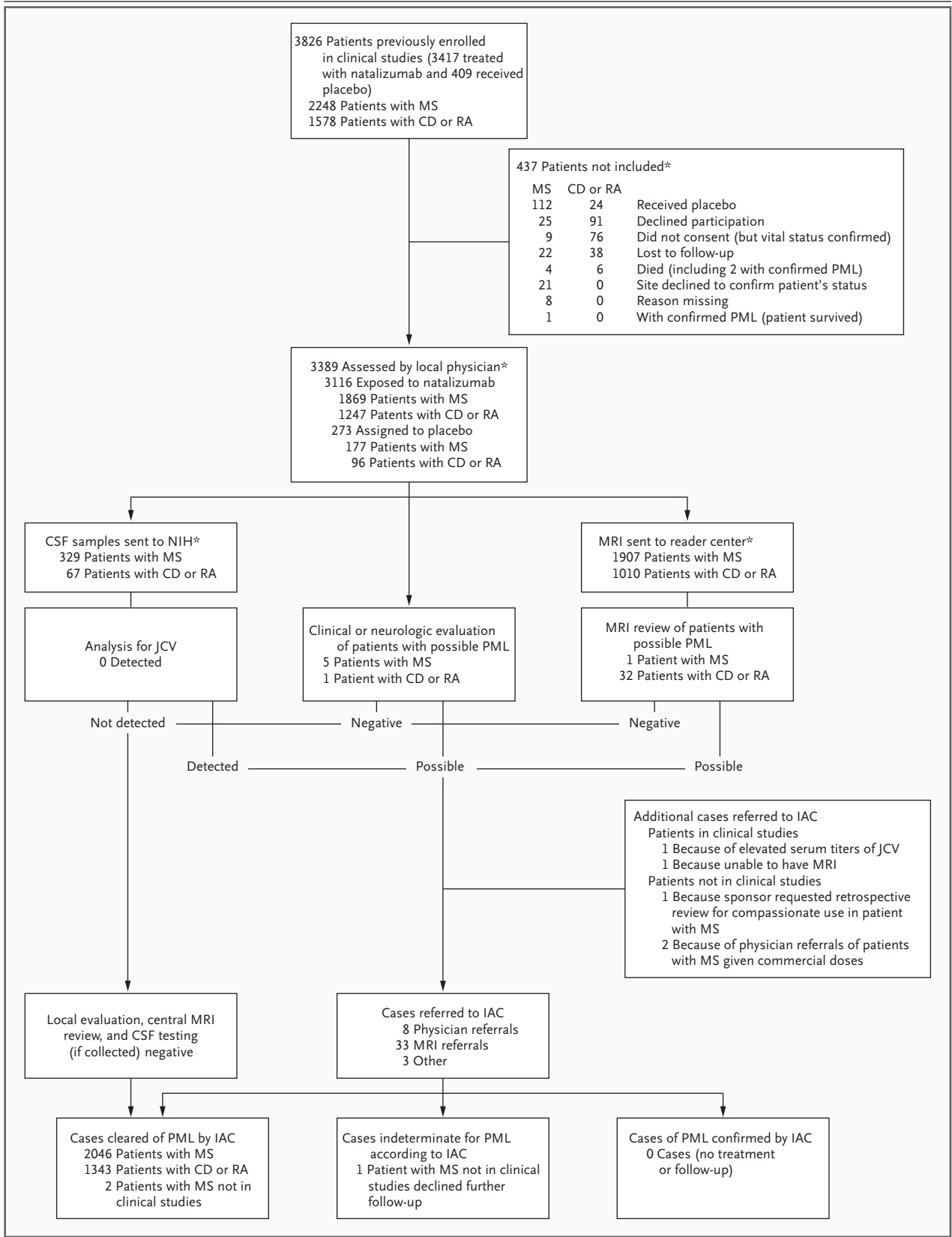


Table 1. Features Visualized on Magnetic Resonance Imaging to Be Considered in the Differential Diagnosis of Multiple Sclerosis and Progressive Multifocal Leukoencephalopathy.*

Feature	Multiple Sclerosis	Progressive Multifocal Leukoencephalopathy
Location of new lesions	Mostly focal; may affect entire brain and spinal cord, in white and possibly gray matter; posterior cranial fossa lesions are rarely seen	Diffuse lesions, mainly subcortical and rarely periventricular, located almost exclusively in white matter, although occasional extension to gray matter has been seen; posterior fossa frequently involved (cerebellum)
Borders	Sharp edges; mostly round or finger-like in shape (especially periventricular lesions), confluent with other lesions; U-fibers may be involved	Ill-defined edges; infiltrating; irregular in shape; confined to white matter, sparing gray matter; pushing against the cerebral cortex; U-fibers destroyed
Mode of extension	Initially focal, lesions enlarge within days or weeks and later decrease in size within months	Lesions are diffuse and asymmetric, extending homogeneously; no confluence with other lesions; confined to white-matter tracks, sparing the cortex; continuous progression
Mass effect	Acute lesions show some mass effect	No mass effect even in large lesions (but lesion slightly abuts cerebral cortex)
On T ₂ -weighted sequence	Acute lesions: hyperintense center, isointense ring, discrete hyperintensity outside the ring structure Subacute and chronic lesions: hyperintense, with no ring structure	Diffuse hyperintensity, slightly increased intensity of newly involved areas compared with old areas, little irregular signal intensity of lesions
On T ₁ -weighted sequence	Acute lesions: densely hypointense (large lesions) or isointense (small lesions); increasing signal intensity over time in 80 percent; decreasing signal intensity (axonal loss) in about 20 percent	Slightly hypointense at onset, with signal intensity decreasing over time and along the affected area; no reversion of signal intensity
On FLAIR sequence	Hyperintense, sharply delineated	Hyperintensity more obvious, true extension of abnormality more clearly visible than in T ₂ -weighted images
With enhancement	Acute lesions: dense homogeneous enhancement, sharp edges Subacute lesions: ring enhancement Chronic lesions: no enhancement	Usually no enhancement even in large lesions; in patients with HIV, some peripheral enhancement is possible, especially under therapy
Atrophy	Focal atrophy possible, due to focal white-matter degeneration; no progression	No focal atrophy

* FLAIR denotes fluid-attenuated inversion recovery, and HIV human immunodeficiency virus.

STATISTICAL ANALYSIS

We based our estimate of the risk of PML on the three confirmed cases originally identified and on the 3116 patients in the clinical trials who had been exposed to natalizumab and were clinically evaluated for PML with the use of, at least, a history and a physical examination or MRI designed to rule out PML. The three patients with PML previously reported had received 8, 29, and 37 monthly infusions of natalizumab and had participated in the clinical trials included in our evaluation. The 95 percent confidence interval was calculated with the use of the method for a binomial proportion.

RESULTS

Of the 3826 patients who had participated in the named clinical trials and were recruited for enroll-

ment in this study, 3389 (89 percent) agreed to participate. Of these 3826 patients, 3417 had received natalizumab, and of these patients, the history and either physical examination or MRI were available for 3116 (91 percent). Some patients who had received placebo were recruited, because at the time when this safety evaluation was initiated, the blinding was still maintained in some ongoing trials and because controls were needed for cerebrospinal fluid testing. Of the 3389 patients assessed for PML, MRI scans were available for 2917, and results of cerebrospinal fluid testing were available for 396; 437 patients were excluded (Fig. 1).

The majority (2700) of the patients included in the evaluation had received the last dose of natalizumab on or after December 1, 2004. Of the patients with multiple sclerosis, 97 percent had undergone MRI or a neurologic examination within three months after the last dose. Patients who

had participated in the clinical trials involving people with Crohn's disease or rheumatoid arthritis were evaluated later, with 27 percent evaluated within three months after the last dose and 91 percent evaluated within six months after the last dose. Patients with multiple sclerosis treated with natalizumab had received a mean of 21.4 infusions and a median of 30 (range, 1 to 41), whereas those with Crohn's disease or rheumatoid arthritis had received a mean of 12.6 monthly infusions and a median of 7 (range, 1 to 39). The mean exposure to natalizumab among all patients included in the evaluation was 17.9 monthly infusions, with a median of 17 (range, 1 to 41). Forty-four patients were referred to the IAC for evaluation (Table 2), and the three cases of PML previously reported were also evaluated by the IAC.

Table 2 lists the cases and evidence available for evaluation by the IAC. For each case, the IAC reviewed the patient's clinical history, the local neurologist's examination report, the findings on MRI, the results of cerebrospinal fluid testing, and the PCR assay for JC virus DNA. If the IAC did not unanimously find that the evidence was sufficient to rule out PML, then it recommended repeating the MRI and collecting a sample of cerebrospinal fluid, if none was available. Four patients (Cases 1, 2, 3, and 4) had normal clinical examinations, and three (Cases 5, 6, and 7) had examinations that showed stable, known abnormalities; for these seven patients, MRI scans inconsistent with a diagnosis of PML and negative results of cerebrospinal fluid testing for JC virus DNA were reported. For 16 patients (Cases 8 through 23) whose baseline evaluations suggested active neurologic disease, MRI was repeated at a minimum recommended interval between scanning procedures to detect changes consistent with PML on MRI. Eight of these 16 patients also had no detectable JC virus DNA in the cerebrospinal fluid. For 19 other patients (Cases 24 through 42), the history and MRI were not consistent with PML, and a diagnosis of PML was ruled out without cerebrospinal fluid testing for JC virus DNA. One case (Case 43) was referred to the IAC for evaluation because MRI was precluded because of the patient's size. However, the neurologic examination and cerebrospinal fluid testing for this patient with Crohn's disease did not indicate a neurologic disease, and PML was ruled out in the absence of MRI. One patient (Case 44) with a history of progressive multiple sclerosis preceding the use of natalizumab was evaluated on the basis of only

a single MRI scan. Recommended repeated MRI and cerebrospinal fluid testing were not performed; the IAC therefore classified this case as indeterminate.

Samples of plasma or serum were collected for exploratory analysis only and not as part of the risk analysis or for use in the diagnosis of PML. However, in one patient (Case 28 in Table 2) in whom the plasma viral load was high (8733 copies per milliliter), a finding of JC virus DNA was reported by the LMMN and the case was reviewed by the IAC at the sponsor's request. Neurologic examination revealed chronic cognitive changes, and the MRI was consistent with old ischemic disease in this 49-year-old man with Crohn's disease and ankylosing spondylitis, who had undergone several bowel-resection procedures. The committee ruled out PML in this case.

The IAC reviewed the records of serious adverse events and deaths that had occurred during the period of the natalizumab trials and within the three to six months after participating patients had received the last dose of natalizumab. Details with respect to adverse events have been published previously¹¹ or are reported elsewhere in this issue of the *Journal*.^{7,8} Other than the two previously reported deaths,^{4,12} no deaths were suspicious for association with PML.

The IAC ruled out PML in 43 of the 44 cases referred to the committee, and 1 case was classified as indeterminate because follow-up examinations could not be obtained. The three previously reported cases of PML (two in patients with multiple sclerosis who had participated in the SENTINEL study [NCT00030966] and one in a patient with Crohn's disease who had participated in both the ENACT-1 and ENACT-2 trials [NCT00032799 and NCT00032786, respectively]) were initially reviewed by the committee. All three cases fulfilled the diagnostic criteria for PML established by the committee and have been described by investigators at their local sites.²⁻⁴

ESTIMATE OF RISK OF PML

Of 3116 patients who had participated in the named clinical trials for whom histories and neurologic examinations or MRIs were available for evaluation and who were included in the safety analysis, no new cases were identified. Only the three previously identified cases of PML were confirmed and were included in the estimate of the risk of PML. We estimated that the incidence of PML associated with exposure to natalizumab is

Table 2. Cases Referred to the Independent Adjudication Committee (IAC) for Evaluation for Progressive Multifocal Leukoencephalopathy (PML).*

Case No.	Diagnosis	Source of Referral	Findings on Neurologic Examination	Findings on MRI	Findings on Follow-up MRI	Results of CSF Testing for JCV DNA	Determination by IAC
Index cases							
IAC-991	MS	Physician	Deteriorating	Possible PML	Progressive	Detected	PML confirmed
IAC-992	MS	Physician	Deteriorating	Possible PML	Progressive	Detected	PML confirmed
IAC-993	CD	Retrospective review of serious adverse events	Deteriorating	Possible PML	Progressive	No sample available	PML confirmed
Cases evaluated by the IAC							
1	CD	Central reader	Normal	Not PML	Not detected	Not detected	PML ruled out
2	CD	Local reader	Normal	Not PML	Not detected	Not detected	PML ruled out
3	CD	Central reader	Normal	Not PML	Not detected	Not detected	PML ruled out
4	CD	Central reader	Normal	Not PML	Not detected	Not detected	PML ruled out
5	MS	Physician	Stable	Not PML	Not detected	Not detected	PML ruled out
6	CD	Central reader	Stable	Not PML	Not detected	Not detected	PML ruled out
7	CD	Central reader	Stable	Not PML	Not detected	Not detected	PML ruled out
8	MS	Physician	Progressive (MS)	Possible PML	Not PML	Not detected†	PML ruled out
9	MS	Physician	Progressive (MS)	Not PML	Not PML	Not detected	PML ruled out
10	MS	Central reader	Progressive (MS)	Possible PML	Not PML	Not detected	PML ruled out
11	RA	Central reader	Mild vestibular dysfunction	Possible PML	Not PML	Not detected	PML ruled out
12	CD	Central reader	Normal	Possible PML	Not PML	Not detected	PML ruled out
13	CD	Local and central readers	Normal	Possible PML	Not PML	Not detected	PML ruled out
14	CD	Central reader	Normal	Possible PML	Not PML	Not detected	PML ruled out
15	CD	Central reader	Mild cognitive changes	Possible PML	Not PML	Not detected	PML ruled out
16	Pediatric MS	Sponsor	Progressive (MS)	Not PML	Not PML	No sample available	PML ruled out
17	MS	Physician	Progressive (MS)	Not PML	Not PML	No sample available	PML ruled out
18	MS	Physician	Progressive (MS)	Not PML	Not PML	No sample available	PML ruled out
19	CD	Central reader	Normal	Possible PML	Not PML	No sample available	PML ruled out
20	CD	Central reader	Normal	Possible PML	Not PML	No sample available	PML ruled out
21	CD	Central reader	Normal	Possible PML	Not PML	No sample available	PML ruled out
22	CD	Central reader	Normal	Possible PML	Not PML	No sample available	PML ruled out
23	CD	Central reader	Normal	Not PML	Not PML	No sample available	PML ruled out

24 [‡]	MS	Physician	Stable	Not PML	No sample available	PML ruled out
25	CD	Central reader	Stable	Not PML	No sample available	PML ruled out
26	CD	Central reader	Normal	Not PML	No sample available	PML ruled out
27	CD	Central reader	Remote optic neuritis	Not PML	No sample available	PML ruled out
28	CD	Sponsor (because of high serum titers of JCV)	Stable	Not PML	No sample available	PML ruled out
29	RA	Central reader	Reflex asymmetry	Not PML	No sample available	PML ruled out
30	CD	Central reader	Normal	Not PML	No sample available	PML ruled out
31	CD	Central reader	Normal	Not PML	No sample available	PML ruled out
32	CD	Central reader	Normal	Not PML	No sample available	PML ruled out
33	CD	Central reader	Normal	Not PML	No sample available	PML ruled out
34 [‡]	CD	Central reader	Normal	Not PML	No sample available	PML ruled out
35	CD	Central reader	Normal	Not PML	No sample available	PML ruled out
36	CD	Central reader	Normal	Not PML	No sample available	PML ruled out
37	RA	Central reader	Normal	Not PML	No sample available	PML ruled out
38	CD	Central reader	Normal	Not PML	No sample available	PML ruled out
39	CD	Central reader	Normal	Not PML	No sample available	PML ruled out
40	CD	Central reader	Normal	Not PML	No sample available	PML ruled out
41	CD	Central reader	Normal	Not PML	No sample available	PML ruled out
42	CD	Central reader	Normal	Not PML	No sample available	PML ruled out
43	CD	MRI precluded [§]	Normal	NA	Not detected	PML ruled out
44	MS	Physician	Progressive lesions documented over 5 yr (antedating receipt of natalizumab)	Possible PML	No sample available	Indeterminate

* MRI denotes magnetic resonance imaging, CSF cerebrospinal fluid, JCV JC virus, MS multiple sclerosis, CD Crohn's disease, RA rheumatoid arthritis, and NA not available.

[†] Results of repeated testing of CSF were negative for PML.

[‡] The patient received placebo.

[§] MRI was precluded because of the size of the patient.

1.0 case per 1000 patients (95 percent confidence interval, 0.2 to 2.8 per 1000) in this population who received a mean of 17.9 monthly doses of natalizumab.

DISCUSSION

After the evaluation of more than 3000 patients who were treated with natalizumab, no new cases of PML were identified. The evaluation was rigorous and careful, but several limitations of this study need to be acknowledged. The assessment of these patients was complicated by the presence of underlying neurologic dysfunction in those who had multiple sclerosis, including lesions on MRI, and by the occurrence of incidental lesions on MRI in those who had rheumatoid arthritis or Crohn's disease.¹³

The criteria of the IAC for a diagnosis of PML required evidence of active neurologic disability. The possibility that PML might have different clinical behavior in the setting of natalizumab was recognized. The possibility of nonprogressive disease cannot be totally ruled out. However, because the known cases in which treatment with natalizumab was associated with PML were of aggressive disease, the hypothesis that PML in this setting might be clinically and neuroradiologically silent is not suggested by current evidence. It was also recognized that PML might develop in a clinically silent area of the brain.

We used MRI as the most sensitive tool for screening for PML,¹⁴ because it has the potential of detecting lesions at an early stage, possibly before they are clinically detectable. Prospective criteria, along with scans obtained before the initiation of treatment which could be used for comparison, resulted in only one referral to the IAC based on MRI from among the population with multiple sclerosis. Incidentally discovered underlying abnormalities in patients with Crohn's disease or rheumatoid arthritis resulted in more MRI-based referrals to the committee, but the application of MRI criteria combined with clinical evidence and the results of cerebrospinal fluid testing made for a small number of referrals of patients from this population. On repeated scanning in suspected cases, no patients with worsening lesions on MRI were found.

Cerebrospinal fluid evidence alone is not sufficient to rule out PML, since it is recognized that JC virus DNA testing, although almost 100 percent

specific, is not perfectly sensitive for the pathological diagnosis of PML.¹⁵ The absence of detectable JC virus in the cerebrospinal fluid of 396 patients is reassuring with respect to the possibility that smoldering or subclinical PML might be present, since the sensitivity of cerebrospinal fluid detection for PML usually exceeds 90 percent.

One of the limitations of this study results from the collection of data only after the discontinuation of natalizumab. Therapy with the drug was immediately stopped pending safety evaluation. In the setting of the human immunodeficiency virus, the reversal of immunodeficiency effected by potent antiretroviral therapy has been shown in some cases to stop the clinical progression of PML¹³ and progression on MRI.¹⁶ Improved immunodeficiency may result in a decline in JC virus DNA in the cerebrospinal fluid.¹⁵ Although the organization of the safety evaluation took several weeks, 97 percent of the patients who had multiple sclerosis and were involved in our study were evaluated within three months after the drug was discontinued. Because natalizumab was thought to be active during this interval, the delay of the evaluation appears unlikely to have greatly diminished the validity of the evaluation. The evaluation was slightly more delayed for patients with Crohn's disease or rheumatoid arthritis, but 91 percent of the evaluations for these patients were accomplished within six months after receipt of the final dose of natalizumab.

The safety analysis performed by the IAC was not designed as a prospective epidemiologic study. We chose to estimate the risk of PML in this setting on the basis of a calculation with the use of the number of cases of PML according to the number of patients exposed to natalizumab who were prospectively examined. We do not know the duration of exposure to natalizumab required to put patients at risk for PML. Patients reported as having a diagnosis of PML had received 8 to 37 monthly infusions, whereas the median exposure in the examined population was 30 infusions among patients with multiple sclerosis and 7 among those with Crohn's disease or rheumatoid arthritis. It is estimated that there have been approximately 5200 patient-years of exposure to natalizumab to date. Our evaluation recruited patients directly from the clinical trials but encouraged referrals from physicians who treated the estimated 7000 commercially treated patients. In our risk analysis, the commercially treated patients

and those treated in trials that were not included in our evaluation were not included in the denominator. PML is generally a serious, disabling neurologic disease, and we believe that if cases of PML occurred in these other populations, these cases would probably have been detected. However, we think it is appropriate that our risk estimate was based only on patients who had participated in the clinical trials examined in this study, for three reasons: patients who were not included in this evaluation were not formally assessed for PML; we were not able to ascertain the duration of exposure of commercially treated patients; and most of the patients who had participated in the clinical trials and the commercially treated patients had only brief exposures to natalizumab. Our assessment of the neurologic examinations, MRI studies, and laboratory data for more than 3000 patients exposed to natalizumab confirmed the diagnosis of PML in three patients but did not identify any additional cases.

Supported by the National Institutes of Health (NIH), through the Division of Intramural Programs, for analyses performed at the Laboratory of Molecular Medicine and Neuroscience, the Institute for Neurological Disorders and Stroke, and the Division of Laboratory Medicine Clinical Center. Biogen Idec and Elan Pharmaceuticals provided support for the clinical procedures and magnetic resonance imaging performed and provided some reagents and supplies for laboratory testing.

Drs. Yousry and Clifford report having received reimbursement for time required to perform duties as members of the independent adjudication committee; Drs. Yousry, Miszkiel, and Jäger, reimbursement for activities related to the reading center; Drs. Sanchez and Barkhof, reimbursement for time related to this project; Dr. Radue, grant support from Biogen Idec, Novartis, and Sanofi; and Dr. Clifford, consulting fees from Biogen Idec, Boehringer Ingelheim, Pfizer, and Genzyme, speaker's fees from Bristol-Myers Squibb and Boehringer Ingelheim, and research support from Savient Pharmaceuticals, NeurogesX, Schering-Plough, Roche, Bavarian Nordic, and Pfizer. None of the authors hold a financial interest in Biogen Idec or Elan Pharmaceuticals. None of the authors at the NIH received reimbursement or compensation for this study. No other potential conflict of interest relevant to this article was reported.

We are indebted to the many local investigators and radiologists who provided the data required for this analysis; to the patients involved in the studies who underwent the procedures; and to the many staff members who coordinated the clinical activities and made the data available for review by the independent adjudication committee (IAC).

APPENDIX

The independent adjudication committee included the following members: E.O. Major, neurovirologist and committee chair (National Institutes of Health, Bethesda, Md.); T.A. Yousry, neuroradiologist (Institute of Neurology, Queen Square, London); and D.B. Clifford, clinical neurologist (School of Medicine, Washington University, St. Louis). The members of the ad hoc committee that developed guidelines for the detection on magnetic resonance imaging of progressive multifocal leukoencephalopathy in the presence of multiple sclerosis lesions were the following neuroradiologists — T.A. Yousry, H.R. Jäger (Institute of Neurology, Queen Square, London); E.-W. Radue, N. Mueller-Lenke (University of Basel, Basel, Switzerland), and M.A. van Buchem (Leiden University Medical Center, Leiden, the Netherlands). They were supported by neurologist D.H. Miller (Institute of Neurology, London).

REFERENCES

- Koralnik IJ. New insights into progressive multifocal leukoencephalopathy. *Curr Opin Neurol* 2004;17:365-70.
- Langer-Gould A, Atlas SW, Green AJ, Bollen AW, Pelletier D. Progressive multifocal leukoencephalopathy in a patient treated with natalizumab. *N Engl J Med* 2005;353:375-81.
- Kleinschmidt-DeMasters BK, Tyler KL. Progressive multifocal leukoencephalopathy complicating treatment with natalizumab and interferon beta-1a for multiple sclerosis. *N Engl J Med* 2005;353:369-74.
- Van Assche G, Van Ranst M, Sciort R, et al. Progressive multifocal leukoencephalopathy after natalizumab therapy for Crohn's disease. *N Engl J Med* 2005;353:362-8.
- Rice GP, Hartung HP, Calabresi PA. Anti-alpha4 integrin therapy for multiple sclerosis: mechanisms and rationale. *Neurology* 2005;64:1336-42.
- Adelman B, Sandrock A, Panzara MA. Natalizumab and progressive multifocal leukoencephalopathy. *N Engl J Med* 2005;353:432-3.
- Polman CH, O'Connor PW, Havrdova E, et al. A randomized, placebo-controlled trial of natalizumab for relapsing multiple sclerosis. *N Engl J Med* 2006;354:899-910.
- Rudick RA, Stuart WH, Calabresi PA, et al. Natalizumab plus interferon beta-1a for relapsing multiple sclerosis. *N Engl J Med* 2006;354:911-23.
- Ryschkewitsch CF, Jensen P, Hou J, Fahle G, Fischer S, Major EO. Comparison of PCR-southern hybridization and quantitative real-time PCR for the detection of JC and BK viral nucleotide sequences in urine and cerebrospinal fluid. *J Virol Methods* 2004;121:217-21.
- Major EO, Ryschkewitsch C, Fahle G, et al. The laboratory evaluation for JC virus DNA in cerebrospinal fluid and plasma from multiple sclerosis patients participating in the phase III clinical trials of natalizumab. *Mult Scler* 2005;11:Suppl 1:s181.
- Sandborn WJ, Colombel JF, Enns R, et al. Natalizumab induction and maintenance therapy for Crohn's disease. *N Engl J Med* 2005;353:1912-25.
- Kleinschmidt-DeMasters BK, Tyler KL. Progressive multifocal leukoencephalopathy, natalizumab, and multiple sclerosis. *N Engl J Med* 2005;353:1745.
- Geissler A, Andus T, Roth M, et al. Focal white-matter lesions in brain of patients with inflammatory bowel disease. *Lancet* 1995;345:897-8.
- Whiteman ML, Post MJ, Berger JR, Tate LG, Bell MD, Limonte LP. Progressive multifocal leukoencephalopathy in 47 HIV-seropositive patients: neuroimaging with clinical and pathologic correlation. *Radiology* 1993;187:233-40.
- Yiannoutsos CT, Major EO, Curfman B, et al. Relation of JC virus DNA in the cerebrospinal fluid to survival in acquired immunodeficiency syndrome patients with biopsy-proven progressive multifocal leukoencephalopathy. *Ann Neurol* 1999;45:816-21.
- Thurnher MM, Post MJ, Rieger A, Kleibl-Popov C, Loewe C, Schindler E. Initial and follow-up MR imaging findings in AIDS-related progressive multifocal leukoencephalopathy treated with highly active antiretroviral therapy. *AJNR Am J Neuroradiol* 2001;22:977-84.

Copyright © 2006 Massachusetts Medical Society.