



The Price of Sight — Ranibizumab, Bevacizumab, and the Treatment of Macular Degeneration

Robert Steinbrook, M.D.

Related articles, pp. 1419, 1432, 1474, and 1493

On June 30, 2006, the Food and Drug Administration (FDA) approved ranibizumab — which is manufactured by Genentech and marketed as Lucentis — for the treatment of neovascular age-

related macular degeneration. Ranibizumab is a fragment of a recombinant monoclonal antibody (see Figure 1) that binds to and inhibits all the biologically active forms of vascular endothelial growth factor A. Administered by injection into the vitreous cavity (see Figure 2), ranibizumab prevents vision loss and improves visual acuity, with few serious adverse effects (as indicated in the reports by Rosenfeld et al. and Brown et al. in this issue of the *Journal*, pages 1419–1431 and 1432–1444); it thus represents a substantial advance against a leading cause of blindness (discussed by de Jong in this issue of the *Jour-*

nal, pages 1474–1485). According to the prescribing information, it is recommended that ranibizumab be injected monthly, with treatment likely to be required indefinitely, although less frequent administration is being evaluated. Ranibizumab is also expensive. The wholesale acquisition cost of a vial containing a single dose of 0.5 mg (0.05 ml) is \$1,950.

In the United States, about 155,000 cases of age-related macular degeneration are diagnosed each year; typical patients are 65 years of age or older. Although the neovascular form of macular degeneration accounts for about 10% of cases, it is responsible for the

vast majority of the associated vision loss. Before the FDA approved ranibizumab, some ophthalmologists began using another monoclonal antibody, bevacizumab, that is closely related to ranibizumab to treat patients who have neovascular macular degeneration or other chorioretinal diseases mediated by vascular endothelial growth factor. Marketed as Avastin and also manufactured by Genentech, bevacizumab is a full-length antibody that is derived from the same mouse monoclonal antibody precursor as ranibizumab (see Figure 1), neutralizes vascular endothelial growth factor, and costs considerably less than ranibizumab when administered as an intraocular injection.^{1,2}

In February 2004, the FDA approved bevacizumab for the treatment of metastatic cancer of the colon or rectum. Although the typ-

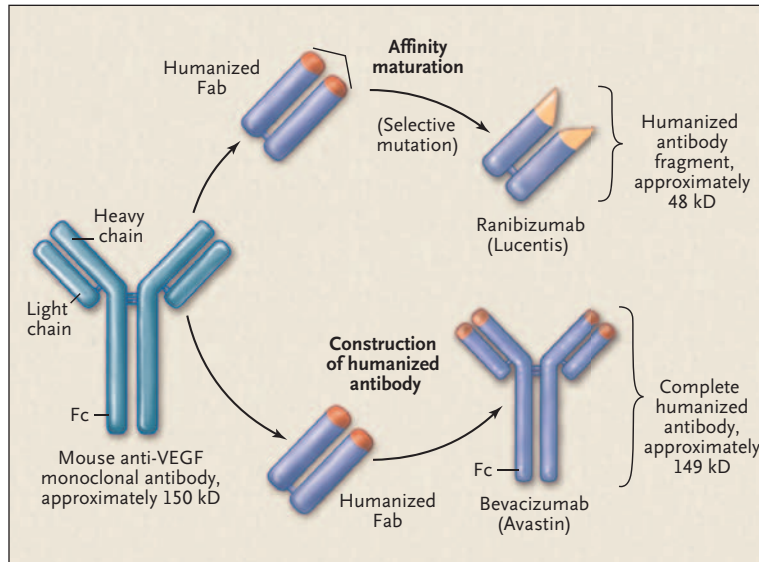


Figure 1. Relationship between Ranibizumab and Bevacizumab.

Ranibizumab is a recombinant humanized monoclonal IgG1 kappa-isotype antibody fragment (with a molecular weight of about 48 kD). It is produced in an *Escherichia coli* expression system (and thus is not glycosylated) and is designed for intraocular use. Bevacizumab is a recombinant humanized monoclonal IgG1 antibody (with a molecular weight of about 149 kD). It is produced in a Chinese-hamster-ovary mammalian-cell expression system (and thus is glycosylated) and is designed for intravenous infusion. Both the antibody fragment and the full-length antibody bind to and inhibit all the biologically active forms of vascular endothelial growth factor (VEGF) A and are derived from the same mouse monoclonal antibody. However, ranibizumab has been genetically engineered through a process of selective mutation to increase its affinity for binding and inhibiting the growth factor. The Fab domain of ranibizumab differs from the Fab domain of bevacizumab by six amino acids, five on the heavy chain (four of which are in the binding site) and one on the light chain. Not all the intermediate Fabs between the mouse monoclonal antibody and ranibizumab are shown.

ical price of bevacizumab as part of a chemotherapy regimen is \$4,400 a month, a 4-ml vial containing 100 mg has a wholesale acquisition cost of \$550. Thus, physicians and compounding pharmacies can prepare small aliquots in syringes for intraocular injection at a cost to the physician of \$17 to \$50, depending on the dose and the efficiency of the process.² In some instances, charges to patients may be considerably higher. On a molar basis, the typical dose — 1.25 mg (0.05 ml) — of bevacizumab is similar to the approved dose of ranibizumab.

Intraocular administration of bevacizumab is entirely off-label;

the drug is formulated for intravenous infusion, not intravitreal injection. Nonetheless, and though data from controlled trials are lacking, bevacizumab appears to be safe and effective in the short term.^{1,3} And ophthalmologists frequently use medications off-label.

As of mid-September 2006, ranibizumab had been approved in the United States and Switzerland (where it is marketed by Novartis, which has commercialization rights outside the United States). Bevacizumab has already brought Genentech billions of dollars in sales; ranibizumab will soon do so as well.

The good news for patients is

that there are two new medications for neovascular age-related macular degeneration, both of which appear to work better than the alternatives. But since they have never been directly compared, physicians can only speculate about which drug is superior with regard to safety, efficacy, and frequency of administration. The price difference is also too big to ignore.

Philip Rosenfeld of the University of Miami School of Medicine has studied both drugs and has pioneered the use of bevacizumab in the eye. (Rosenfeld has also has received consulting fees and grant support from Genentech and consulting fees, lecture fees, and grant support from other companies.) After bevacizumab became available, Rosenfeld and his colleagues administered it intravenously to 18 patients with neovascular age-related macular degeneration. Their preliminary findings suggested benefits that were similar to the initial findings with intravitreal ranibizumab. Improvement occurred in both eyes of patients with bilateral disease and lasted 6 months or longer in 12 of the patients.⁴ However, the treatment cost an average of \$2,200 per infusion, and the investigators and other retinal specialists were concerned about the potential for life-threatening adverse reactions, such as heart attack and stroke, which had previously been identified in patients with cancer.²

In an interview, Rosenfeld said that in May 2005 he was driving home and thinking about how bevacizumab could be delivered more safely into the eye. “The ‘eureka moment’ was when I suddenly realized that an appropriate molar amount of Avastin

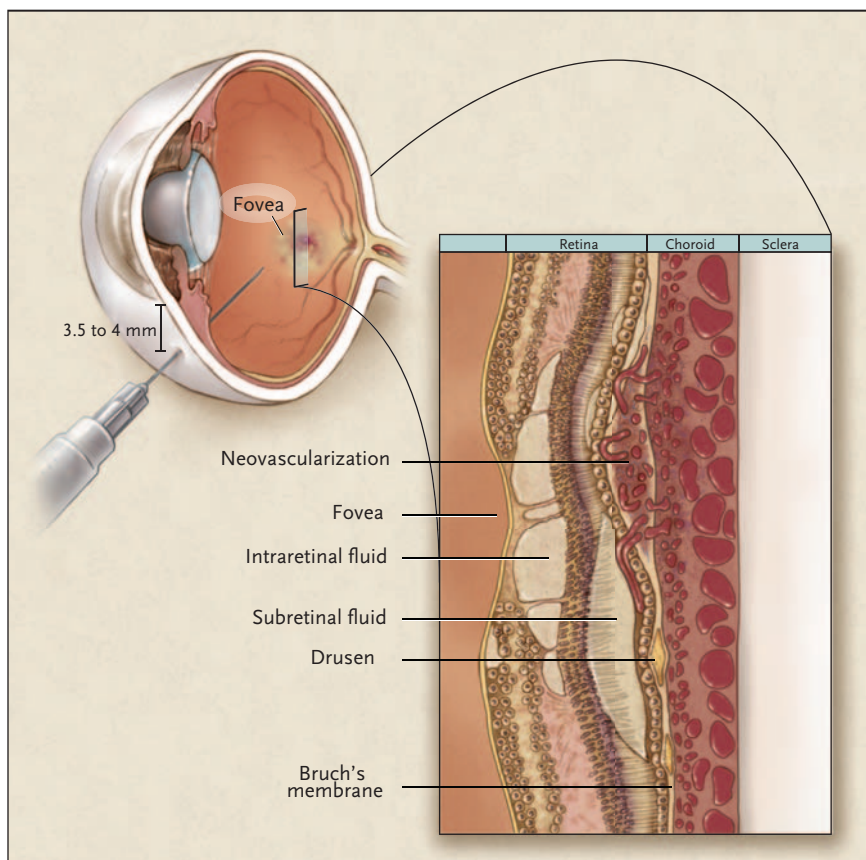


Figure 2. Intravitreal Injection for the Treatment of Neovascular Age-Related Macular Degeneration.

Under topical anesthesia and sterile conditions, ranibizumab or bevacizumab is typically injected with a 30-gauge \times 0.5-in. needle inserted 3.5 to 4 mm posterior to the limbus through the sclera into the vitreous cavity behind the lens of the eye. In general, patients can return to their usual activities within 24 hours. Usually, one eye is treated; depending on the situation, treatment in both eyes may be required, but it is generally given on separate days. The cross-section shows the retina and choroid as they would appear in a patient, with the neovascularization and accumulation of subretinal fluid that are characteristic of the disease. For the drugs to be effective, the vascular endothelial growth factor in and beneath the retina has to be inhibited. The fovea is the area at the center of the macula and is responsible for the best visual acuity.

could be injected into the eye, using the same low volume as Lucentis but at a small fraction of the cost.” The next day he spoke to a pharmacy director at the University of Miami about preparing the injections.

In July 2005, Rosenfeld’s group published two case reports showing benefit.¹ The first patient had neovascular age-related macular degeneration and was losing vision in her one good eye despite

having received all the therapies that were approved at the time. The second patient had central retinal vein occlusion and had exhausted other treatment options, according to Rosenfeld. Within 6 months, the intraocular use of bevacizumab had spread around the world. The Ophthalmic Mutual Insurance Company of San Francisco, which is affiliated with the American Academy of Ophthalmology, even provides risk-man-

agement recommendations for such use and an informed-consent form that physicians can modify to fit their practice.⁵ Most regional Medicare carriers cover intravitreal injections of bevacizumab, although there is no national policy.

In many parts of the world, a medication that costs \$1,950 for a monthly injection is unaffordable. In the United States, under Medicare, ranibizumab is covered through Part B; patients are responsible for a 20% copayment for each injection. In some instances, supplemental insurance, Medicaid, or support programs for the poor or uninsured that are funded by the manufacturer or others cover most or all of the patients’ costs. But regardless of who pays the bill, sales of ranibizumab generate revenue for Genentech, the drug’s high price contributes to the overall cost of health care, and the drug may sometimes still be unaffordable.

It is possible that bevacizumab would prove to be superior for neovascular age-related macular degeneration. For example, the molecule is about three times as large as ranibizumab and may remain in the eye longer, decreasing the frequency with which injections are required. At present, intraocular pharmacokinetic data are lacking. However, ranibizumab could also prove to be better. In addition to its smaller size, ranibizumab is genetically engineered to have greater affinity for vascular endothelial growth factor and is formulated for intraocular use; more of the drug may therefore penetrate all the layers of the retina. Moreover, ranibizumab that leaks out of the eye into the circulation has a half-life of hours; the half-life of a full-

length antibody such as bevacizumab is longer. For this reason, ranibizumab could theoretically be associated with less systemic toxicity than bevacizumab, but it is not known whether this is in fact the case. As an antibody fragment, ranibizumab lacks an Fc portion, so it may be less likely to induce inflammation within the eye. However, according to Rosenfeld, no apparent inflammation has been seen with bevacizumab, even with the highest dose that has been administered.³

Genentech specifically developed ranibizumab for the treatment of neovascular age-related macular degeneration. In an interview, Hal Barron, a senior vice-president and chief medical officer of Genentech, explained the company's position on the use of intraocular bevacizumab. "We have a huge database suggesting that Lucentis is very effective and very safe, so we are just not sure of the value of taking something that

is not formulated for the eye and subjecting patients to a randomized trial when there is, in our opinion, a very low likelihood of its being superior," he said. Nevertheless, Barron acknowledged, "If people have a hypothesis that it would be better or safer, one could certainly test that."

Since late 2005, the National Eye Institute has been considering a proposal for a prospective multicenter trial that would compare ranibizumab directly with bevacizumab. Although the institute has signed off on the need for a trial, as of mid-September it was still considering the research design and how to pay for the study, which would probably cost tens of millions of dollars. If the study is to go forward, the federal government will probably have to buy both drugs from Genentech. And the investigators will probably have to submit to the FDA an investigational new drug application for intravitreal bevacizumab.

Such a comparison might not ultimately affect the difference in price between the drugs, but it is certainly the only way to determine which drug is better for patients.

Dr. Steinbrook (rsteinbrook@attglobal.net) is a national correspondent for the *Journal*.

1. Rosenfeld PJ. Intravitreal Avastin: the low cost alternative to Lucentis? *Am J Ophthalmol* 2006;142:141-3.
2. *Idem*. Avastin in ophthalmology: a global phenomenon. *Current Insights*. Vol. 1. No. 2. Spring 2006. (San Francisco: American Academy of Ophthalmology.)
3. Bashshur ZF, Bazarbachi A, Schakal A, Haddad ZA, El Haibi CP, Noureddin BN. Intravitreal bevacizumab for the management of choroidal neovascularization in age-related macular degeneration. *Am J Ophthalmol* 2006;142:1-9.
4. Moshfeghi AA, Rosenfeld PJ, Puliafito CA, et al. Systemic bevacizumab (Avastin) therapy for neo-vascular age-related macular degeneration: twenty-four-week results of an uncontrolled open-label study. *Ophthalmology* (in press).
5. Ophthalmic Mutual Insurance Company. Risk management recommendations for off-label, intravitreal use of Avastin. August 2, 2006. (Accessed September 19, 2006, at http://www.omic.com/resources/risk_management/consent/Avastin%20080206.rtf.)

Tracing Atrial Fibrillation — 100 Years

W. Bruce Fye, M.D.

Today, there is talk about an epidemic of atrial fibrillation, and physicians caring for patients with this common arrhythmia face a bewildering array of treatment options. Contrast this situation with that of 1900, when no one understood the arrhythmia's mechanism or realized that it occurred in humans. One hundred years ago, in 1906, two publications — one from the Netherlands and the other from the United States — revealed that the

arrhythmia, then called "auricular fibrillation," did indeed affect humans, that it was in fact common in patients with heart disease, and that it could be identified by means of a new instrument, the electrocardiograph. These two articles marked a turning point in the history of atrial fibrillation. Their publication, along with subsequent reports and the development of electrocardiography, helped clinical investigators begin to solve a perplexing problem

that physicians soon came to recognize as a common one.^{1,2}

Around 1900, a few clinical investigators, notably James Mackenzie in Scotland and Karel Wenckebach in Holland, were studying cardiac arrhythmias with the use of arterial and venous pulse tracings. Pulse tracings reflect the consequences of cardiac contractions; they do not document the actual electrical impulses that stimulate the atria and ventricles to contract in the