

ORIGINAL ARTICLE

## Treatment of Coronary In-Stent Restenosis with a Paclitaxel-Coated Balloon Catheter

Bruno Scheller, M.D., Christoph Hehrlein, M.D., Wolfgang Bocksch, M.D.,  
Wolfgang Rutsch, M.D., Dariush Haghi, M.D., Ulrich Dietz, M.D.,  
Michael Böhm, M.D., and Ulrich Speck, Ph.D.

### ABSTRACT

#### BACKGROUND

Treatment of coronary in-stent restenosis is hampered by a high incidence of recurrent in-stent restenosis. We assessed the efficacy and safety of a paclitaxel-coated balloon in this setting.

#### METHODS

We enrolled 52 patients with in-stent restenosis in a randomized, double-blind, multicenter trial to compare the effects of a balloon catheter coated with paclitaxel (3  $\mu\text{g}$  per square millimeter of balloon surface area) with those of an uncoated balloon catheter in coronary angioplasty. The primary end point was late luminal loss as seen on angiography. Secondary end points included the rates of restenosis (a binary variable) and major adverse cardiac events.

#### RESULTS

Multivessel disease was present in 80% of patients in both groups. Quantitative coronary angiography revealed no significant differences in baseline measures. At 6 months, angiography showed that the mean ( $\pm$ SD) in-segment late luminal loss was  $0.74\pm 0.86$  mm in the uncoated-balloon group versus  $0.03\pm 0.48$  mm in the coated-balloon group ( $P=0.002$ ). A total of 10 of 23 patients (43%) in the uncoated-balloon group had restenosis, as compared with 1 of 22 patients (5%) in the coated-balloon group ( $P=0.002$ ). At 12 months, the rate of major adverse cardiac events was 31% in the uncoated-balloon group and 4% in the coated-balloon group ( $P=0.01$ ). This difference was primarily due to the need for target-lesion revascularization in six patients in the uncoated-balloon group ( $P=0.02$ ).

#### CONCLUSIONS

Treatment of coronary in-stent restenosis with paclitaxel-coated balloon catheters significantly reduced the incidence of restenosis. These data suggest that the inhibition of restenosis by local drug delivery may not require stent implantation and sustained drug release at the site of injury. (ClinicalTrials.gov number, NCT00106587.)

From Universitätsklinikum des Saarlandes, Homburg/Saar (B.S., M.B.); Universitätsklinikum, Freiburg (C.H.); Campus Virchow-Klinikum (W.B.) and Campus Charité Mitte (W.R., U.S.), Universitätsklinikum Charité, Berlin; Universitätsklinikum Mannheim, Ruprecht Karls Universität Heidelberg, Mannheim (D.H.); and Deutsche Klinik für Diagnostik, Wiesbaden (U.D.) — all in Germany. Address reprint requests to Dr. Scheller at the Klinik für Innere Medizin III, Universitätsklinikum des Saarlandes, Homburg/Saar, Germany, or at [bruno.scheller@uniklinikum-saarland.de](mailto:bruno.scheller@uniklinikum-saarland.de).

N Engl J Med 2006;355:2113-24.

Copyright © 2006 Massachusetts Medical Society.

**T**HE INCIDENCE OF IN-STENT RESTENOSIS after percutaneous coronary intervention ranges from 5 to 35% after the implantation of an uncoated stent and is somewhat lower after the implantation of a drug-eluting stent in patients who are at moderate risk.<sup>1</sup> Treatment of in-stent restenosis with a balloon catheter for coronary angioplasty is limited by high rates of restenosis (39 to 67%).<sup>2-6</sup> Other approaches, such as the implantation of a second, uncoated stent or mechanical debulking (e.g., rotablation), have not been associated with a significant reduction in recurrent in-stent restenosis.<sup>2</sup> Intracoronary irradiation (brachytherapy) has been found to be effective in this setting, with recurrence rates of 16 to 23%.<sup>3,7</sup> The implantation of drug-eluting stents in restenotic stented lesions has had similar results. Rates of restenosis of 13 to 20% with the Cypher stent and of 15 to 22% with the Taxus stent have been reported.<sup>5-10</sup> However, these stent-in-stent approaches involve two or more layers of metal in a native coronary artery. Furthermore, a restenosis rate of 43% has been reported after treatment of a restenotic drug-eluting stent with a second drug-eluting stent.<sup>11</sup>

Restenosis that is caused by neointimal hyperplasia is a slow process, suggesting that the local administration of a drug would need to be prolonged in order to be beneficial. Stent-based local drug delivery provides sustained drug release with the use of stents that have special features for drug release, such as a polymer coating.<sup>12,13</sup> However, cell-culture experiments indicate that even brief contact between vascular smooth-muscle cells and lipophilic taxane compounds can inhibit the proliferation of such cells for a long period.<sup>14-16</sup> In experiments in swine, intracoronary delivery of paclitaxel by means of contrast medium or a drug-coated balloon catheter resulted in concentrations of the drug in vascular tissue that were high enough to have antiproliferative effects, thus leading to a significant reduction in neointimal proliferation.<sup>15-18</sup> In these studies in animals, the most pronounced reduction of neointimal formation was seen with paclitaxel-coated balloon catheters.<sup>18,19</sup>

The aim of our trial, called the Treatment of In-Stent Restenosis by Paclitaxel-Coated Balloon Catheters (PACCOCATH ISR), was to investigate the use of angioplasty balloon catheters coated with paclitaxel for the treatment of coronary in-stent restenosis. The short-term tolerance, safety, and efficacy of this new approach were evaluated.

---

## METHODS

---

### STUDY DESIGN

The study was a double-blind, randomized pilot trial performed at five departments of cardiology at the medical schools of the University of Berlin, Freiburg, Homburg–Saar, and Mannheim–Heidelberg in Germany. The study was sponsored by Bavaria Medizin Technologie, Oberpfaffenhofen, Germany, which manufactured the balloon catheters used in the study. The sponsor had no role in the design or conduct of the study, in the analysis of the results, in the decision to publish, or in the drafting of the manuscript. The authors held the data. The authors vouch for the accuracy and completeness of the data presented.

The study was performed according to the Declaration of Helsinki and World Health Organization guidelines. Furthermore, the requirements of sections 20 to 22 of the German medical device law and of the European standard EN 540 were followed. All patients gave written informed consent. The study was approved by the appropriate local ethics committees.

Eligible patients were at least 18 years of age, had clinical evidence of stable or unstable angina or an abnormal functional study, and had a single restenotic lesion in a stented coronary artery. Major clinical criteria for exclusion were acute myocardial infarction within the previous 72 hours; chronic renal insufficiency with a serum creatinine level of more than 2.0 mg per deciliter (177  $\mu$ mol per liter); a known hypersensitivity or contraindication to aspirin, heparin, clopidogrel, abciximab, or paclitaxel; and sensitivity to contrast medium that could not be controlled with premedication. We also excluded patients who had concomitant medical illnesses that required cytostatic or radiation therapy, that might cause the patient to be noncompliant with the protocol, or that were associated with a life expectancy of less than 2 years. Angiographic exclusion criteria were a stented segment that was 30 mm or longer, a vessel diameter of less than 2.5 mm, stenosis of less than 70% of the luminal diameter, clinically significant calcification of the target lesion, and thrombus in the target lesion.

### INTERVENTIONAL PROCEDURE

Cardiac catheterization was performed through the femoral artery. Patients received 250 mg of aspirin intravenously. Heparin was given as an initial bolus of 2500 to 10,000 IU that was adjusted accord-

**Table 1. Baseline Clinical and Angiographic Characteristics (Intention-to-Treat Analysis).\***

| Characteristic                            | Uncoated Balloon (N=26) | Paclitaxel-Coated Balloon (N=26) | P Value |
|---|-------------------------|----------------------------------|---------|
| Age — yr                                  | 63.5±10.5               | 63.6±11.2                        | 0.97    |
| Male sex — no. (%)                        | 17 (65)                 | 20 (77)                          | 0.54    |
| Other conditions — no. (%)                |                         |                                  |         |
| Diabetes mellitus                         | 6 (23)                  | 4 (15)                           | 0.48    |
| Hyperlipidemia                            | 22 (85)                 | 20 (77)                          | 0.73    |
| Smoking history                           | 15 (58)                 | 11 (42)                          | 0.41    |
| Hypertension                              | 20 (77)                 | 22 (85)                          | 0.73    |
| Unstable angina                           | 12 (46)                 | 11 (42)                          | 1.00    |
| Coronary artery disease — no. (%)         |                         |                                  | 0.84    |
| Single-vessel disease                     | 5 (19)                  | 6 (23)                           |         |
| Two-vessel disease                        | 10 (38)                 | 11 (42)                          |         |
| Three-vessel disease                      | 11 (42)                 | 9 (35)                           |         |
| Vessels affected — no. (%)                |                         |                                  | 0.66    |
| Right coronary artery                     | 10 (38)                 | 9 (35)                           |         |
| Left circumflex coronary artery           | 6 (23)                  | 4 (15)                           |         |
| Left anterior descending coronary artery  | 10 (38)                 | 13 (50)                          |         |
| Pattern of in-stent restenosis — no. (%)† |                         |                                  | 0.70    |
| IA  | 0                       | 0                                |         |
| IB  | 2 (8)                   | 0                                |         |
| IC  | 5 (19)                  | 5 (19)                           |         |
| II  | 10 (38)                 | 12 (46)                          |         |
| III                                       | 8 (31)                  | 8 (31)                           |         |
| IV  | 1 (4)                   | 1 (4)                            |         |

\* Plus-minus values are means ±SD. Percentages may not total 100 because of rounding.

† Patterns are listed according to the Mehran classification.<sup>23</sup> Pattern I includes all focal lesions, with IA indicating an articulation or gap between lesions, IB indicating a margin, IC indicating a focal body, and ID indicating multifocal bodies; pattern II includes diffuse restenosis within the stent; pattern III includes diffuse in-stent restenosis extending outside the stent; and pattern IV includes totally occluded in-stent restenosis.

ing to the activated clotting time, with a target of 200 to 250 seconds. Patients received a loading dose of 300 mg of clopidogrel the day before the procedure or 600 mg immediately beforehand. Glycoprotein IIb/IIIa antagonists were administered at the operator's discretion.

After intracoronary injection of nitroglycerin (at a dose of 100 to 200  $\mu$ g), baseline angiography of the target vessel was performed in at least two near-orthogonal views showing the target lesion free of foreshortening and vessel overlap. After assessment with respect to angiographic criteria for exclusion had been performed, each eligible patient was randomly assigned by lot to undergo balloon angioplasty of the target lesion with either a paclitaxel-coated balloon catheter or an uncoated

catheter. Standard angioplasty catheters (Orbus X, Bavaria Medizin Technologie) were supplied either uncoated or coated with a paclitaxel dose of 3  $\mu$ g per square millimeter of balloon surface area.

Dilation of the target lesion was usually performed before the study intervention, with the use of a nonstudy balloon catheter with a diameter that was 0.5 mm smaller than that of the study balloon. The study balloon was inflated in the same fashion as a conventional balloon catheter. The recommended time of inflation was 60 seconds. Immediately after the procedure, heparin was discontinued. Vascular sheaths were removed according to usual hospital practice. After the procedure, the study balloon was saved for a determination of the residual paclitaxel content.<sup>18</sup>

**Table 2. Procedural Data and Angiographic Findings during Intervention and at 6 Months (Intention-to-Treat Analysis).\***

| Variable   | Uncoated Balloon (N=26) | Paclitaxel-Coated Balloon (N=26) | Absolute Difference (95% CI) | P Value |
|--|-------------------------|----------------------------------|------------------------------|---------|
| <b>Procedural data</b>                               |                         |                                  |                              |         |
| Study balloon  |                         |                                  |                              |         |
| Diameter — mm  | 2.9±0.4                 | 2.9±0.3                          | 0.0 (−0.2 to 0.2)            | 1.00    |
| Length — mm  | 23.8±5.0                | 24.6±5.1                         | −0.7 (−3.6 to 2.0)           | 0.58    |
| Predilation of target lesion — no. (%)               | 17 (65)                 | 18 (69)                          |                              | 0.77    |
| Mean balloon pressure — atm                          | 13.2±2.8                | 12.7±2.6                         | 0.5 (−1.0 to 2.0)            | 0.50    |
| Balloon inflation time — sec                         | 83.7±49.6               | 81.5±48.7                        | 2.1 (−25.3 to 29.5)          | 0.88    |
| Paclitaxel residue on balloon after procedure — %    | NA                      | 4.2±4.1                          |                              | NA      |
| Additional stents — no. (%)                          | 1 (4)                   | 2 (8)                            |                              | 0.55    |
| Glycoprotein IIb/IIIa antagonists — no. (%)          | 4 (15)                  | 3 (12)                           |                              | 0.69    |
| TIMI flow after procedure — no. (%)                  |                         |                                  |                              |         |
| Grade 2  | 1 (4)                   | 0                                |                              | 0.31    |
| Grade 3  | 25 (96)                 | 26 (100)                         |                              |         |
| <b>Angiographic measurements during intervention</b> |                         |                                  |                              |         |
| Lesion length — mm                                   | 18.1±7.8                | 17.9±6.2                         | 0.2 (−4.0 to 4.4)            | 0.93    |
| Reference diameter — mm                              | 2.95±0.45               | 2.94±0.39                        | 0.01 (−0.25 to 0.27)         | 0.93    |
| Minimal luminal diameter — mm                        |                         |                                  |                              |         |
| Before procedure                                     | 0.67±0.40               | 0.75±0.32                        | −0.08 (−0.30 to 0.14)        | 0.47    |
| After procedure                                      | 2.46±0.53               | 2.49±0.49                        | −0.03 (−0.33 to 0.27)        | 0.83    |

**QUANTITATIVE CORONARY ANGIOGRAPHY**

Angiography was performed before and after all interventions and at 6 months, with the use of identical projections and analyses. Quantitative analysis of the coronary angiographic images was performed by investigators at an independent core laboratory who were unaware of the study-group assignments. The CAAS II research system (Pie Medical Imaging) was used for automated contour detection and quantification. Measurements included the inner stenotic area, the stented area with measurement shoulder to shoulder (in-stent), and the total stented area plus 5 mm of the proximal and distal area (in-segment). Restenosis was defined as stenosis of at least 50% of the luminal diameter at 6 months.

**FOLLOW-UP AND END POINTS**

Patients received daily aspirin (100 mg) and clopidogrel (75 mg) orally for 1 month, followed by treatment with aspirin alone. Patients underwent follow-up angiography 6 months after the intervention, with clinical observation for a total of 12 months. All end points and adverse events were

adjudicated on the basis of a consensus among the investigators. The investigators and the study staff at the core laboratory remained unaware of the patients' study-group status until the database was closed.

The late luminal loss (the difference between the in-segment minimal luminal diameter after the procedure and at 6 months, as evaluated by quantitative coronary angiography) was the primary end point. Secondary end points included the rate of restenosis (a binary variable) and rates of combined clinical events at 6 and 12 months, including acute and subacute closure of the vessel, target-lesion revascularization, myocardial infarction, cerebral stroke, and death.

Acute closure was defined as the occurrence of new, severely reduced flow (grade 0 or 1, according to the Thrombolysis in Myocardial Infarction [TIMI] classification) within the target vessel during the intervention that persisted and required a nonassigned treatment strategy or resulted in myocardial infarction or death. Subacute closure was defined as closure occurring during follow-up. Target-lesion revascularization was defined as per-

Table 2. (Continued.)

| Variable  | Uncoated Balloon (N=26) | Paclitaxel-Coated Balloon (N=26) | Absolute Difference (95% CI) | P Value |
|---|-------------------------|----------------------------------|------------------------------|---------|
| <b>Angiographic findings at 6 mo</b>                  |                         |                                  |                              |         |
| No. of patients                                       | 23                      | 22                               |                              |         |
| Minimal luminal diameter — mm                         |                         |                                  |                              |         |
| In-stent  | 1.60±0.89               | 2.31±0.66                        | -0.71 (-1.18 to 0.24)        | 0.004   |
| In-segment  | 1.57±0.86               | 2.22±0.57                        | -0.65 (-1.09 to 0.21)        | 0.005   |
| Late luminal loss — mm                                |                         |                                  |                              |         |
| In-stent  | 0.76±0.86               | 0.09±0.49                        | 0.67 (0.24 to 1.09)          | 0.003   |
| In-segment  | 0.74±0.86               | 0.03±0.48                        | 0.70 (0.28 to 1.12)          | 0.002   |
| Restenosis — no. (%)                                  |                         |                                  |                              |         |
| In-stent  | 10 (43)                 | 1 (5)                            | 0.39 (0.15 to 0.63)          | 0.002   |
| In-segment  | 10 (43)                 | 1 (5)                            | 0.39 (0.15 to 0.63)          | 0.002   |
| Pattern of in-stent restenosis — no. (%) <sup>†</sup> |                         |                                  |                              | 0.59    |
| IC  | 4 (40)                  | 0                                |                              |         |
| II  | 3 (30)                  | 1 (100)                          |                              |         |
| III   | 1 (10)                  | 0                                |                              |         |
| IV  | 2 (20)                  | 0                                |                              |         |
| TIMI flow — no. (%)                                   |                         |                                  |                              | 0.36    |
| Grade 0 or 1  | 2 (9)                   | 0                                |                              |         |
| Grade 2   | 2 (9)                   | 0                                |                              |         |
| Grade 3   | 19 (83)                 | 22 (100)                         |                              |         |
| Left ventricular function — %                         | 61.3±11.3               | 58.5±14.5                        | 2.7 (-5.4 to 10.9)           | 0.45    |

\* Plus-minus values are means ±SD. TIMI denotes Thrombolysis in Myocardial Infarction, and NA not applicable.

<sup>†</sup> Percentages are based on the number of patients with restenosis. Patterns are listed according to the Mehran classification.<sup>23</sup>

cutaneous reintervention or coronary-artery bypass grafting involving the target lesion. The decision to perform a revascularization procedure was based on symptoms, anatomical findings on follow-up angiography, or both.

Myocardial infarction was assumed to have occurred if two of the following five criteria were present: chest pain lasting longer than 30 minutes; substantial changes on electrocardiography (ECG) that were typical of acute myocardial infarction (an ST elevation of 0.1 mV in at least two adjacent ECG leads or a new occurrence of a complete left bundle-branch block); a substantial increase in the level of creatine kinase or its MB isoform (at least three times the normal level); new, clinically significant Q waves; and chest pain leading to angiography up to 6 hours after the onset of the pain, with angiographic evidence of a totally occluded vessel, in contrast to the results of the previous study. Deaths were documented and confirmed by

reviewing hospital records or by contacting the patient's relatives or the treating physician.

Serious adverse events were defined according to international guidelines.<sup>20</sup> Target-lesion revascularization was considered a serious adverse event because it involved the hospitalization of the patient.

#### STATISTICAL ANALYSIS

We estimated that an enrollment of 52 patients would be needed for the study to have a statistical power of 90% to detect a reduction in late luminal loss from 1.0±0.5 mm in the uncoated-balloon group to 0.40±0.35 mm in the coated-balloon group, assuming a maximal dropout rate of 20%. Estimates of late luminal loss for this power calculation were based on data from trials of paclitaxel-coated stents and trials of brachytherapy for in-stent restenosis.<sup>3,12,21,22</sup>

We evaluated data for all end points in the in-

**Table 3. Results of Clinical Follow-up (Intention-to-Treat Analysis).\***

| Variable  | Uncoated Balloon (N=26)<br><i>no. of patients (%)</i> | Paclitaxel-Coated Balloon (N=26) | Absolute Difference (95% CI) | P Value |
|---|---|----------------------------------|------------------------------|---------|
| <b>After procedure</b>  |   |                                  |                              |         |
| Elevation in creatine kinase level  | 1 (4)   | 0                                | 0.04 (−0.4 to 1.2)           | 0.33    |
| <b>At 6 mo</b>  |   |                                  |                              |         |
| Target-lesion revascularization   | 6 (23)  | 0                                | 0.23 (0.06 to 0.40)          | 0.02    |
| Myocardial infarction   | 1 (4)   | 0                                | 0.04 (−0.4 to 1.2)           | 0.33    |
| Death   | 0   | 0                                |                              |         |
| Acute and subacute closure  | 0   | 0                                |                              |         |
| Stroke  | 0   | 0                                |                              |         |
| Target-lesion revascularization, myocardial infarction, acute or subacute closure, stroke, or death | 6 (23)  | 0                                | 0.23 (0.06 to 0.40)          | 0.02    |
| <b>At 12 mo</b>   |   |                                  |                              |         |
| Target-lesion revascularization   | 6 (23)  | 0                                | 0.23 (0.06 to 0.40)          | 0.02    |
| Myocardial infarction   | 2 (8)   | 1 (4)                            | 0.04 (−0.09 to 0.17)         | 0.56    |
| Death   | 0   | 1 (4)†                           | −0.04 (−0.12 to 0.04)        | 0.33    |
| Subacute closure  | 0   | 0                                |                              |         |
| Stroke  | 1 (4)   | 0                                | 0.04 (−0.4 to 1.2)           | 0.33    |
| Target-lesion revascularization, myocardial infarction, acute or subacute closure, stroke, or death | 8 (31)  | 1 (4)                            | 0.27 (0.07 to 0.47)          | 0.01    |

\* CI denotes confidence interval.

† Death was from myocardial infarction.

tention-to-treat analysis. An as-treated analysis was performed for comparison only. Continuous data are expressed as means  $\pm$ SD. Categorical variables were compared with the use of the two-sided chi-square test, and continuous variables were compared with the use of the two-sided Student's t-test. Confidence intervals for the difference between proportions were calculated with the use of a normal approximation of the binomial distribution without correction for continuity. Event-free survival was compared by Kaplan–Meier analysis with the use of the Mantel–Cox log-rank test constructed by SPSS software, version 13.0.1. A two-sided P value of less than 0.05 was considered to indicate statistical significance.

## RESULTS

### PATIENTS

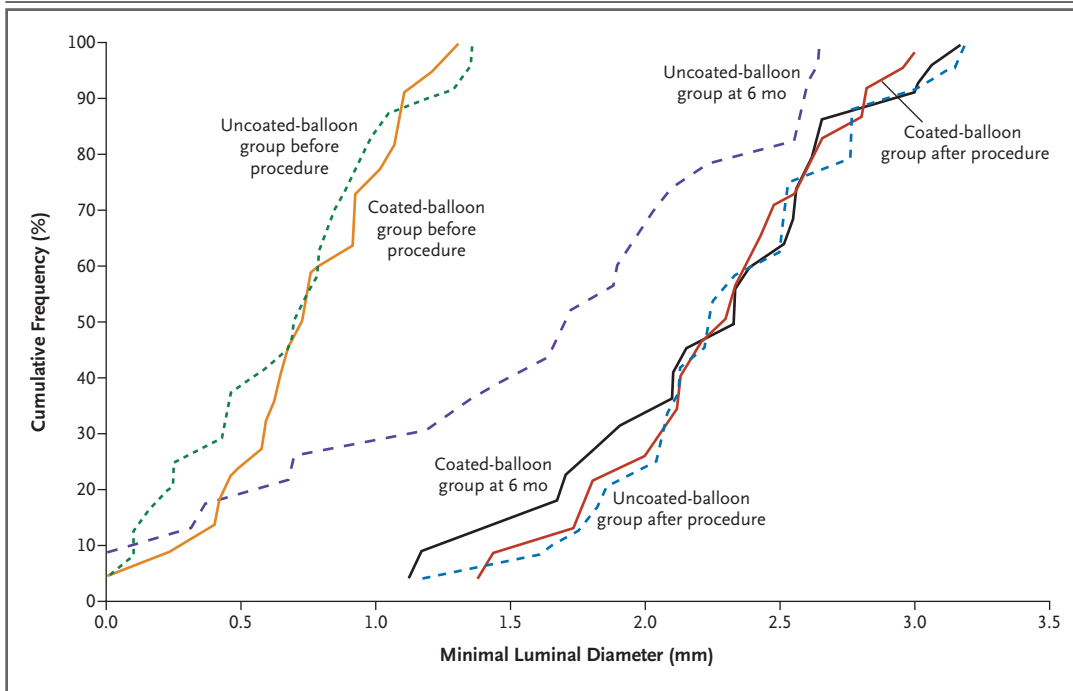
Fifty-two patients were enrolled in the trial between December 16, 2003, and July 22, 2004. Twenty-six patients were randomly assigned to the uncoated-

balloon group and 26 to the coated-balloon group. One patient who was assigned to the uncoated-balloon group was erroneously treated with a coated-balloon catheter taken from a nonassigned set, but the data from this patient were evaluated with the uncoated-balloon group in the intention-to-treat analysis.

Baseline characteristics of the patients were very similar in the two groups (Table 1). The mean age of patients in the study was 63.6 years; 71% were men. Most patients had multivessel coronary artery disease. The pattern of in-stent restenosis was predominantly diffuse.<sup>23</sup>

### ANGIOPLASTY

Procedural data — including the size of the balloon, the use of additional stents, and the use of glycoprotein IIb/IIIa antagonists — were also similar in the two groups (Table 2). The primary procedure was successful in 25 of 26 patients in the uncoated-balloon group and in all 26 patients in the coated-balloon group. The patient from the un-



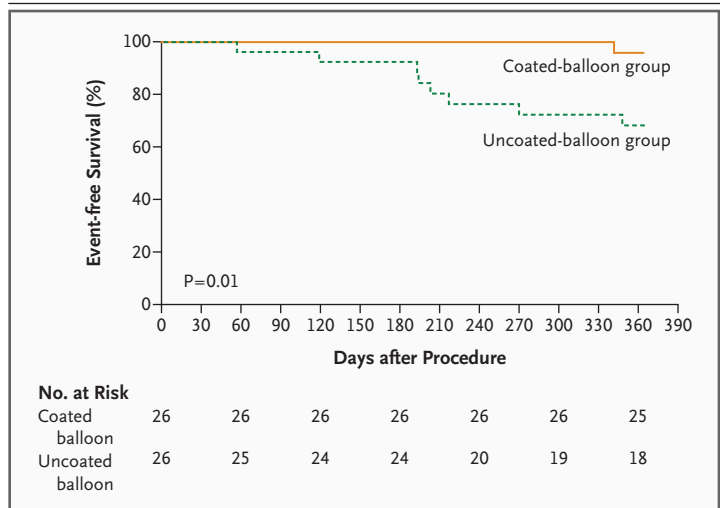
**Figure 1. Cumulative Frequency Distribution of In-Segment Minimal Luminal Diameter on Quantitative Coronary Angiography (Intention-to-Treat Analysis).**

Data are shown for the uncoated-balloon group and the coated-balloon group before the procedure, after the procedure, and at 6 months.

coated-balloon group who was erroneously treated with a paclitaxel-coated balloon had initially presented with an occluded stent and had only TIMI grade 2 flow after the procedure. Acute closure of a small septal branch vessel, without evidence of infarction, occurred in one patient who was treated with a drug-coated balloon. No other acute adverse events were considered to be attributable to the investigational device. After the procedure, about 4% of the drug remained on the surface of the paclitaxel-coated balloons.

**FOLLOW-UP AT 6 MONTHS**

All 52 patients underwent clinical follow-up during the first 7 months. One myocardial infarction occurred in the uncoated-balloon group about 7 months after the procedure; no patient died during this period. None of the patients in the coated-balloon group underwent repeated target-lesion revascularization during the first 6 months or during follow-up angiography. In contrast, 6 of 26 patients (23%) in the uncoated-balloon group un-



**Figure 2. Event-free Survival in the Two Groups at 1 Year.**

Survival free from acute and subacute vessel closure, target-lesion revascularization, myocardial infarction, and death was compared by Kaplan-Meier analysis with the use of the Mantel-Cox log-rank test.

**Table 4. Adverse Events and Serious Adverse Events.**

| Patient No.                 | Time and Type of Event   | Relationship to Procedure* | Outcome                                 |
|-----------------------------|--|----------------------------|---|
| <b>Adverse events</b>       |  |                            |   |
| <b>Uncoated-stent group</b> |  |                            |   |
| 18                          | Day 1; small groin hematoma  | Related                    | Complete recovery                       |
| 19                          | Day 1; small groin hematoma  | Related                    | Complete recovery                       |
| 19                          | Day 1; phlebitis in right hand due to intravenous line   | Not related                | Resolved after antibiotic treatment     |
| 28                          | 6 Mo; renal insufficiency  | Not related                | Ongoing condition                       |
| 29                          | Day 1; elevated creatine kinase MB level after procedure   | Probably related           | Complete recovery by hospital discharge |
| 29                          | 6 Mo; pronounced hyperlipidemia  | Not related                | Ongoing condition                       |
| 40                          | 1 Mo; dyspnea and chest pain not typical of angina pectoris                                      | Probably not related       | Complete recovery                       |
| 43                          | Day 1; small groin hematoma  | Related                    | Complete recovery                       |
| 45                          | Day 1; supraventricular tachycardia  | Probably not related       | Spontaneous resolution                  |
| 45                          | 6 Mo; dysuria  | Not related                | Complete recovery                       |
| 48                          | 1 Mo; abdominal pain   | Not related                | Complete recovery                       |
| 55                          | 6 Mo; hypertension   | Not related                | Complete recovery                       |
| <b>Coated-stent group</b>   |  |                            |   |
| 12                          | Day 1; increased levels of amylase and lipase; transient pancreatitis                            | Probably not related       | Complete recovery                       |
| 20                          | Day 1; acute closure of a septal branch of the left anterior descending artery (diameter, <2 mm) | Probably related           | Complete recovery                       |
| 23                          | Day 1; small groin hematoma  | Related                    | Complete recovery                       |
| 30                          | Day 1; small groin hematoma  | Related                    | Complete recovery                       |
| 36                          | 1 Mo; dyspnea, atypical angina   | Possibly related           | Complete recovery                       |
| 39                          | Day 1; groin hematoma  | Related                    | Complete recovery                       |
| 39                          | 2 Mo; dyspnea  | Probably not related       | Complete recovery                       |
| 41                          | Day 2; transient ischemic attack with brachiofacial dominance for 2 hr                           | Probably not related       | Complete recovery                       |
| 44                          | Day 1; dysuria and leukocytosis; treated with antibiotics  | Probably not related       | Complete recovery                       |
| 53                          | Day 1; transient headache  | Not related                | Complete recovery                       |

derwent repeated angioplasty during this period ( $P=0.02$ ) (Table 3).

A total of 45 of the 52 patients (87%) underwent follow-up angiography after 4 to 7 months; 7 patients declined to undergo angiographic follow-up owing to an absence of clinical symptoms. The mean in-segment late luminal loss — the primary end point — was  $0.74\pm 0.86$  mm in the uncoated-balloon group and  $0.03\pm 0.48$  mm in the coated-balloon group ( $P=0.002$ ) (Table 2 and Fig. 1). Restenosis occurred in 10 of 23 patients (43%) in the uncoated-balloon group and in 1 of 22 patients (5%) in the coated-balloon group ( $P=0.002$ ).

#### FOLLOW-UP AT 12 MONTHS

In the coated-balloon group, one patient died 11 months after the procedure, after having a myocardial infarction. In the uncoated-balloon group, one patient had a thrombotic cerebral stroke, and another had a myocardial infarction. No target-lesion revascularizations or other major cardiac events occurred in any of the patients during the second 6 months of follow-up (Table 3). The Kaplan–Meier estimates of survival free from clinical events for the two groups during the 12 months of the trial are shown in Figure 2. The significant difference in event rates (31% in the uncoated-bal-

Table 4. (Continued.)

| Patient No.                    | Time and Type of Event   | Relationship to Procedure* | Outcome                   |
|--------------------------------|--|----------------------------|---------------------------|
| <b>Serious adverse events†</b> |  |                            |                           |
| Uncoated-stent group           |  |                            |                           |
| 5                              | 6 Mo; target-lesion revascularization  | Probably related           | Complete recovery         |
| 6                              | 11 Mo; hospitalization for stroke  | Not related                | Recovery with sequelae    |
| 19                             | 2 Mo; hospitalization for unstable angina; target-lesion revascularization   | Probably related           | Complete recovery         |
| 26                             | 6 Mo; hospitalization for unstable angina pectoris   | Not assessed               | Not assessed              |
| 31                             | 2 Mo; hospitalization for angina pectoris  | Not related                | Complete recovery         |
| 35                             | 6 Mo; target-lesion revascularization  | Probably related           | Complete recovery         |
| 37                             | 6 Mo; target-lesion revascularization, myocardial infarction   | Possibly related           | Complete recovery         |
| 40                             | 6 Mo; target-lesion revascularization  | Possibly related           | Complete recovery         |
| 43                             | 6 Mo; myocardial infarction due to occlusion of a side branch during angioplasty of a nontarget lesion   | Not related                | Complete recovery         |
| 46                             | 7 Mo; target-lesion revascularization  | Possibly related           | Not assessed              |
| 49                             | 6 Mo; angioplasty of a nontarget lesion  | Not related                | Complete recovery         |
| 52                             | 1 Mo; admission to another hospital because of acute dyspnea and chest discomfort  | Possibly related           | Complete recovery         |
| Coated-stent group             |  |                            |                           |
| 8                              | Day 3; angina 2 days after treatment; good result of treated left circumflex coronary artery confirmed on angiography; two native stenotic segments in the right coronary artery treated by stent implantation | Not related                | Complete recovery         |
| 8                              | 1 Mo; angina; angioplasty of a nontarget lesion  | Not related                | Complete recovery         |
| 8                              | 3 Mo; angina; angiography showed resolution of vasospasm after administration of intracoronary nitroglycerin   | Not related                | Acute problems resolved   |
| 8                              | 6 Mo; hospitalization for angina   | Not related                | Diagnostic procedure only |
| 8                              | 7 Mo; hospitalization for peripheral vascular disease  | Not related                | Diagnostic procedure only |
| 12                             | 5 Mo; angina; angioplasty of a nontarget lesion; increased level of creatinine   | Not related                | Complete recovery         |
| 12                             | 7 Mo; implantation of a biventricular cardioverter-defibrillator   | Not related                | Recovery with sequelae    |
| 25                             | 9 Mo; hospitalization for unstable angina pectoris   | Not related                | Complete recovery         |
| 30                             | 11 Mo; death after myocardial infarction   | Possibly related           | Death                     |
| 36                             | 2 Mo; unscheduled angiography  | Not related                | Complete recovery         |
| 53                             | 6 Mo; hospitalization for unstable angina pectoris   | Not related                | Not assessed              |

\* This column describes the presumed relationship between the trial procedure and the reported adverse event. Some inconsistencies in this assessment were noted after the fact. In some cases, the determination of this relationship was made with reference to the entire interventional procedure; in other cases, the determination was made with reference to the specific use of a coated balloon catheter.

† As defined by the International Conference on Harmonisation,<sup>20</sup> serious adverse events included angioplasty performed during hospitalization.

loon group vs. 4% in the coated-balloon group,  $P=0.01$ ) was primarily a consequence of the difference in the rates of target-lesion revascularization.

#### ADVERSE EVENTS

A total of 45 adverse events and serious adverse events occurred (Table 4). Twenty-two adverse

events were recorded in 18 patients: 8 patients in the uncoated-balloon group and 10 in the coated-balloon group. A total of 23 serious adverse events occurred in 18 patients; 12 of these events occurred in patients treated with uncoated balloons, with 6 patients having restenosis of the target lesion. A total of 11 serious adverse events

occurred in 6 patients who were treated with drug-coated balloons. Of these patients, 5 had events that were classified as being unrelated to treatment, and 1 died from myocardial infarction, which was classified as being possibly related to treatment.

#### AS-TREATED ANALYSIS

When one patient was included in the coated-balloon group for the purposes of data analysis, the numbers changed slightly. In the uncoated-balloon group, the mean late luminal loss in the stenotic area was  $0.82 \pm 0.86$  mm, as compared with  $0.13 \pm 0.51$  mm in the coated-balloon group ( $P=0.002$ ). The advantage of the drug-coated balloon also remained significant with respect to the minimal luminal diameter, target-lesion revascularization, major adverse cardiac events at 6 months, and target-lesion revascularization at 12 months. The difference between the groups in the rate of major adverse cardiac events at 12 months in this analysis was no longer significant ( $P=0.05$ ).

#### DISCUSSION

The aim of our study was to investigate the efficacy of a novel drug-coated balloon catheter in the prevention of restenosis after treatment of in-stent restenosis in a typical population of patients with this condition. For our pilot trial, late luminal loss was chosen as the primary end point because it is recognized to be a sensitive surrogate measure of restenosis, particularly in patients who have in-stent restenosis.<sup>24,25</sup> We recorded clinical measures indicative of target-lesion restenosis as well.

The handling of the drug-coated balloon catheter was identical to that of an uncoated catheter. After 6 months, there was a significant difference with respect to the primary end point in favor of patients who received the drug-coated balloon. This result was also reflected in the rate of restenosis. None of the patients in the coated-balloon group required repeated revascularization during the 12 months of follow-up. The effectiveness of drug-coated balloons was similar to results recently reported for drug-eluting stents in the treatment of in-stent restenosis.<sup>5</sup>

Local delivery of a drug by coated-balloon catheters differs from delivery by drug-eluting stents. Drug-eluting stents contain low doses of drugs that are slowly released from a polymer stent coat-

ing. In contrast, the drug-eluting balloons used in our trial are coated with the free drug. Dissolution of the drug is enhanced by adding to the coating a small amount of a radiographic contrast agent, which is known to improve the solubility of paclitaxel.<sup>15</sup> The balloon is in contact with the vessel wall for approximately 1 minute, and it releases most of the drug immediately, during the first inflation.<sup>18</sup>

These differences in technique result in a marked difference in the duration and concentration of drug exposure between drug-eluting stents and drug-coated balloons. When paclitaxel is administered with a drug-coated balloon, blood flow and other transport processes, as well as biotransformation, decrease antiproliferative activity in the tissue quite rapidly.<sup>17,18</sup> After the catheters were used in this trial, only about 4% of the original dose was found to be extractable from the surface of the balloon. On the basis of studies in animals,<sup>17,18</sup> we estimate that as much as 90% of the dose is lost in the bloodstream.

Nevertheless, the dose and duration of administration appear to be sufficient to prevent neointimal proliferation.<sup>14-17</sup> Studies in cell culture indicate that an increased concentration of paclitaxel in the culture medium compensates for a shorter incubation time and that the duration of inhibition of cell proliferation far exceeds the time during which the cells are exposed to the drug.<sup>14-16</sup> Preclinical studies have demonstrated a significant reduction of neointimal formation by drug-coated balloon catheters, as compared with drug-eluting stents.<sup>18,19</sup>

Disappointing results with drug-eluting stents, which have a fast or moderate rate of drug release,<sup>26</sup> may be explained by the fact that an optimal concentration of the drug (which is required to inhibit neointimal proliferation) is not reached during elution. Furthermore, the drug that is delivered by the drug-eluting balloon is more evenly distributed on the vessel surface than is the drug bound to the struts of a drug-eluting stent. Finally, the therapeutic agent contained in a drug-eluting stent must inhibit neointimal proliferation occurring in response to the injury caused by the stent struts themselves, whereas the stimulus to neointimal proliferation caused by inflation of the drug-eluting balloon is likely to be less marked and less prolonged.

A number of limitations of this pilot study

should be noted. The number of patients was small; larger trials will be required to provide definitive evidence of a clinical benefit. Whereas the core laboratory was not aware of study-group status, the coated balloons have a faintly white color, which differs slightly from that of uncoated balloons — a difference that might be observed by investigators. A comparison of this treatment and optimal current therapy (such as brachytherapy) in randomized trials is required. Furthermore, factors such as the specific requirements for medication during and after treatment and compliance with prescribed medication regimens should be addressed.

In conclusion, in this pilot study, treatment of coronary in-stent restenosis with paclitaxel-coated balloon catheters significantly lowered the incidence of adverse events and recurrent in-stent re-

stenosis. Our clinical findings suggest that the inhibition of restenosis by local drug delivery may not require the implantation of stents and a prolonged release of a drug. The scale of the trial was not aimed at justifying clinical application or regulatory approval of the drug-coated balloon; larger studies will be required to determine whether the effects observed in this trial can be replicated.

Supported by Bavaria Medizin Technologie.

Dr. Scheller and Dr. Speck report being coinventors on a patent application for various methods of inhibiting restenosis (including the technique used in this trial), which was submitted by Charité University Hospital in Berlin. Dr. Böhm reports receiving lecture fees from Boehringer Ingelheim, Pfizer, AstraZeneca, and Sanofi Aventis. Dr. Speck reports receiving consulting fees from Schering and grant support from Bavaria Medizin Technologie. No other potential conflict of interest relevant to this article was reported.

We thank Matthias Braeutigam, M.D., of Schering, Berlin, for his support of basic experiments leading to our clinical pilot study.

#### REFERENCES

1. Stone GW, Ellis SG, Cannon L, et al. Comparison of a polymer-based paclitaxel-eluting stent with a bare metal stent in patients with complex coronary artery disease: a randomized controlled trial. *JAMA* 2005;294:1215-23.
2. vom Dahl J, Dietz U, Haager PK, et al. Rotational atherectomy does not reduce recurrent in-stent restenosis: results of the Angioplasty versus Rotational Atherectomy for Treatment of Diffuse In-Stent Restenosis Trial (ARTIST). *Circulation* 2002;105:583-8.
3. Waksman R, Cheneau E, Ajani AE, et al. Intracoronary radiation therapy improves the clinical and angiographic outcomes of diffuse in-stent restenotic lesions: results of the Washington Radiation for In-Stent Restenosis Trial for Long Lesions (Long WRIST) Studies. *Circulation* 2003;107:1744-9.
4. Alfonso F, Zueco J, Cequier A, et al. A randomized comparison of repeat stenting with balloon angioplasty in patients with in-stent restenosis. *J Am Coll Cardiol* 2003;42:796-805.
5. Kastrati A, Mehilli J, von Beckerath N, et al. Sirolimus-eluting stent or paclitaxel-eluting stent vs balloon angioplasty for prevention of recurrences in patients with coronary in-stent restenosis: a randomized controlled trial. *JAMA* 2005;293:165-71.
6. Iofina E, Haager PK, Radke PW, et al. Sirolimus- and paclitaxel-eluting stents in comparison with balloon angioplasty for treatment of in-stent restenosis. *Catheter Cardiovasc Interv* 2005;64:28-34.
7. Radke PW, Kobella S, Kaiser A, et al. Treatment of in-stent restenosis using a paclitaxel-eluting stent: acute results and long-term follow-up of a matched-pair comparison with intracoronary beta-radiation therapy. *Eur Heart J* 2004;25:920-5.
8. Degertekin M, Regar E, Tanabe K, et al. Sirolimus-eluting stent for treatment of complex in-stent restenosis: the first clinical experience. *J Am Coll Cardiol* 2003;41:184-9.
9. Tanabe K, Serruys PW, Grube E, et al. TAXUS III Trial: in-stent restenosis treated with stent-based delivery of paclitaxel incorporated in a slow-release polymer formulation. *Circulation* 2003;107:559-64.
10. Werner GS, Emig U, Krack A, Schwarz G, Figulla HR. Sirolimus-eluting stents for the prevention of restenosis in a worst-case scenario of diffuse and recurrent in-stent restenosis. *Catheter Cardiovasc Interv* 2004;63:259-64.
11. Lemos PA, Hoye A, Goedhart D, et al. Clinical, angiographic, and procedural predictors of angiographic restenosis after sirolimus-eluting stent implantation in complex patients: an evaluation from the Rapamycin-Eluting Stent Evaluated At Rotterdam Cardiology Hospital (RESEARCH) study. *Circulation* 2004;109:1366-70.
12. Stone GW, Ellis SG, Cox DA, et al. A polymer-based, paclitaxel-eluting stent in patients with coronary artery disease. *N Engl J Med* 2004;350:221-31.
13. van der Giessen WJ, Lincoff AM, Schwartz RS, et al. Marked inflammatory sequelae to implantation of biodegradable and nonbiodegradable polymers in porcine coronary arteries. *Circulation* 1996;94:1690-7.
14. Axel DI, Kunert W, Goggelmann C, et al. Paclitaxel inhibits arterial smooth muscle cell proliferation and migration in vitro and in vivo using local drug delivery. *Circulation* 1997;96:636-45.
15. Scheller B, Speck U, Romeike B, et al. Contrast media as carriers for local drug delivery: successful inhibition of neointimal proliferation in the porcine coronary stent model. *Eur Heart J* 2003;24:1462-7.
16. Scheller B, Speck U, Schmitt A, Böhm M, Nickenig G. Addition of paclitaxel to contrast media prevents restenosis after coronary stent implantation. *J Am Coll Cardiol* 2003;42:1415-20.
17. Speck U, Scheller B, Abramjuk C, Grossmann S, Mahnkopf D, Simon O. Inhibition of restenosis in stented porcine coronary arteries: uptake of paclitaxel from angiographic contrast media. *Invest Radiol* 2004;39:182-6.
18. Scheller B, Speck U, Abramjuk C, Bernhardt U, Böhm M, Nickenig G. Paclitaxel balloon coating, a novel method for prevention and therapy of restenosis. *Circulation* 2004;110:810-4.
19. Speck U, Scheller B, Abramjuk C, et al. Neointima inhibition: comparison of effectiveness of non-stent-based local drug delivery and a drug-eluting stent in porcine coronary arteries. *Radiology* 2006;240:411-8.
20. International Conference on Harmonisation of Technical Requirements for Registration of Pharmaceuticals for Human Use. ICH harmonized tripartite guideline: clinical safety data management — definitions and standards for expedited reporting: E2A. October 1994. (Accessed October 23, 2006, at <http://www.ich.org/LOB/media/MEDIA436.pdf>)
21. Waksman R, Ajani AE, White RL, et al. Intravascular gamma radiation for in-stent restenosis in saphenous-vein by-

- pass grafts. *N Engl J Med* 2002;346:1194-9.
22. Waksman R, White RL, Chan RC, et al. Intracoronary gamma-radiation therapy after angioplasty inhibits recurrence in patients with in-stent restenosis. *Circulation* 2000;101:2165-71.
23. Mehran R, Dangas G, Abizaid AS, et al. Angiographic patterns of in-stent restenosis: classification and implications for long term outcome. *Circulation* 1999; 100:1872-8.
24. Mauri L, Orav EJ, Candia SC, Cutlip DE, Kuntz RE. Robustness of late lumen loss in discriminating drug-eluting stents across variable observational and randomized trials. *Circulation* 2005;112:2833-9.
25. Moliterno DJ. Healing Achilles — sirolimus versus paclitaxel. *N Engl J Med* 2005; 353:724-7.
26. Lansky AJ, Costa RA, Mintz GS, et al. Non-polymer-based paclitaxel-coated coronary stents for the treatment of patients with de novo coronary lesions: angiographic follow-up of the DELIVER clinical trial. *Circulation* 2004;109:1948-54.

Copyright © 2006 Massachusetts Medical Society.