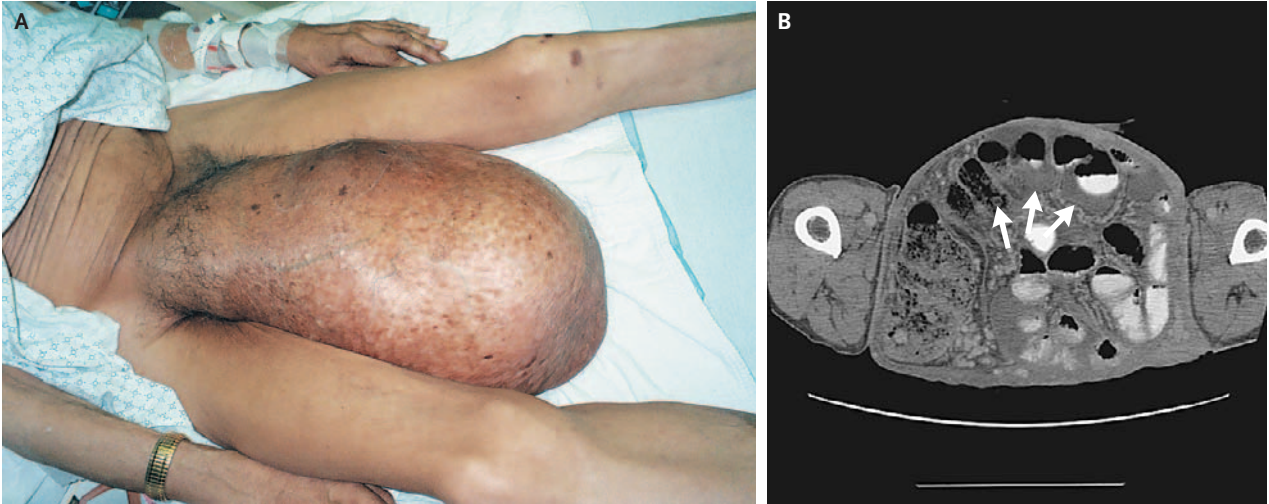


IMAGES IN CLINICAL MEDICINE

Inguinal Hernia



A 68-YEAR-OLD MAN WITH CHRONIC DYSURIA AND INCREASED URINARY frequency presented with three weeks of weakness and fever. Physical examination revealed a man with cachexia who had a large, right-sided inguinal hernia that had been enlarging for more than eight years (Panel A). Computed tomography revealed unobstructed bowel within the hernia sac (Panel B, arrows). A urinary tract infection was diagnosed, and the patient received a course of levofloxacin. Given the size of the hernia, surgical repair would have involved multiple sequential procedures with a high risk of intraoperative death. The patient declined surgical intervention.

Copyright © 2006 Massachusetts Medical Society.

David Rosmarin, M.D.
Chen S. Tan, M.D.

New York University School of Medicine
New York, NY 10016

Web-only Images in Clinical Medicine are published every week in the *Journal*. They are listed (with e page numbers) in the table of contents on the cover of the printed *Journal* and can be seen at www.nejm.org.