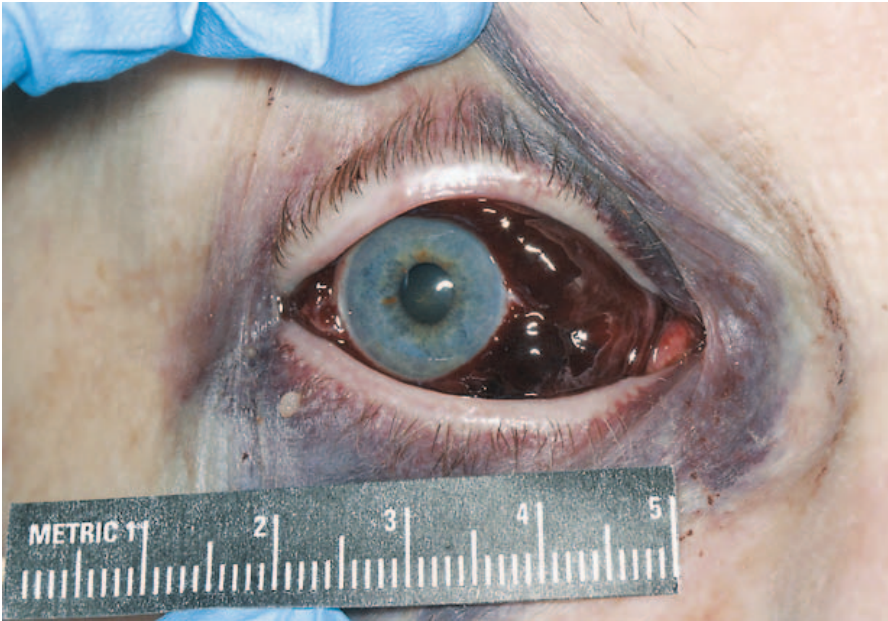


IMAGES IN CLINICAL MEDICINE

Ocular Bleeding Due to Anticoagulation



AN 83-YEAR-OLD WOMAN WITH A HISTORY OF HYPERTENSION, GLAUCOMA, and atrial fibrillation, who had a pacemaker and was receiving warfarin, woke up with a sensation of pain in the right eye and noticed what she thought was a big bruise. She had no headache, trauma, nuchal rigidity, nausea, or photophobia. Physical examination showed a subconjunctival hemorrhage in the right eye, as well as a defect in the nasal and superior temporal visual field, periorbital ecchymosis, and edema. The patient's visual acuity was unchanged from baseline. The blood pressure was 192/90 mm Hg, the intraocular pressure was 20 mm Hg, the hemoglobin level was 14.6 g per deciliter, and the international normalized ratio (INR) was 2.2. Computed tomography showed modest hemorrhage in the preseptal tissues overlying the globe and complete opacification of the right maxillary sinus with blood but no intracerebral hemorrhage or fracture. The bleeding slowly resolved over a period of six weeks. Because the INR was in the range desired, the dose of warfarin was not changed. There were no subsequent visual-field defects. The patient was not referred for further treatment and had no subsequent episodes.

Copyright © 2006 Massachusetts Medical Society.

Latha G. Stead, M.D.
Kurtis A. Judson, M.D.

Mayo Clinic
Rochester, MN 55905