

The NEW ENGLAND JOURNAL of MEDICINE

ESTABLISHED IN 1812

MARCH 29, 2007

VOL. 356 NO. 13

MRI Evaluation of the Contralateral Breast in Women with Recently Diagnosed Breast Cancer

Constance D. Lehman, M.D., Ph.D., Constantine Gatsonis, Ph.D., Christiane K. Kuhl, M.D., R. Edward Hendrick, Ph.D., Etta D. Pisano, M.D., Lucy Hanna, M.S., Sue Peacock, M.S., Stanley F. Smazal, M.D., Daniel D. Maki, M.D., Thomas B. Julian, M.D., Elizabeth R. DePeri, M.D., David A. Bluemke, M.D., Ph.D., and Mitchell D. Schnall, M.D., Ph.D., for the ACRIN Trial 6667 Investigators Group*

ABSTRACT

BACKGROUND

Even after careful clinical and mammographic evaluation, cancer is found in the contralateral breast in up to 10% of women who have received treatment for unilateral breast cancer. We conducted a study to determine whether magnetic resonance imaging (MRI) could improve on clinical breast examination and mammography in detecting contralateral breast cancer soon after the initial diagnosis of unilateral breast cancer.

METHODS

A total of 969 women with a recent diagnosis of unilateral breast cancer and no abnormalities on mammographic and clinical examination of the contralateral breast underwent breast MRI. The diagnosis of MRI-detected cancer was confirmed by means of biopsy within 12 months after study entry. The absence of breast cancer was determined by means of biopsy, the absence of positive findings on repeat imaging and clinical examination, or both at 1 year of follow-up.

RESULTS

MRI detected clinically and mammographically occult breast cancer in the contralateral breast in 30 of 969 women who were enrolled in the study (3.1%). The sensitivity of MRI in the contralateral breast was 91%, and the specificity was 88%. The negative predictive value of MRI was 99%. A biopsy was performed on the basis of a positive MRI finding in 121 of the 969 women (12.5%), 30 of whom had specimens that were positive for cancer (24.8%); 18 of the 30 specimens were positive for invasive cancer. The mean diameter of the invasive tumors detected was 10.9 mm. The additional number of cancers detected was not influenced by breast density, menopausal status, or the histologic features of the primary tumor.

CONCLUSIONS

MRI can detect cancer in the contralateral breast that is missed by mammography and clinical examination at the time of the initial breast-cancer diagnosis. (ClinicalTrials.gov number, NCT00058058.)

From the University of Washington Medical Center, Seattle (C.D.L., S.P.); Brown University, Providence, RI (C.G., L.H.); University of Bonn, Bonn, Germany (C.K.K.); Feinberg School of Medicine, Northwestern University, Chicago (R.E.H.); University of North Carolina, Chapel Hill (E.D.P.); Porter Adventist Hospital, Denver (S.F.S.); Scottsdale Medical Imaging, Scottsdale, AZ (D.D.M.); Allegheny General Hospital, Allegheny, PA (T.B.J.); Mayo Clinic, Jacksonville, FL (E.R.D.); Johns Hopkins University School of Medicine, Bethesda, MD (D.A.B.); and University of Pennsylvania Medical School, Philadelphia (M.D.S.). Address reprint requests to Dr. Lehman at the University of Washington Medical Center, Seattle Cancer Care Alliance, 825 Eastlake Ave., E, Rm. G3-200, P.O. Box 19023, Seattle, WA 98109, or at lehman@u.washington.edu.

*Members of the American College of Radiology Imaging Network (ACRIN) Trial 6667 Investigators Group are listed in the Appendix.

N Engl J Med 2007;356:1295-303.

Copyright © 2007 Massachusetts Medical Society.

A WOMAN WITH UNILATERAL BREAST cancer has an increased risk of having cancer in the contralateral breast.¹⁻⁶ In the 1990s, the role of mammography in improving the detection of contralateral cancers at the time of the initial diagnosis of breast cancer was firmly established; as compared with clinical breast examination alone, mammography resulted in a 1 to 3% increase in the number of cancers detected.⁷⁻⁹ Despite normal findings on clinical and mammographic examination of the contralateral breast at the time of the initial breast-cancer diagnosis, however, contralateral cancer was subsequently detected in up to 10% of women.^{1,3,5,6} When contralateral cancer is diagnosed after the initial treatment, the woman must undergo a second round of cancer therapy rather than the single round that would have been administered if the contralateral cancer had been detected at the time of the initial diagnosis.

The importance of clinical breast examination and mammography in the diagnostic workup of a woman with recently diagnosed breast cancer is not disputed. However, mammography and clinical breast examination have limitations — both methods yield false negative results.^{10,11} A recent large study showed that screening magnetic resonance imaging (MRI) can improve on mammography by detecting otherwise occult cancers in 1.2% of women at high risk.¹⁰ However, this study did not include women with a current diagnosis of breast cancer.

Preliminary studies have suggested that MRI can detect otherwise occult contralateral breast cancers in an average of 5% of women with a recent diagnosis of breast cancer.¹²⁻¹⁹ The rate of detection for tumors not identified by other means ranged from 3 to 24%, the specificity of MRI was variable, and the studies lacked follow-up data to confirm the negative predictive values of MRI in such women. We conducted a study to determine the number of clinically and mammographically occult cancers in the contralateral breast that could be detected by MRI in women with recently diagnosed unilateral breast cancer.

METHODS

The trial was conducted by the American College of Radiology Imaging Network (ACRIN), funded by the National Cancer Institute, and monitored by a data and safety monitoring board. It was open

to all interested sites that were approved by ACRIN through a general qualifying application and a protocol-specific application. The sites ranged from academic institutions to private practices. Between April 1, 2003, and June 10, 2004, a total of 1007 women with a recent diagnosis of unilateral breast cancer were enrolled at 25 sites.

Participating radiologists had to have interpreted a minimum of 50 breast MRI scans and had to have performed at least five magnetic resonance-guided breast biopsies. All participating facilities obtained approval for the study from their institutional review boards, and written informed consent was obtained from all patients.

PATIENTS

Women were eligible to participate in the study if they were 18 years of age or older and had received a diagnosis of unilateral breast cancer within 60 days before the study MRI was performed. Since the study was designed not to compare mammography with MRI but to determine the additional number of cancers detected by means of MRI after clinical and mammographic examination of the contralateral breast, all women were required to have had normal clinical and mammographic findings in the contralateral breast within 90 days before enrollment. Women were excluded from the study if they had undergone breast MRI within 12 months before enrollment, if they were pregnant, or if they had a contraindication for MRI (e.g., an implanted magnetic device or severe claustrophobia). Additional exclusion criteria were a breast-cancer diagnosis made more than 60 days before enrollment or chemotherapy or hormonal therapy for breast cancer within 6 months before enrollment.

DATA COLLECTION

All participants underwent dynamic, contrast-enhanced breast MRI. Minimum standard criteria were required for each MRI study performed: a 1.5-T or larger magnet, a dedicated breast-surface coil, and one image obtained before and two images obtained after the administration of contrast material, with three-dimensional, T₁-weighted, gradient-echo sequences (reception time, <60 msec; echo time, <20 msec). Initial and delayed images were obtained within 4 and 8 minutes after the injection of contrast material. Spatial-resolution criteria included voxels smaller than 0.9 mm in the frequency-encoding direction,

smaller than 1.8 mm in the phase-encoding direction, and 3 mm or smaller in the slice direction, providing full coverage of the breast.

All examinations were interpreted according to the American College of Radiology Breast Imaging Reporting and Data System (BI-RADS).²⁰ The initial MRI assessment was classified on a six-point scale (0, “needs additional imaging evaluation”; 1, “negative”; 2, “benign”; 3, “probably benign”; 4, “suspicious abnormality”; and 5, “highly suggestive of malignancy”). For examinations scored as 0 or 3, additional imaging was performed to determine the final BI-RADS assessment. For purposes of receiver-operating-characteristic (ROC) curve analysis, readers also rated the initial study MRI on a five-point malignancy scale (with a score of 1 denoting “definitely not malignant” and a score of 5 denoting “definitely malignant”). A diagnosis of cancer was based on histologic examination of a biopsy specimen and included all cases of invasive carcinoma or ductal carcinoma in situ.

Cancer status was followed for 365 days after the study MRI. Results of all breast-imaging tests, clinical examinations, and biopsies and surgeries were documented. To establish a reference standard, the study participants were classified as positive for cancer if a breast cancer was histologically verified within 365 days after the initial study MRI, and negative for cancer if the study records, including the 1-year follow-up, showed no diagnosis of cancer within that period. The details of all cancers diagnosed during the study were recorded, including the size and histologic features of the tumor and tumor–node–metastasis staging.

STATISTICAL ANALYSIS

Data were analyzed at the Center for Statistical Sciences at Brown University (Providence, RI), which serves as the biostatistics center for all ACRIN trials. The primary aim of the study was to determine the diagnostic yield of breast MRI, defined as the proportion of women with a recently diagnosed unilateral breast cancer and negative clinical and mammographic examinations of the contralateral breast in whom cancer in that breast was detected by MRI and histologically confirmed. The secondary aims included estimation of the sensitivity, specificity, negative predictive value, and positive predictive value of MRI and the associated positive biopsy rate; estimation of the ROC curve for MRI; and assessment of the diagnostic

yield, sensitivity, specificity, negative predictive value, positive predictive value, and associated positive biopsy rate according to mammographic density (fatty vs. dense), menopausal status (premenopausal or perimenopausal vs. postmenopausal), and the type of index cancer (invasive vs. in situ and lobular vs. nonlobular).

The final BI-RADS MRI assessment score was used to derive estimates of the diagnostic yield, sensitivity, specificity, negative predictive value, positive predictive value, and associated positive biopsy rate. This score was equal to the initial score if the initial score was 1, 2, 4, or 5. Participants with an initial score of 0 or 3 were assigned a final score that took into account the results of the workup after the initial MRI. For estimation of the diagnostic yield, sensitivity, and specificity, a final BI-RADS MRI score of 1, 2, or 3 was considered to be negative, and a final score of 0, 4, or 5 was considered to be positive. The same classification of the test result was used to estimate the positive predictive value of a final positive score. The positive predictive value was defined as the percentage of positive examinations that resulted in a histologic diagnosis of cancer within 1 year. The positive biopsy rate was defined as the percentage of all known biopsies performed after positive examinations that resulted in a histologic diagnosis of cancer within 1 year.²¹

Diagnostic test data from all participating readers for the primary and secondary analyses were pooled. The 95% confidence intervals for the binary test measures (diagnostic yield, sensitivity, specificity, negative predictive value, positive predictive value, and positive biopsy rate) were derived with the use of the normal approximation of the binomial distribution. Exact intervals were computed and reported when the asymptotic approximation was not sufficiently accurate. All reported P values are two-sided. The differences in the diagnostic yield, sensitivity, and specificity were used to compare subgroups. Ratios were used to compare the negative predictive values, positive predictive values, and positive biopsy rates in subgroups. Approximate confidence intervals for the ratios were computed.²² The Bonferroni correction was used to assess significance in the comparisons of measures of performance among subgroups. For each performance measure, four comparisons were made; thus, a P value of less than 0.0125 was considered to indicate statistical significance. Computations were carried out with the use of SAS software.²³

The degree of suspicion recorded in the report on the initial MRI was used to derive a ROC curve. A binomial model was used to estimate and plot the ROC curve, as implemented with Stata software.²⁴

RESULTS

STUDY POPULATION

A total of 1007 women were enrolled in the trial, 20 of whom were subsequently determined to be

ineligible. Four eligible participants withdrew from the study and 14 who did not undergo the study MRI examination were excluded. Thus, the study group comprised 969 participants (98.2% of the eligible women). Table 1 lists the characteristics of all eligible women and of those included in the study group. Table 1 also shows the histologic features of the index breast cancer (the cancer diagnosed before enrollment). The major types were infiltrating ductal carcinoma (in 58.3% of the women) and ductal carcinoma in situ (20.2%).

Characteristic	All Eligible Patients (N=987)	Study Participants (N=969)
Age — yr	53.4±11.4	53.3±11.4
Ethnic group — no. (%)		
Hispanic or Latino	39 (4.0)	38 (3.9)
Not Hispanic or Latino	942 (95.4)	925 (95.5)
Unknown	6 (0.6)	6 (0.6)
Race — no. (%)†		
American Indian or Alaska Native	3 (0.3)	2 (0.2)
Asian	23 (2.3)	23 (2.4)
Black	49 (5.0)	48 (5.0)
Native Hawaiian or Pacific Islander	2 (0.2)	2 (0.2)
White	903 (91.5)	887 (91.5)
Unknown	14 (1.4)	14 (1.4)
Menopausal status — no. (%)		
Premenopausal or perimenopausal	418 (42.4)	414 (42.7)
Postmenopausal (natural or surgical menopause)	565 (57.2)	552 (57.0)
Unknown	4 (0.4)	3 (0.3)
No. of first-degree relatives with breast cancer — no. (%)		
0	787 (79.7)	774 (79.9)
1	182 (18.4)	179 (18.5)
>1	12 (1.2)	11 (1.1)
Unknown	6 (0.6)	5 (0.5)
No. of relatives (first-degree or other) with breast cancer — no. (%)		
0	615 (62.3)	606 (62.5)
1	253 (25.6)	249 (25.7)
>1	113 (11.4)	109 (11.2)
Unknown	6 (0.6)	5 (0.5)
Histologic features of index cancer — no. (%)		
Infiltrating ductal carcinoma	577 (58.5)	565 (58.3)
Ductal carcinoma in situ	198 (20.0)	196 (20.2)
Infiltrating lobular carcinoma	102 (10.3)	101 (10.4)
Infiltrating carcinoma with ductal and lobular features	61 (6.2)	60 (6.2)
Other‡	49 (5.0)	47 (4.9)†

* Plus-minus values are means ±SD. Ethnic group or race was reported by the patients. Numbers may not sum to 100 because of rounding.

† Race was self-reported.

‡ Other cancers included 16 mucinous cancers, 10 carcinomas not otherwise specified, 10 invasive cancers, not otherwise specified, 7 tubular cancers, 1 medullary tumor, 1 case of Paget's disease, 1 squamous-cell carcinoma, and 1 unknown.

One-year follow-up information was available for 939 of the 969 women. The results of a biopsy, clinical breast examination, or additional imaging (mammographic, ultrasound, or repeat MRI) performed 10 to 14 months after the initial study MRI were recorded for 899 of the 969 women. For 40 of the 969 women, the results of a clinical breast examination, a biopsy, or additional imaging performed between 6 and 10 months after the initial study MRI were recorded.

BREAST CANCERS

Among the 969 women, a total of 33 contralateral breast tumors were diagnosed within 365 days after entry into the study. Of these 33 tumors, 30 were diagnosed as the result of a positive breast MRI examination, 1 was diagnosed by examination of a mastectomy specimen from a woman with MRI findings that were interpreted as BI-RADS 3 (probably benign), and 2 were discovered in prophylactic mastectomy specimens from women with MRI findings that were interpreted as BI-RADS 1 (negative). The three tumors associated with a BI-RADS 1 or BI-RADS 3 score (indicating a false negative result of MRI) were pure ductal carcinomas in situ and were 1, 3, and 4 mm in diameter.

DIAGNOSTIC PERFORMANCE OF BREAST MRI

MRI detected biopsy-proven contralateral tumors in 30 of the 969 women, for a diagnostic yield of MRI, after negative findings on mammographic and clinical breast examination, of 3.1% (95% confidence interval [CI], 2.0 to 4.2). In the entire study population, the estimated sensitivity of breast MRI was 91% (95% CI, 76 to 98) and the specificity was 88% (95% CI, 86 to 90). The negative predictive value of MRI was 99% (95% CI, 99 to 100). The estimated positive predictive value of a positive MRI examination was 21% (95% CI, 14 to 27) (Table 2). On the basis of a positive MRI examination, a biopsy was recommended for 135 of the 969 women (13.9%), and 121 of them underwent a biopsy. Examination of specimens from these 121 biopsies detected 30 cancers (24.8%). Among the women with a positive MRI examination who did not undergo a recommended biopsy, the lesion was no longer visible on subsequent imaging in nine women, four women declined the procedure, and in one woman it was contraindicated. A total of 91 of 969 women with a positive MRI finding underwent a biopsy that detected a benign lesion.

As Table 2 shows, there were no significant differences in the diagnostic yield, sensitivity, or negative predictive value of MRI according to breast density (fatty vs. dense), menopausal status (premenopausal or perimenopausal vs. postmenopausal), or the histologic features of the index cancer (invasive vs. in situ and lobular vs. non-lobular). The specificity was significantly higher among postmenopausal women than among premenopausal or perimenopausal women (91% vs. 84%, $P=0.002$; 95% CI for the difference, 2.5 to 11.1). Similarly, the positive predictive value was higher in the postmenopausal group than in the premenopausal or perimenopausal group (31% vs. 11%; ratio, 2.83; 95% CI for ratio, 1.22 to 6.58; $P=0.006$), as was the positive biopsy rate (35% vs. 14%, ratio, 2.62; 95% CI for ratio, 1.14 to 6.0; $P=0.009$).

The estimated mean (\pm SE) area under the ROC curve for MRI was 0.94 ± 0.02 (95% CI, 0.90 to 0.98) for the entire study cohort (Table 2 and Fig. 1). There were no significant differences in the areas under the ROC curve for any of the paired subgroup comparisons (Table 2).

TUMOR CHARACTERISTICS

Table 3 provides details of the 30 otherwise occult breast tumors that were detected by MRI. Of these 30 tumors, 18 were invasive carcinomas and 12 were ductal carcinomas in situ. Ductal carcinoma was the most common invasive cancer (accounting for 67% of invasive tumors), followed by invasive lobular carcinoma (22%) and two cases of tubular carcinoma. The average diameter of the invasive tumors was 10.9 mm (range, 1 to 42). None of the 30 cancers diagnosed in the study were associated with detectable metastases, and all lymph nodes were negative for metastases in 27 of the 30 women with tumors in the contralateral breast; information about nodal status was not available for the other 3 women, all of whom had invasive disease. A total of 96.7% of the cancers were stage 0 or stage 1. The one stage 2 cancer was a 4.2-cm, node-negative, infiltrating lobular carcinoma.

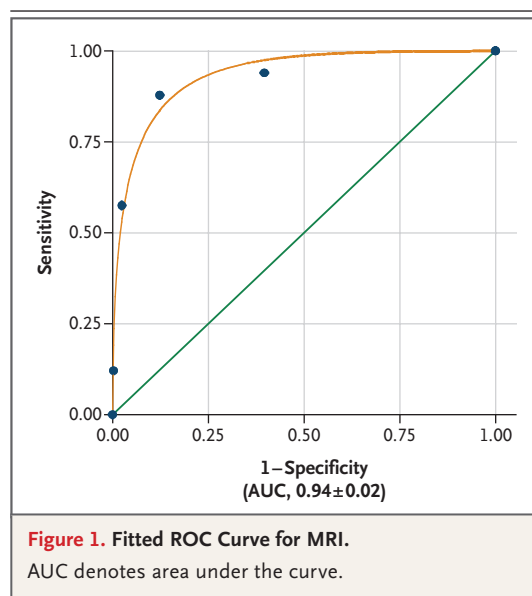
DISCUSSION

The current standard practice for evaluating the contralateral breast in women with a recent diagnosis of breast cancer is to perform a clinical breast examination and mammography. In this prospective study, we estimated the additional

Table 2. Performance of Breast MRI According to Breast Density, Menopausal Status, and Histologic Features of the Index Cancer.*

Characteristic	Cancers Detected [†]		Sensitivity [‡]		Specificity [‡]		Negative Predictive Value [§]		Positive Predictive Value [¶]		Positive Biopsy Rate		Fitted AUC ^{**}	
	No./ Total No. (%)	Standard Error (95% CI)	No./ Total No. (%)	Standard Error (95% CI)	No./ Total No. (%)	Standard Error (95% CI)	No./ Total No. (%)	Standard Error (95% CI)	No./ Total No. (%)	Standard Error (95% CI)	No./ Total No. (%)	Standard Error (95% CI)	P Value	Standard Error (95% CI)
All participants	30/969 (3)	1 (2-4)	30/33 (91)	5 (76-98)	822/936 (88)	1 (86-90)	822/825 (99)	0.2 (99-100)	30/144 (21)	3 (14-27)	30/121 (25)	4 (17-32)	0.94	2 (90-98)
Breast density														
Fatty	9/299 (3)	1 (1-5)	9/9 (100)	0 (100-100)	264/290 (91)	2 (88-94)	264/264 (100)	0 (100-100)	9/35 (26)	7 (11-40)	9/30 (30)	8 (14-46)	0.97	2 (93-100)
Dense	20/666 (3)	1 (2-4)	20/23 (87)	7 (66-97)	555/643 (86)	1 (84-89)	555/558 (99)	0.3 (98-100)	20/108 (19)	4 (11-26)	20/90 (22)	4 (14-31)	0.92	3 (86-97)
Menopausal status														
Premenopausal or perimenopausal	8/414 (2)	1 (1-3)	8/10 (80)	13 (44-97)	339/404 (84)	2 (80-87)	339/341 (99)	0.4 (98-100)	8/73 (11)	4 (4-18)	8/59 (14)	4 (5-22)	0.82	9 (65-99)
Postmenopausal	22/552 (4)	1 (2-6)	22/23 (96)	4 (78-100)	480/529 (91)	1 (88-93)	480/481 (100)	0.2 (99-100)	22/71 (31)	5 (20-42)	22/62 (35)	6 (24-47)	0.97	1 (95-99)
Histologic features of index cancer														
Infiltrating ductal carcinoma	19/565 (3)	1 (2-5)	19/20 (95)	5 (75-100)	478/545 (88)	1 (85-90)	478/479 (100)	0.2 (99-100)	19/86 (22)	4 (13-31)	19/77 (25)	5 (15-34)	0.96	2 (93-99)
Infiltrating lobular carcinoma	6/101 (6)	2 (1-11)	6/6 (100)	0 (100-100)	83/95 (87)	3 (81-94)	83/83 (100)	0 (100-100)	6/18 (33)	11 (12-55)	6/17 (35)	12 (13-58)	0.99	2 (95-100)
Ductal carcinoma in situ	5/196 (3)	1 (0.3-5)	5/7 (71)	17 (29-96)	170/189 (90)	2 (86-94)	170/172 (99)	1 (96-100)	5/24 (21)	8 (5-37)	5/18 (28)	11 (7-48)	0.80	10 (60-100)

* The first number is the number of cancers detected, and the second is the total number of patients. Numbers may not sum to 100 because of rounding.
[†] The first number is the number of true positive results, and the second is the total number of patients with tumors in the contralateral breast.
[‡] The first number is the number of true negative results, and the second is the total number of patients without tumors in the contralateral breast.
[§] The first number is the number of true positive results, and the second is the total number of true positive and false positive results.
[¶] The first number is the number of true negative results, and the second is the total number of true negative and false negative results.
^{||} The first number is the number of biopsy-confirmed results, and the second is the total number of biopsies performed.
^{**} AUC denotes the area under the ROC curve.



diagnostic yield of MRI in such women. Among 969 women with a recent diagnosis of breast cancer and normal results of clinical breast examination and mammographic studies, 30 contralateral cancers were detected on MRI (18 invasive cancers and 12 ductal carcinomas in situ), for a diagnostic yield of 3.1%, with a sensitivity of 91%. In comparison, a recent assessment of mammographic and MRI screening in 1909 high-risk women documented 22 cancers that were detected only by means of MRI; the additional diagnostic yield of MRI over mammography was 1%, with a sensitivity of 80%.¹⁰

We did not find that breast MRI had a low specificity, as previously reported.²⁵⁻²⁷ The specificity of MRI in our study was 88%; a biopsy was recommended on the basis of a positive MRI in 13.9% of the women, and 24.8% of the biopsies resulted in a diagnosis of breast cancer. The overall high accuracy of MRI (as measured by the estimated area under the ROC curve of 0.94) may reflect improved technology or improved interpretation of the results, especially in regard to how to distinguish benign from malignant patterns of enhancement on MRI scans. Our results should be widely applicable, since the participating sites represent a range of radiology practices, from academic centers to community practices, and a range of expertise in interpreting breast MRI studies, from extensive experience to moderate experience.

Table 3. Histologic Features of Cancers in the Contralateral Breast Detected on MRI and Size and Stage of Invasive Tumors.

Characteristic	Value
Histologic features — no./total no. (%)	
In situ carcinoma	12/30 (40)
Invasive carcinoma	18/30 (60)
Invasive ductal carcinoma	12/18 (67)
Invasive lobular carcinoma	4/18 (22)
Tubular carcinoma	2/18 (11)
Invasive carcinoma	
Mean diameter — mm (range)	10.9 (1–42)
TNM stage — no./total no. (%)*	
T1	17/18 (94)
T2	1/18 (6)
NX (unknown)	3/18 (17)
N0	15/18 (83)
M0	18/18 (100)

* TNM denotes tumor–node–metastasis.

The negative predictive value of MRI in the population we studied was extremely high (99%). The risk of an occult cancer in the contralateral breast 1 year after a negative MRI was estimated at 0.3%, and all of the cancers that were detected at that time were ductal carcinoma in situ and were 4 mm or less in diameter. This information may be helpful to women and their physicians in discussing the relative value of bilateral mastectomy when only unilateral cancer is diagnosed after breast MRI. Some women with a diagnosis of unilateral breast cancer choose prophylactic mastectomy of the contralateral breast,^{28,29} but negative findings on preoperative MRI and mammographic studies might reduce the number of unnecessary mastectomies.

In our study, all of the cancers that were detected by means of MRI were node-negative, and 40% were ductal carcinomas in situ. The success of screening programs for breast cancer lies in their ability to detect early cancer, before it has spread to lymph nodes or metastasized to distant sites. Recent studies provide support for the benefit of detecting ductal carcinoma in situ, since this tumor is likely to progress to invasive disease if left untreated.³⁰⁻³² In addition to early detection of in situ or node-negative invasive disease in the contralateral breast, MRI, if positive, can

lead to simultaneous treatment of synchronous cancers rather than multiple treatments on separate occasions.

Our study shows that MRI can improve the detection of cancer in the contralateral breast when added to a thorough clinical breast examination and mammographic evaluation at the time of the initial diagnosis of breast cancer. The increased rate of detection of cancer comes with a false positive rate of 10.9% and a relatively low risk of detecting benign disease on biopsy (9.4%). The current cost of MRI precludes its widespread use in general populations, but this imaging tool

appears to improve the detection of cancer in women at increased risk, such as women with a recent diagnosis of breast cancer.

Supported by grants from the National Cancer Institute (CA 80098 and CA 79778).

No potential conflict of interest relevant to this article was reported.

We thank the many people at the headquarters of ACRIN and at the recruiting sites for their important contributions to the study; the dedicated radiologists and research associates at the clinical sites; and Bruce Hillman, Cynthia Olson, Diane Guay, Charles Apgar, Steve King, Sophia Sabina, Anthony Levering, Cheryl Crozier, Karan Boparai, Sharlene Snowdon, Rob Sole, Marianne Rahme, Glenna Gabrielli, Jo-Ann D'Amato, Chris Steward, and Peggy Devine.

APPENDIX

The following persons served as principal investigators at the ACRIN 6667 clinical sites: *Allegheny-Singer Research Institute, Pittsburgh* — T. Julian, W. Poller; *Boca Raton Community Hospital, Boca Raton, FL* — K. Schilling; *Clinical Radiologists, Springfield, IL* — C. Neal, L. Wichterman; *Elizabeth Wende Breast Clinic, Rochester, NY* — P. Seifert; *Hartford Hospital, Hartford, CT*: M. O'Loughlin; *Johns Hopkins University, Baltimore* — D. Bluemke, S. Kawamoto; *Mayo Clinic, Jacksonville, FL* — E. DePeri; *Northwestern University Medical School, Chicago* — E. Hendrick, J. Wolfman; *Porter Adventist Hospital, Denver* — S. Smazal, D. Thickman; *Scottsdale Medical Imaging, Scottsdale, AZ* — R. Korn, D. Maki, C. Whitfill; *St. Elizabeth Health Center, Youngstown, OH* — A. Cook; *Sunnybrook and Women's College, Toronto* — P. Causer; *Thomas Jefferson University Hospital, Philadelphia* — V. Rao, C. Piccoli; *University of Arkansas for Medical Sciences, Fayetteville* — E. Ferris, S. Harms; *University of Bonn, Bonn, Germany* — C. Kuhl; *University of California at Los Angeles Medical Center, Los Angeles* — N. DeBruhl; *University of California, San Francisco, San Francisco* — N. Hylton; *University of Cincinnati, Cincinnati* — M. Mahoney; *University of North Carolina at Chapel Hill, Chapel Hill* — E. Pisano; *University of Pennsylvania Medical Center, Philadelphia* — M. Schnall, S. Weinstein; *University of Southern California, Los Angeles* — S. Keesara; *University of Texas Southwestern Medical Center, Dallas* — P. Weatherall; *University of Virginia Medical Center, Charlottesville* — G. DeAngelis; *University of Washington, Seattle* — C. Lehman; and *Wayne State University, Detroit* — T. Li, R. Soulen.

REFERENCES

- Heron DE, Komarnicky LT, Hyslop T, Schwartz GF, Mansfield CM. Bilateral breast carcinoma: risk factors and outcomes for patients with synchronous and metachronous disease. *Cancer* 2000;88:2739-50.
- Jobsen JJ, van der Palen J, Ong F, Meerwaldt JH. Synchronous, bilateral breast cancer: prognostic value and incidence. *Breast* 2003;12:83-8.
- Poggi MM, Danforth DN, Sciuto LC, et al. Eighteen-year results in the treatment of early breast carcinoma with mastectomy versus breast conservation therapy: the National Cancer Institute randomized trial. *Cancer* 2003;98:697-702.
- Pomerantz RA, Murad T, Hines JR. Bilateral breast cancer. *Am Surg* 1989;55:441-4.
- Samant RS, Olivetto IA, Jackson JS, Mates D. Diagnosis of metachronous contralateral breast cancer. *Breast J* 2001;7:405-10.
- Veronesi U, Cascinelli N, Mariani L, et al. Twenty-year follow-up of a randomized study comparing breast-conserving surgery with radical mastectomy for early breast cancer. *N Engl J Med* 2002;347:1227-32.
- Fowle BL, Orel SG, Jardines L. Conservative surgery and radiation for early-stage breast cancer. *Semin Roentgenol* 1993;28:279-88.
- Morrow M, Schmidt R, Hassett C. Patient selection for breast conservation therapy with magnification mammography. *Surgery* 1995;118:621-6.
- Morrow M, Strom EA, Bassett LW, et al. Standard for breast conservation therapy in the management of invasive breast carcinoma. *CA Cancer J Clin* 2002;52:277-300.
- Kriege M, Brekelmans CT, Boetes C, et al. Efficacy of MRI and mammography for breast-cancer screening in women with a familial or genetic predisposition. *N Engl J Med* 2004;351:427-37.
- Pisano ED, Gatsonis C, Hendrick E, et al. Diagnostic performance of digital versus film mammography for breast-cancer screening. *N Engl J Med* 2005;353:1773-83. [Erratum, *N Engl J Med* 2006;355:1840.]
- Fischer U, Kopka L, Grabbe E. Breast carcinoma: effect of preoperative contrast-enhanced MR imaging on the therapeutic approach. *Radiology* 1999;213:881-8.
- Kuhl C, Schmiedel A, Morakkabiti N. Breast MR imaging of the asymptomatic contralateral breast in the work-up or follow-up of patients with unilateral breast cancer. *Radiology* 2000;217:268. abstract.
- Lee SG, Orel SG, Woo IJ, et al. MR imaging screening of the contralateral breast in patients with newly diagnosed breast cancer: preliminary results. *Radiology* 2003;226:773-8.
- Lehman CD, Blume JD, Thickman D, et al. Added cancer yield of MRI in screening the contralateral breast of women recently diagnosed with breast cancer: results from the International Breast Magnetic Resonance Consortium (IBMC) trial. *J Surg Oncol* 2005;92:9-15.
- Lieberman L, Morris EA, Kim CM, et al. MR imaging findings in the contralateral breast of women with recently diagnosed breast cancer. *AJR Am J Roentgenol* 2003;180:333-41.
- Rieber A, Merkle E, Bohm W, Brambs HJ, Tomczak R. MRI of histologically confirmed mammary carcinoma: clinical relevance of diagnostic procedures for detection of multifocal or contralateral secondary carcinoma. *J Comput Assist Tomogr* 1997; 21:773-9.
- Slanetz DJ, Edmister WB, Yeh ED, Talele AC, Kopans DB. Occult contralateral breast carcinoma incidentally detected by breast magnetic resonance imaging. *Breast J* 2002;8:145-8.
- Viehweg P, Rotter K, Laniado M, et al. MR imaging of the contralateral breast in patients after breast-conserving therapy. *Eur Radiol* 2004;14:402-8.
- ACR BI-RADS — magnetic resonance imaging. In: *Breast Imaging Reporting and Data System (BI-RADS) breast imaging atlas*. 4th ed. Reston, VA: American College of Radiology, 2003.
- ACR BI-RADS — mammography. In: *Breast Imaging Reporting and Data System (BI-RADS) breast imaging atlas*. 4th ed. Reston, VA: American College of Radiology, 2003.

22. Pepe M. The statistical evaluation of medical tests for classification and prediction. New York: Oxford University Press, 2003:39.
23. SAS/STAT user's guide, version 9.1. Cary, NC: SAS Institute, 2004.
24. Stata reference manual, release 9. College Station, TX: Stata Press, 2005.
25. Bluemke DA, Gatsonis CA, Chen MH, et al. Magnetic resonance imaging of the breast prior to biopsy. *JAMA* 2004;292:2735-42.
26. Berg WA, Gutierrez L, NessAiver MS, et al. Diagnostic accuracy of mammography, clinical examination, US, and MR imaging in preoperative assessment of breast cancer. *Radiology* 2004;233:830-49.
27. Fischer U, Kopka L, Grabbe E. Breast carcinoma: effect of preoperative contrast-enhanced MR imaging on the therapeutic approach. *Radiology* 1999;213:881-8.
28. Herrinton LJ, Barlow WE, Yu O, et al. Efficacy of prophylactic mastectomy in women with unilateral breast cancer: a Cancer Research Network project. *J Clin Oncol* 2005;23:4275-86.
29. Polednak AP. Frequency of prophylactic contralateral mastectomy among breast cancer patients. *J Am Coll Surg* 2001;192:804-5.
30. Griggs JJ, Sorbero MES, Sattelberg K, Dick AW. Does detection and treatment of ductal carcinoma in situ prevent invasive cancer? *J Clin Oncol* 2004;22:14S:664. abstract.
31. Silverstein MJ, Lagios MD, Recht A, et al. Image-detected breast cancer: state of the art diagnosis and treatment. *J Am Coll Surg* 2005;201:586-97.
32. Collins LC, Tamimi RM, Baer HJ, Connolly JL, Colditz GA, Schnitt SJ. Outcome of patients with ductal carcinoma in situ untreated after diagnostic biopsy: results from the Nurses' Health Study. *Cancer* 2005;103:1778-84.

Copyright © 2007 Massachusetts Medical Society.