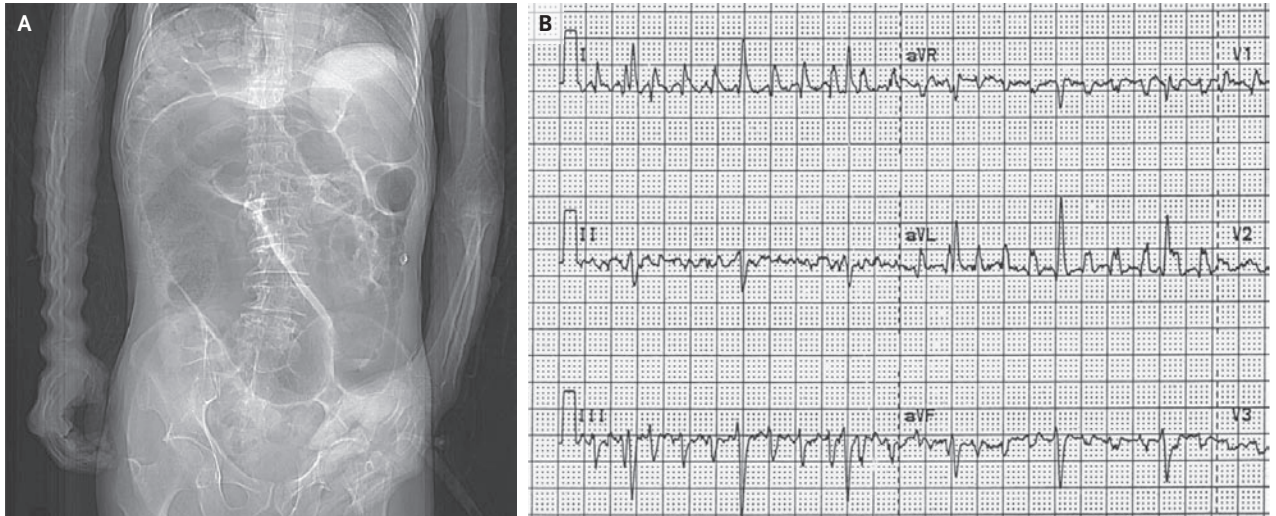


IMAGES IN CLINICAL MEDICINE

A Medical Mystery: Dilated Bowel



A 70-YEAR-OLD MAN PRESENTED WITH A HISTORY OF INCREASING AB-
dominal distention. On physical examination, the patient was afebrile and
his abdomen was soft and nontender. An abdominal radiograph raised concern
about a sigmoid volvulus; thus, a computed tomographic (CT) scan of the ab-
domen was obtained. What disorder does this man have on the basis of his scout
CT image (Panel A) and electrocardiogram (Panel B)?

Jason Handwerker, M.D.
Vassilios D. Raptopoulos, M.D.
Beth Israel Deaconess Medical Center
Boston, MA 02215
jhandwer@bidmc.harvard.edu

Editor's note: We invite our readers to submit their answers at www.nejm.org/mystery. We will publish the diagnosis in the Correspondence section of the March 29 issue and e-mail it to everyone who submits an answer. All answers must be received by February 14.

Copyright © 2007 Massachusetts Medical Society.

WEB-ONLY IMAGES IN CLINICAL MEDICINE

Click on "Featured Images" at www.nejm.org to see the *Journal's* Web-only Images in Clinical Medicine. The Images are listed (with e page numbers) in the table of contents of the printed *Journal* the week they are published and are compiled on the *Journal's* Web site.