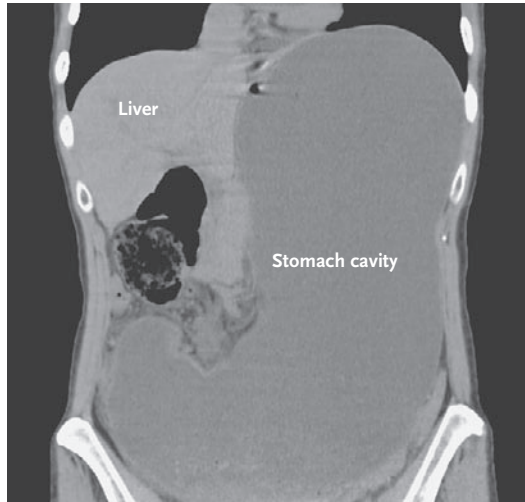


IMAGES IN CLINICAL MEDICINE

Gastric-Outlet Obstruction



Luis M. Franco, M.D.
Natalie J. Dryden, M.D.

Baylor College of Medicine
Houston, TX 77030
njanetd@yahoo.com

A 51-YEAR-OLD WOMAN WITH A HISTORY OF HYPERTENSION AND CHRONIC constipation presented with abdominal pain of 2 weeks' duration. The pain was continuous, worsened with eating, was associated with nausea, and radiated to her back. She reported no vomiting, fever, diarrhea, or weight loss, and her vital signs were normal. Her abdomen was distended, diffusely tender on palpation, and tympanic on percussion on the upper half and dull on the lower half. Bowel sounds were missing on the left side, and a large mass was palpated in that area. Laboratory evaluation was unremarkable. Computed tomography (CT) showed massive dilatation of the stomach, and gas was seen distally on a CT scan. More than 4 liters of fluid was drained from the patient's stomach during the first 24 hours. Upper gastrointestinal endoscopy showed no evidence of peptic ulcer disease or cancer but did show hypertrophic pyloric stenosis. She underwent endoscopic balloon dilation of the pyloric sphincter, with immediate symptomatic relief and resolution of gastric dilatation. Within a few days, the patient returned to a normal diet, and 20 months later, she continued to do well.

Copyright © 2007 Massachusetts Medical Society.

WEB-ONLY IMAGES IN CLINICAL MEDICINE

Click on "Featured Images" at www.nejm.org to see the *Journal's* Web-only Images in Clinical Medicine. The Images are listed (with e page numbers) in the table of contents of the printed *Journal* the week they are published and are compiled on the *Journal's* Web site.