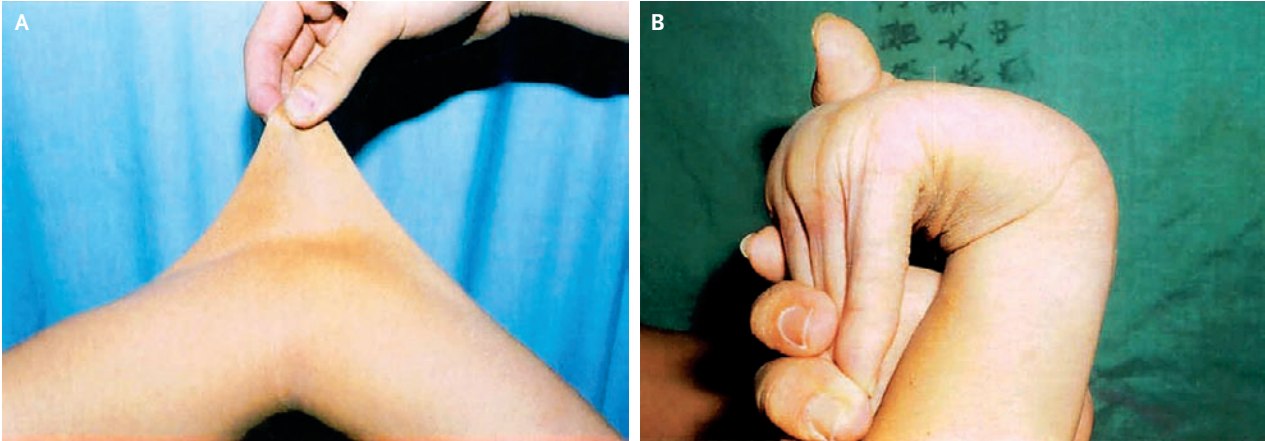


Ehlers–Danlos Syndrome



Chuang-Wei Chen, M.D.
Shu-Wen Jao, Ph.D.

Tri-Service General Hospital
Taipei 114, Taiwan
1211cathy@yahoo.com.tw

A 20-YEAR-OLD MAN PRESENTED FOR CONSIDERATION OF REPAIR OF A rectal prolapse that had been present since birth. Physical examination revealed hyperelasticity of the skin (Panel A) with easy bruisability, hypermobility of the joints (Panel B), and a rectal prolapse of about 15 cm in length, which was easily reducible. Results of laboratory tests and chromosome studies were normal. Results of a skin biopsy showed disorganization of collagen bundles in the dermis. The diagnosis of the Ehlers–Danlos syndrome was made. None of the patient's family members had the disease or similar findings on physical examination. No evaluation for vascular abnormalities was performed. Surgery was deferred, given the mild nature of the rectal prolapse and concern that the patient was at increased risk for surgical complications. He received conservative treatment and has done well for more than 6 years.

Copyright © 2007 Massachusetts Medical Society.